

ROLE OF PREOPERATIVE DOPPLER MAPPING IN SUCCESSFUL AV FISTULA – (RETROSPECTIVE STUDY)

Gurunath Reddy B¹, Shankarnath S², Shekhar Sreekumar³

¹Assistant Professor, Department of General Surgery, Unit of Vascular Surgery St. Johns Medical College hospital, Bangaluru, India.

²Assistant Professor, Department of Trauma Surgery and critical care, Unit of Vascular Surgery St. Johns Medical College Hospital, Bangaluru, India.

³Junior Resident, Department of General Surgery, Unit of Vascular Surgery St. Johns Medical College hospital, Bangaluru, India.

Received : 27/03/2026
Received in revised form : 14/05/2026
Accepted : 30/05/2026

Keywords:

Haemodialysis, Duplex USG, AVF, Vascular mapping, vessels diameter.

Corresponding Author:

Dr. Shankarnath S,

Email: Shansurgery5@gmail.com

DOI: 10.47009/jamp.2026.8.3.154

Source of Support: Nil,

Conflict of Interest: None declared

Int J Acad Med Pharm
2026; 8 (3); 856-861



ABSTRACT

Background: The patients who require hemodialysis, a native AV fistula is the vascular access due to the lower risk of complications. Physical examination has been traditionally used by surgeons for the identification of the suitable vessels. **Materials and Methods:** 118 adult patients of pre-hemodialysis were studied. The ideal site was selected on the basis of standard parameters. The differences between USG and operative findings were analyzed. The AVF evaluation by physical examination was carried out in the superior extremities and then referred to radiodiagnosis for vascular mapping, and patients were evaluated using color Doppler ultrasound. AVF maturation was assessed postoperatively at four weeks using Doppler ultrasound color flow evaluation by looking for vascular components (flow volume, vein, and arterial diameter). **Results:** Out of 118 pre-hemodialysis 4 (3.38%) arteriovenous grafts were done. The highest access site was 52 (44%), which was brachio-cephalic, followed by 35 (29.6%) radio-cephalic and the least, 4 (3.38%), which was brachiocubital. 90 (76%) cephalic veins, followed by 20 (16.9%) basilic veins, were used. In comparative studies, the larger diameter was the axillary artery: 4.43 in ultrasound and 4.54 in surgical studies. Similarly, the axillary vein had a 5.14 diameter in ultrasound and 4.74 in a surgical study, and zero pulmonary embolisms were observed. **Conclusion:** It is confirmed that Doppler evaluation can be the ideal and reliable tool for selecting vessels for AVF preoperatively and assessing AVF maturation postoperatively.

INTRODUCTION

Prevalence of kidney failure on renal replacement therapy affects more than 4 million people globally, and hemodialysis represents the main form of kidney replacement therapy.^[1] The creation of an arteriovenous fistula is recommended as the primary vascular access for the initiation of hemodialysis. The successful creation of an arteriovenous fistula depends on several factors; the patient may require multiple salvage percutaneous or open intra-venous or even repeat vascular access procedures, which exacerbates cost-effectiveness and reduces the quality of life.

To identify suitable candidate vessels and increase patency rates, preoperative ultrasound mapping of vessels of upper limbs versus conventional physical examination is recommended by Spanish clinical guidelines for vascular access,^[2] rather than vascular mapping; it is suggested that selective preoperative ultrasound evaluation in patients at high risk of AV

access failure sonography allows more precise measurement of internal vessel diameters with a minimum of 2 mm of arteries and veins typically recommended.^[3] At the same time, it also provides valuable information concerning internal vascular lesions, which cannot be detected by physical examination alone.^[4] Hence, evaluation of the role of preoperative Doppler USG in planning vascular access was carried out to decrease negative surgical exploration.

MATERIALS AND METHODS

118 adult patients 18 to 65 years old who regularly visited the Nephrology department of St. John's Medical College Hospital, Bengaluru, Karnataka-560034, were studied.

Patients referred by nephrologists to vascular surgeons for physical assessment of upper limbs for AVF creation. The vascular surgeon refers to the radiodiagnostic department for USG evaluation.

Inclusion Criteria: Adult patients with renal failure who needed AVF creation for HD (hemodialysis) access referred from vascular surgery unit to the radio-diagnosis. The patients who gave their consent in writing for the study were selected.

Exclusion Criteria: Patients with upper limb arterial disease like Raynaud's patients with heart valves and prostheses. Patients have undergone arm, chest, and neck surgery and surgery for trauma. The patients > 90 years of age were excluded from the study.

Method: The study was performed on an ultrasound machine using a 13 MHz linear probe. Every patient examination was performed in a sitting position, as most cases require bilateral upper limb examination. The limb under examination is properly exposed and extended in a relaxed position on support. A tourniquet is applied to the proximal part of the limb, particularly during venous examination.

The vessels under examination were checked in both longitudinal and transverse planes. A transverse plane is used to identify arteries and veins and evaluate the diameter of vessels. Measurements are taken in different levels—caudal, mid, and cranial forearm near the ACF and in the caudal, mid, and cranial upper arm as needed.

Arteries were assessed for diameters and morphology of arterial wall for calcification and luminal stenosis. Veins were assessed for compressibility to rule out occluding thrombus and adequate drainage to the deep venous system to check for phlebitis, thrombus,

and thrombophlebitis. Depth of CV from skin was measured (> 0.5 cm considered for transposition). For brachial artery anastomosis, the length of the CV should extend 2 cm below and the BV 4 cm above the ACF (Antecubital fossa). The non-dominant arm is preferred to create HD (hemodialysis access). An AVF is placed first in the forearm if patients have suitable anatomy and the upper arm is saved for future potential dialysis access. Likewise, if an AVF cannot be placed, a forearm graft is preferred over an upper arm graft. However, most will put an AVF in the dominant arm before a graft is considered. The presence of large vein tributaries in the 10 cm of draining vein was noted. Any variation at ACF was mandatory to identify. Two arteries at ACF indicate high bifurcation of the brachial artery, predominant forearm CV, and upper arm BV, double cephalic system y-shaped connection, and variants. Color and spectral Doppler waveforms were obtained in the longitudinal plane of vessels. Bilateral internal jugular and subclavian veins were examined for symmetric respiratory phasicity and transmitted cardiac pulsatility. Unilateral or bilateral monophasic waveforms or low-velocity venous waveforms were abnormal and needed further evaluation. The marking of the skin surface for mapping the vascular system was done accordingly. An important aspect of planning for AVF and graft creation was vessel size and preferential order, as mentioned in Tables 1 and 2.

Table 1: List of minimum diater criteria for AVF and graft creation

Vessels	Minimum diameter (mm)
Artery (AV for graft)	2
AVF vein	2.5 (with tourniquet) 2.0 without tourniquet
Graft vein	3

Table 2: List of preferred order of vascular Access placement

Order of Access placement	Type of placement
1	Non-dominant forearm AV fistula
2	Dominant forearm AV fistula
3	Non-dominant or dominant upper arm cephalic vein Fistula
4	Non-dominant or dominant arm basilica vein trans position fistula
5	Forearm loop graft
6	Upper arm straight graft
7	Upper arm loop graft axillary artery in axillary vein

Duration of study was from January 2024 to December 2025.

Statistical Analysis: Various types of vascular access, comparison of veins and arteries used between ultrasound and surgery was carried out. Moreover measurement arteries and veins by ultrasound and surgical was also carried out. The statistical analysis was carried out SPSS software. The ratio of males and females was 2:1.

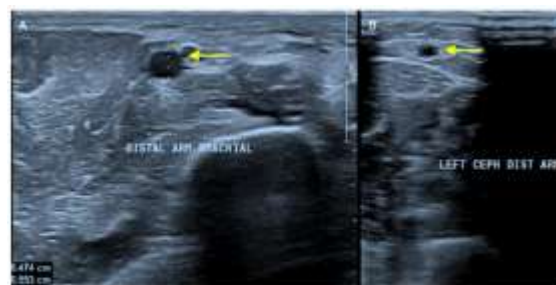

FIGURE 1: Ultrasound grayscale images showing preoperative arterial and venous mapping of the brachial artery (1A) and cephalic vein (1B) using a linear probe (3-12 MHz)

Table 5: Comparison of measurement of Arteries between ultrasound and surgical studies

Arteries	Number	Mean arterial size by ultrasound (diameter)	Surgically measured mean artery (diameter)
Radial	35	2.22	2.43
Axillary	2	4.43	4.54
Brachial fistula	79	3.49	3.38
Brachial graft	2	3.63	3.74

Table 6: Comparison of measurement of veins between ultrasound and surgical studies

Veins	Number	Mean vein size by ultrasound (diameter)	Surgically measured Mean vein size (diameter)
Cephalic (wrist)	35	2.13	2.02
Cephalic (Elbow)	55	2.88	2.74
Basilic	20	2.46	2.32
Axillary	4	5.14	4.74
Antecubital	4	4.53	3.93

Table 7: Comparison of present study results with previous workers

Author and year	Pulmancy embolism (PE) (percentage %)	(E+DUSG) pulmancy Embolismt Doppler ultrasound (Percentage %)
Allon ML etal (2002)	14	63
Silva MB etal (1998)	34	64
Wells AC (2005)	74 (out of 145)	86.5
Malvroh M (2002)	0	77
Present study (2025)	0	77.1

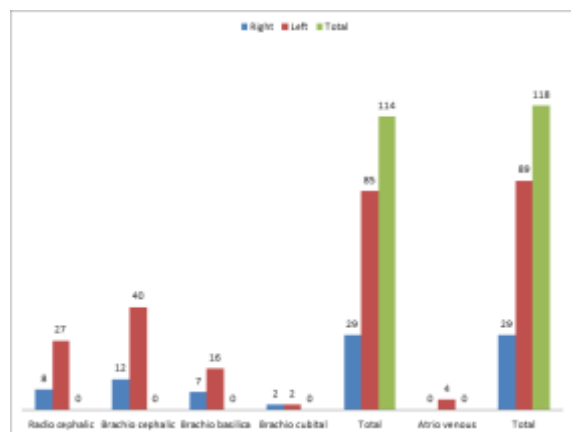


Figure 3: Types of vascular access

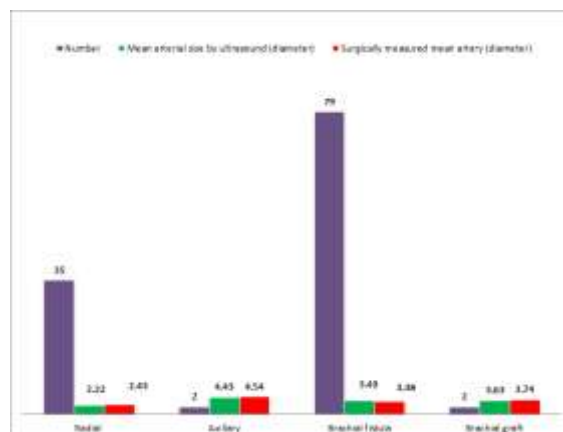


Figure 5: Comparison of measurement of Arteries between ultrasound and surgical studies

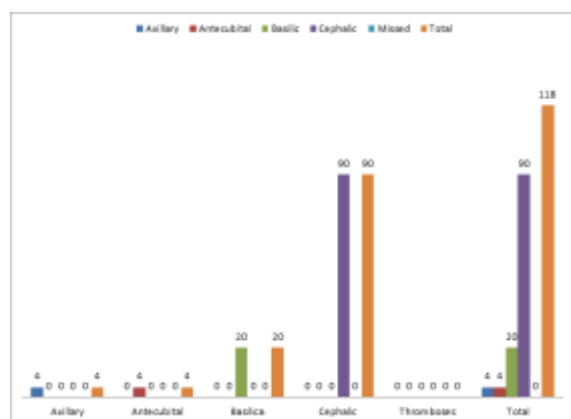


Figure 4: Comparison of veins used between ultrasound and surgery

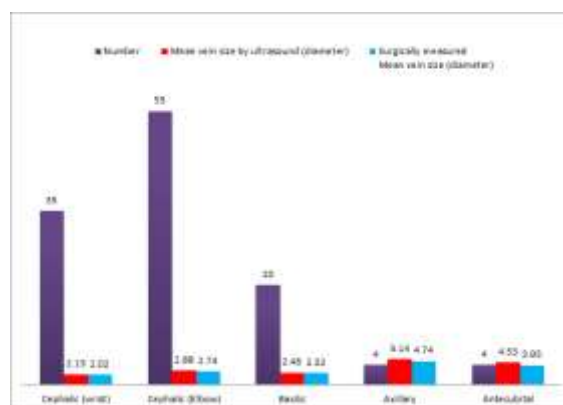


Figure 6: Comparison of measurement of veins between ultrasound and surgical studies

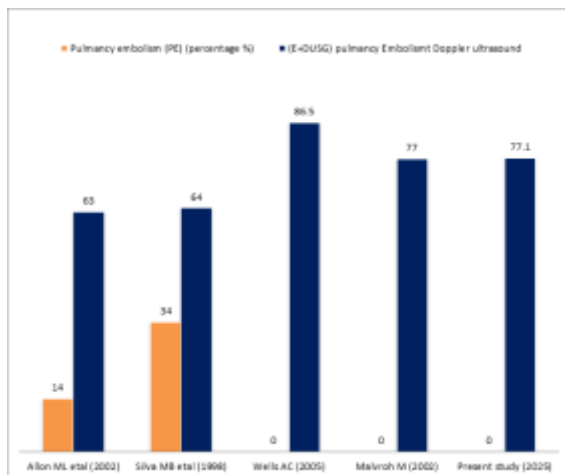


Figure 7: Comparison of present study results with previous workers

DISCUSSION

The role of preoperative Doppler mapping in successful AV fistulas. The highest vascular access was 52 (44%) Bascheo cephalic followed by 35 (29.6%) radiocephalic, and the least was 2 (1.69%) brachio-cubital, and 4 (3.38%) grafts were observed (Table 3). In the comparison of veins used were 90 (76.2%) cephalic veins, 20 (16.9%) basilic veins, 4 (3.88%) axillary, and 4 (3.38%) axillary veins (Table 4). In the comparison of the measurement of arterial size between ultrasound and surgical study. The highest was the axillary artery, with a 4.43 mean size in ultrasound and 4.54 surgically measured, and the least was the radial artery, with a 2.22 diameter in ultrasound and 2.43 in the surgical study (Table 5). In comparison of the measurement of veins between ultrasound and surgical study. The highest diameter was the axillary vein, 5.14 in ultrasound and 4.74 in the surgical study, and the least diameter was observed in the cephalic vein, 2.13 in ultrasound and 2.02 in the surgical study (Table 6) (Figure 1, 2, 3 and 4). These findings are more or less in agreement with previous studies.^[5,6,7]

Successful AVF formation has a significant impact on patients requiring hemodialysis. It facilitates early access to dialysis, reduces the need for acute hemodialysis access, and reduces the number of hospitalizations because of acute electrolyte imbalances, metabolic acidosis, and fluid overload and therefore prevents the morbidity and mortality.^[8] Successful first-time AV access reduces the cost of managing failed fistulas, which may need reoperation or revision, increasing the burden of health care costs for the patients.

Physical examination alone may not be sufficient to evaluate suitable sites for AVF surgery due to patients' habitus (obesity) and compromised vasculature (previous cannulation and medical comorbidities). This has led to recent interest in the role of ultrasonography.^[9] Duplex scanning is a non-invasive, effective, and safe method of establishing morphological and functional parameters or

characteristics of vessels that could help surgeons to improve AVF maturation rates. It can identify the suitable veins that cannot be determined by the physical examination alone.^[10]

In these study both arterial and venous mapping were used in evaluating outcomes of functioning successful AVFs. Some authors assessed radial artery (RA) flow volumes; others used RA diameter, the minimum being 1.6 mm.

The studies reported successful AVF formation assessed by means of a thrill or bruit at the site within 24 hours of surgery.^[11] The key clinical question regarding the proportion of fistulas useful for hemodialysis access remains unanswered.

CONCLUSION

Present study of the role of preoperative Doppler mapping in hemodialysis patients. The physical examination to find an ideal vascular site for AVF also plays an important contributory role in AVF surgery. Though preoperative Doppler mapping in successful AVF, further research is needed to confirm these outcomes as well as to elucidate whether a multidisciplinary approach to vascular access creation involving the routine use of ultrasound is able to affect long-term patency rates, reduce health costs related to access failure complications, and improve patients' quality of life.

Limitation of study: small number of patients, lack of latest techniques we have limited findings and results.

- This research work was approved by the ethical committee of St. Johns Medical College hospital Bengaluru, Karnataka-560034.
- No Conflict of Interest
- Self Funding

REFERENCES

1. Bello AK, Okpechi IG: Epidemiology of hemodialysis outcomes Nat. Rev. Neph. Rol. 2022, 18; 378-395.
2. Voorzaat BM, Janmaat CJ: Patency outcomes of arteriovenous fistulas and grafts for hemodialysis access kidney Journal 2020, vol. 1, 916-924.
3. Lok CE, Huber TS: KDOQI clinical practice guidelines for vascular access. Am. J. kidney Dis. 2019, 75 (2); 1-164.
4. Brooke BS, Griffin CL: Cost effectiveness of repeated intervention on failing arteriovenous fistulas. J. Vasc. Surgery 2019, 70; 1620-1628.
5. Vassalotti JA, Falk A: Obese and non-obese hemodialysis patients have similar prevalence of venous functioning arterio-venous vein mapping. Clin. Nephrol. 2002, 58; 211-214.
6. Siribumrungwang B, Tomitchong P: Role of preoperative vascular ultrasonography in hemodialysis vascular access operation J. Med. Assoc. Thai. 2010, 93 (7); 177-182.
7. Rosenberg I, Benchetrit S: Clinical outcomes in vascular access in hemodialysis patients Isr. Med. Assoc. J. 2022, 24; 514-519.
8. Lee KG, Chang TT: Outcomes of arteriovenous fistula creation: effect of preoperative vein mapping and prediction of fistula success in incident hemodialysis patients. Nephrology 2017, 22; 382-387.
9. Kaur G, Prinja S: Costs of hemodialysis in a public sector tertiary hospital of India. Clin. Kidney J. 2018, 11; 726-33.

10. Prioni RL, Zepel L: International differences in the location and use of arteriovenous access created for hemodialysis. *Am. J. Kidney Dis.* 2018, 71; 469-78.
11. Prasad BR, Chandrashekar AR: A systematic review of the advantage of Doppler ultrasound in arteriovenous access creation and maintenance. *Int. J. Sc. Stud.* 2014, 2; 118-124.