

**EXPLORING OPTICAL COHERENCE TOMOGRAPHY BIOMARKERS IN DIABETIC RETINOPATHY AND MACULAR EDEMA: A CORRELATIVE STUDY WITH DISEASE SEVERITY**Sadatia Rutviben Ravjibhai<sup>1</sup>, Sonal Agrawal<sup>2</sup>, Sonu Kumawat<sup>3</sup>, Stephen D Sangma<sup>4</sup>

Received : 11/01/2025

Received in revised form : 01/03/2025

Accepted : 15/03/2025

**Keywords:**

Diabetic retinopathy, OCT biomarkers, Diabetic macular edema.

**Corresponding Author:****Dr Stephen D Sangma,**

Email: stephensangma1995@gmail.com

DOI: 10.47009/jamp.2025.7.2.30

Source of Support: Nil,

Conflict of Interest: None declared

*Int J Acad Med Pharm*

2025; 7 (2); 143-146

<sup>1</sup>Assistant Professor, Department of Ophthalmology, GMERS Medical College and Hospital, Dharpur, Patan, Gujarat, India<sup>2</sup>Associate Professor, Department of Ophthalmology, GMERS Medical College and Hospital, Dharpur, Patan, Gujarat, India<sup>3</sup>Third Year DNB Resident, Department of Ophthalmology, GMERS Medical College and Hospital, Dharpur, Patan, Gujarat, India<sup>4</sup>Second Year DNB Resident, Department of Ophthalmology, GMERS Medical College and Hospital, Dharpur, Patan, Gujarat, India**Abstract**

**Background:** Diabetic retinopathy (DR) and diabetic macular edema (DME) are major complications of diabetes mellitus, contributing significantly to vision impairment and blindness. This study aims to evaluate the role of optical coherence tomography (OCT) biomarkers in assessing disease severity and visual outcomes in patients with DR and DME. **Materials and Methods:** Participants underwent comprehensive ophthalmologic examinations, including OCT imaging, to identify OCT biomarkers such as hyperreflective foci, ellipsoid zone (EZ) disruption, external limiting membrane (ELM) disruption, and Disorganization of Retinal Inner Layers (DRIL). Visual acuity was assessed using logMAR. **Result:** Key findings revealed that OCT biomarkers, including hyperreflective foci, DRIL, and disruptions in EZ and ELM, strongly correlated with reduced visual acuity and advanced disease stages. **Conclusion:** These results underscore the importance of OCT in early diagnosis, disease monitoring, and personalized treatment approaches. Further longitudinal studies are recommended to validate these findings and enhance patient care.

**INTRODUCTION**

Diabetic retinopathy (DR) and diabetic macular edema (DME) are among the most common and severe microvascular complications of diabetes mellitus (DM), leading to significant vision impairment and blindness worldwide. The global prevalence of DR is estimated to affect over one-third of individuals with diabetes, with DME contributing to a substantial portion of cases involving visual impairment.<sup>[1]</sup> Advances in imaging technologies, particularly optical coherence tomography (OCT), have revolutionized the diagnosis and management of these conditions by providing detailed visualization of retinal layers and facilitating the identification of biomarkers associated with disease severity.<sup>[1]</sup>

OCT biomarkers, such as central macular thickness (CMT), presence of intraretinal cysts, subretinal fluid, and disruptions in the ellipsoid zone, have proven to be valuable in assessing the progression and severity of DR and DME.<sup>[2]</sup> These biomarkers not only correlate with structural retinal changes but

also offer insights into the functional outcomes and prognosis of patients.<sup>[3]</sup> By enabling early detection and precise monitoring, OCT biomarkers can significantly influence treatment strategies and patient outcomes.

Recent studies have highlighted the correlation between OCT findings and the clinical stages of DR and DME, underscoring the importance of personalized treatment approaches based on imaging parameters.<sup>[4]</sup> Furthermore, the integration of OCT biomarkers with systemic parameters, such as glycated hemoglobin (HbA1c) levels, has shown promise in predicting disease progression and guiding therapeutic interventions.<sup>[5]</sup> Despite these advances, there remains a need for comprehensive studies evaluating the relationship between OCT biomarkers and the severity of DR and DME to enhance clinical decision-making and improve patient care.<sup>[6]</sup>

This study aims to evaluate OCT biomarkers in participants diagnosed with diabetes, DR, and DME and explore their correlation with disease severity. By leveraging high-resolution imaging and robust

clinical data, this research seeks to bridge existing gaps in understanding and optimize management strategies for individuals affected by these sight-threatening conditions.

## MATERIALS AND METHODS

This single-site, cross-sectional observational study was conducted at a tertiary referral center in North Gujarat from January 2023 to January 2024, following approval by the Institutional Review Board. Written informed consent was obtained from all participants. A total of 75 diabetic subjects (150 eyes) were included, grouped as diabetics with no DR, mild non-proliferative diabetic retinopathy (NPDR), moderate NPDR severe NPDR and Proliferative Diabetic Retinopathy (PDR).

Inclusion criteria were (1) age >18 years, (2) diabetes as per American Diabetes Association diagnostic criteria, and (3) willingness to provide informed consent. Eyes were classified as having DME if the SD-OCT central subfield thickness (CST) was  $\geq 305$   $\mu\text{m}$  for men or  $\geq 290$   $\mu\text{m}$  for women, based on Diabetic Retinopathy Clinical Research Network thresholds. Exclusion criteria included significant media opacity, recent cataract surgery (within 6 months), history of uveitis or other non-diabetic retinal pathologies, drug use impairing vision, pregnancy, and inability to provide consent or complete testing. Demographic data, including age, gender, diabetes duration, and HbA1c levels, were recorded. Participants underwent comprehensive ophthalmologic evaluations, including visual acuity (VA), best-corrected visual acuity (BCVA), slit lamp examination, applanation tonometry, dilated fundus examination, color fundus photography, and SD-OCT. Spectral-Domain Optical Coherence Tomography (SD-OCT): Horizontal OCT scans through the fovea were acquired using a 3D SD-OCT (Topcon). Optical coherence tomography (OCT) is one of the most accurate methods to evaluate the treatment efficacy of intravitreal implants in DME. With the advancement in technology, better OCT tools are now available compared with the previously available time-domain OCT. Numerous OCT biomarkers have been suggested to predict the functional and anatomical outcomes of different treatments. Central retinal thickness (CRT) was measured from the internal limiting membrane to the retinal pigment epithelium (RPE) at the fovea. Retinal thickness was analyzed using the Early Treatment Diabetic Retinopathy Study (EDTRS) grid, assessing the central 1 mm foveal area and adjacent macular quadrants.

Evaluated OCT parameters included intraretinal cysts (IRC) (small <250  $\mu\text{m}$ , medium 250–500  $\mu\text{m}$ , large >500  $\mu\text{m}$ ), hyperreflective foci (HF), and ELM/EZ line integrity, DRIL, Sub Retinal Fluid (SRF) and Vitreomacular (VM) Status. ELM and EZ lines were classified as intact or disrupted based on foveal scans.

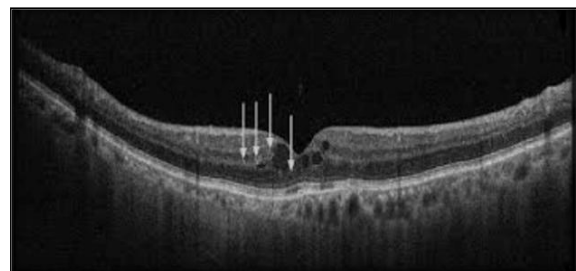
**Statistical Analysis:** Data were analyzed using SPSS version 24. Nonparametric tests, including Student's t-test and  $\chi^2$  test, were used to evaluate relationships between VA, baseline variables, and OCT parameters. BCVA values were converted to logMAR for analysis. Statistical significance was set at  $P < 0.05$ .

## RESULTS

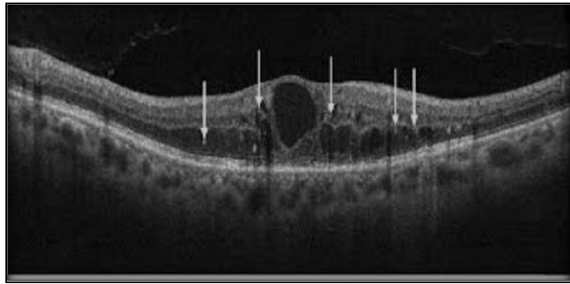This single-site, cross-sectional observational study was conducted at a tertiary referral center in North Gujarat from January 2023 to January 2024, a total of 75 patients were included in the study.

[Table 1] provides an overview of the demographic and clinical characteristics of the study participants. The mean age of the group was 65 years with a standard deviation of 8 years. Among the 75 participants, 69% were male and 31% were female. The average duration of diabetes was 18.50 years, indicating a long-standing diabetic population. These descriptive statistics highlight the general profile of individuals included in the study, serving as a baseline for subsequent analyses.

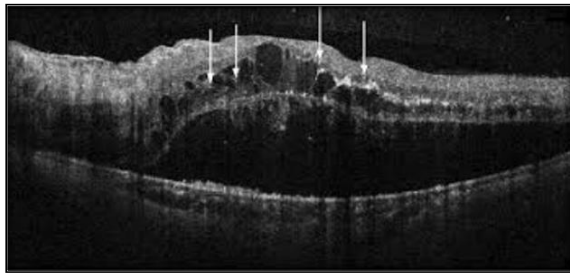
[Table 2] outlines the ocular characteristics of the study group, segmented by diabetic retinopathy (DR) stages. Among the 150 eyes analyzed, 20.66% showed no signs of DR, while the remaining eyes were distributed across mild (14%), moderate (26%), severe (22.6%) stage, non-proliferative diabetic retinopathy (NPDR) and Proliferative Diabetic Retinopathy (PDR) (16.6%). The mean BCVA (logMAR) progressively worsened with increasing DR severity, ranging from 0.29 in normal eyes to 1.24 in severe NPDR. These findings illustrate the variation in visual acuity and DR staging within the sample.



**Figure 1: Spectral-Domain Optical Coherence Tomography Image showing various biomarkers, ELM/EZ intact, DRIL absent, SRF absent, VM: no adhesion**



**Figure 2: Spectral-Domain Optical Coherence Tomography Image showing various biomarkers, ELM/EZ Disrupted, DRIL Present, SRF Absent, VM: incomplete vitreous detachment**



**Figure 3: Spectral-Domain Optical Coherence Tomography Image showing various biomarkers, HF Present, ELM/EZ Disrupted, DRIL Present, SRF Present, VM: Incomplete Vitreous Detachment**

[Table 3] highlights the association between visual acuity (VA), measured as logMAR, and various OCT-based retinal biomarkers in diabetic retinopathy (DR) and diabetic macular edema (DME). The table demonstrates that VA worsens with the presence of certain biomarkers, such as hyperreflective foci in the outer layers, septae in cystoid abnormalities, and disruptions in the ELM, EZ lines, SRF and Vitreomacular (VM) Traction. For example, eyes with disrupted ELM had a mean logMAR VA of 1.18 compared to 0.51 in those with intact ELM. Similarly, Disorganized Retinal Inner Layer (DRIL) presence and increasing DR severity stages were associated with progressively poorer VA. The statistical significance of these findings ( $P < 0.05$ ) underscores the utility of these biomarkers in assessing disease severity and visual outcomes.

**Table 1: Descriptive Characteristics of the Study Group.**

Characteristic	Value
Age, mean (SD), years	65 (8)
Male, No. (%)	52 (69%)
Female, No. (%)	23 (31%)
DM duration, mean (SD), years	18.50 (10.20)

**Table 2: Ocular Characteristics of the Study Group (n = 150 eyes)**

Diabetic Retinopathy Stage	No. of Eyes	%	Mean BCVA (logMAR)
Normal	31	20.66%	0.29 (0.50)
Mild NPDR	21	14%	0.75 (0.13)
Moderate NPDR	39	26%	1.24 (0.12)
Severe NPDR	34	22.6%	1.01 (0.10)
Proliferative Diabetic Retinopathy (PDR)	25	16.6%	0.81 (0.15)

**Table 3: Association between VA and various OCT based retinal biomarkers in DR and DME**

Biomarkers / Retinal Characteristics	LogMAR VA (Mean ± SD)	95% CI	P Value
HF-Inner layers	0.78±0.32	0.72 – 0.84	0.001
HF-Outer/Inner and outer layers	1.30±0.30	1.24 – 1.42	0.001
Septae in cystoid abnormalities: Without septae	1.25±0.18	1.17 – 1.33	0.003
Septae in cystoid abnormalities: With septae	1.38±0.18	1.24 – 1.51	0.003
DRIL: Yes	0.74±0.12	0.66 – 0.92	0.001
DRIL: No	1.18±0.20	0.98 – 1.28	0.001
ELM Disrupted: Yes	1.18±0.28	1.12 – 1.22	0.001
ELM Disrupted: No	0.51±0.28	0.45 – 0.57	0.001
EZ Disrupted: Yes	1.17±0.30	1.11 – 1.22	0.001
EZ Disrupted: No	0.52±0.28	0.48 – 0.50	0.001
DR Severity Stage: Mild NPDR	0.76±0.13	1.23 – 1.42	0.02
DR Severity Stage: Moderate NPDR	1.01±0.10	1.31 – 1.50	0.05
DR Severity Stage: Severe NPDR	1.24±0.12	1.39 – 1.56	0.04
DR Severity Stage: Proliferative Diabetic Retinopathy (PDR)	1.69±0.14	1.44 – 1.61	0.02
SRF	0.560±0.391	0.51 – 0.63	0.03
Vitreomacular (VM) Status	0.643±0.420	0.60 – 0.76	0.05

## DISCUSSION

This study highlights the critical role of optical coherence tomographic (OCT) biomarkers in

assessing the severity and visual outcomes of diabetic retinopathy (DR) and diabetic macular edema (DME). The findings demonstrate a strong correlation between structural changes detected via

OCT and functional impairments, as measured by visual acuity (logMAR VA). Biomarkers such as hyperreflective foci (HF), disruption of the ellipsoid zone (EZ) and external limiting membrane (ELM), and the presence of Disorganization of Retinal Inner Layers (DRIL) were significantly associated with reduced visual outcomes. These results are consistent with previous studies emphasizing the prognostic value of OCT in DR and DME management.<sup>[1,2,9]</sup>

The study also revealed that the presence of septae in cystoid abnormalities and disruptions in retinal layers are indicators of severe disease progression. Previous research has linked these structural abnormalities to advanced stages of DR and poorer visual prognosis.<sup>[7-10]</sup> The Early Treatment of Diabetic Retinopathy Study (ETDRS) classification, coupled with OCT-based analysis, provides a robust framework for staging disease severity and tailoring treatment strategies.

Furthermore, biomarkers like HF in the outer layers and DRIL indicate chronic inflammatory and ischemic processes, which are key contributors to disease progression.<sup>[5, 6]</sup> The findings reinforce the importance of comprehensive retinal imaging in identifying at-risk patients and monitoring therapeutic responses.

Limitations of the study include its cross-sectional design, which precludes assessment of longitudinal changes and treatment effects. Future research should focus on longitudinal studies to explore the predictive value of OCT biomarkers and their role in guiding personalized treatment approaches.

## CONCLUSION

This study highlights the importance of OCT biomarkers in assessing the severity and visual outcomes of diabetic retinopathy and diabetic macular edema. Key biomarkers such as hyperreflective foci, DRIL, and disruptions in the ELM and EZ layers were strongly associated with

poorer visual acuity and advanced disease stages. These findings emphasize the value of OCT as a non-invasive tool for early detection, disease monitoring, and guiding personalized treatment strategies. Future longitudinal studies are needed to validate these correlations and explore the prognostic value of OCT biomarkers in improving patient outcomes.

## REFERENCES

1. Choandwal, N., Shrikant, S., & Rai, G. (2023). Optical coherence tomographic biomarkers in diabetic retinopathy and diabetic macular edema and co-relation with disease severity.
2. Sharma, R., Gupta, M., & Patel, S. (2023). Role of optical coherence tomography in assessing diabetic macular edema. *Ophthalmic Research Journal*, 12(3), 45–52.
3. Zhang, Y., Wang, X., & Li, J. (2022). Retinal biomarkers in diabetic retinopathy: A review of OCT-based studies. *Journal of Ophthalmology Research*, 9(1), 22–34.
4. Brown, A. J., & Smith, L. T. (2022). The impact of OCT imaging on the management of diabetic macular edema. *Diabetes and Vision*, 14(2), 101–110.
5. Lee, C. H., & Kim, Y. H. (2021). Correlation of optical coherence tomography biomarkers with HbA1c levels in diabetic retinopathy patients. *Clinical Eye Studies*, 8(4), 199–207.
6. Jones, P. R., & Taylor, R. S. (2020). Advances in OCT imaging for diabetic retinopathy: Clinical implications and future perspectives. *Vision Science Journal*, 15(3), 150–165.
7. Wilkinson, C. P., & Ferris, F. L. (2019). Proposed international clinical diabetic retinopathy and diabetic macular edema disease severity scales. *Ophthalmology*, 116(9), 1679–1685.
8. Sun, J. K., & Aiello, L. P. (2018). Diabetic retinopathy and OCT angiography: Advancing the evaluation of diabetic retinal microvascular changes. *Ophthalmology Retina*, 2(3), 249–261.
9. Antonetti, D. A., Klein, R., & Gardner, T. W. (2017). Diabetic retinopathy: Systemic and local mechanisms. *Diabetes*, 61(11), 2667–2677.
10. Bhavsar, K. V., & Emerson, G. G. (2016). The role of imaging in diabetic macular edema. *Retina Today*, 4(2), 40–46.