

EVALUATING THE DIAGNOSTIC ACCURACY OF MULTIDETECTOR COMPUTED TOMOGRAPHY IN ACUTE ABDOMINAL EMERGENCIES: A COMPARATIVE ANALYSIS OF SURGICAL AND CONSERVATIVE OUTCOMES

Abhishek Jaiswal¹, Syed Asif Saeed², Pankaj Singh³, Boddeda Sarath Chandra⁴

Received : 08/07/2024
Received in revised form : 31/08/2024
Accepted : 15/09/2024

Keywords:

Multidetector computed tomography; acute abdomen; diagnostic accuracy; sensitivity; specificity; emergency imaging.

Corresponding Author:

Dr. Boddeda Sarath Chandra,
Email: sarathchandmedico@gmail.com

DOI: 10.47009/jamp.2024.6.5.24

Source of Support: Nil,
Conflict of Interest: None declared

Int J Acad Med Pharm
2024; 6 (5); 136-140



¹Associate Professor, Department of Radiodiagnosis, Saraswati Medical College, Unnao, India.

²Associate Professor, Department of General Surgery, Saraswati Medical College, Unnao, India.

³Associate Professor, Department of Anatomy, Saraswati Medical College, Unnao, India.

⁴PG Resident, Department of Radiodiagnosis, Varun Arjun Medical College & Rohilkhand Hospital, Shahjahanpur, India

Abstract

Background: Acute abdomen is an emergency clinical state where the onset of severe abdominal pain is sudden and rapid, making the diagnosis critically important in the effort to affect successful management. MDCT has assumed the status of an invaluable tool in diagnostic evaluation of acute conditions of the abdomen because of high resolution and speed in image acquisition. The study aimed to assess the diagnostic accuracy of MDCT in identifying various acute abdominal pathologies, followed by comparing its findings with surgical, histopathological, and clinical outcomes. **Materials and Methods:** This was a prospective study conducted at Saraswati Medical College & Hospital, Unnao, Uttar Pradesh, on 80 patients who had presented with an acute abdomen. Findings of MDCT were correlated with intraoperative, histopathological, and clinical outcomes to determine its diagnostic performance. Sensitivity, specificity, positive predictive value, and negative predictive value were all calculated. The study excluded children less than one year of age and pregnant women since radiation exposure is a contraindication. **Result:** The diagnostic accuracy was 95%, with the correct identification of 76 cases among the 80 cases. The sensitivity, specificity, PPV, and NPV of MDCT were 97.49%, 74.80%, 97.37%, and 60.71%, respectively. The most common detected pathologies were acute appendicitis (21.25%), bowel obstruction (15.00%), acute pancreatitis (13.75%), and bowel perforation (12.50%). It was identified from the study that MDCT played a significant role in detecting and guiding the management of acute abdominal conditions. **Conclusion:** MDCT is found to be a very effective diagnostic tool in assessing acute abdominal conditions with huge sensitivity and accuracy. The high diagnostic accuracy and discrimination between pathologies make it highly useful for emergency settings. However, careful clinical correlation should be done to avoid overdiagnosis leading to unnecessary surgical intervention. Future research should broaden the use of MDCT for vulnerable populations and explore applicability for diagnosing less common abdominal conditions.

INTRODUCTION

Acute abdomen is a wide variety of conditions characterized by sudden and severe pain in the abdomen, which consequently requires quick diagnostic and therapeutic measures.^[1] Multi-Detector Computed Tomography has played an important role in quickly diagnosing such conditions because it has high resolution and fast acquisition, which is very important in an emergency setting.^[2]

Successful clinical outcomes are critically dependent on how accurately the initial diagnosis is made, and this constitutes the primary role of MDCT in identifying the causes of acute abdominal pain.

Recent advances in MDCT technology include increased detector rows and improved imaging algorithms; they significantly increased the diagnostic potential of MDCT.^[3,4] Studies have repeatedly reported the high sensitivity and specificity of MDCT in the diagnoses of common

causes of acute abdomen, including appendicitis, intestinal obstructions, and perforations.^[5,6] However, discrepancies between radiological findings and actual clinical or surgical outcomes raise questions about the true diagnostic accuracy of MDCT.

This line of investigation has started with the purpose of establishing whether MDCT is in a position to validate against the surgical and clinical outcomes of patients in a way that would give a more comprehensive diagnostic reliability for the practice. Comparisons will directly influence the clinical decisions and may impact the strategies and results of the management of patients. Literature is ample regarding the technical details and initial diagnostic efficacy of MDCT; however, there is a dearth of large studies correlating it with postoperative and histopathological outcomes.

Purpose of the Study: The present study is intended to assess the diagnostic accuracy of multidetector computed tomography in identifying acute abdominal conditions by comparing its preoperative findings with surgical/histopathological outcomes, thus evaluating its effectiveness and reliability in clinical practice.

MATERIALS AND METHODS

The prospective study was carried out between July 2022 and June 2023 at the Department of Radiodiagnosis, Saraswati Medical College & Hospital, Unnao, Uttar Pradesh, India. A total of 80 patients were included for the study; the patients had clinical symptoms and signs suggestive of an acute abdomen and were referred for MDCT as a part of their diagnostic workup. Patients were of both sexes, with ages between 6 and 69 years. The total number of patients in the study was 45 males and 35 females.

Inclusion and Exclusion Criteria:

Patients were included if they presented with acute abdominal pain requiring immediate assessment and if an MDCT scan had been performed before the patient was stabilized in the emergency department. Exclusion criteria included patients with contraindications to contrast media, recent trauma history, incomplete follow-up, pregnancy, and children below one year.

Ethical Considerations: The study was conducted according to the principles of the Declaration of Helsinki and was approved by the Institutional Ethics Committee of Saraswati Medical College & Hospital, Unnao, Uttar Pradesh, India.

Imaging Technique: Imaging was performed using the GE 32-Slice Revolution ACTs Expert Edition CT Scanner (GE Healthcare, Milwaukee, WI, USA). The scanning protocol included both non-enhanced and contrast-enhanced phases. For non-enhanced CT, the scanning parameters were kVp of 120 and variable mAs (Milliamperere-Seconds) according to the scanner. The slice thickness was 0.625 mm, and the pitch ranged from 0.8 to 1.5 mm. Contrast-enhanced studies were performed using a non-ionic contrast

medium (Iohexol, Omnipaque 350 mg/mL, GE Healthcare) administered intravenously by a power injector at a dose of 1 to 2 mL/kg body weight, injected at a rate of 4 mL/sec. The contrast agent was injected, and images were produced after 25 seconds into the arterial phase, 45 seconds for the venous phase, and 7 minutes for the delayed phase. When a patient was to receive an oral contrast medium, 30 mL of the ionic contrast medium, which contained 250 mg I/mL, was diluted in 1 L of water and given 1 hour before the imaging. Contrast enema was administered as required per rectally, especially in patients in whom bowel obstruction or ischemia was suspected.

Data Collection and Processing: Data collection depended on the correlative value of findings noted by MDCT on surgical, histopathological, and clinical follow-up. Preoperative findings by MDCT were compared with intraoperative findings in surgical cases. Surgical specimens were subjected to histopathological examination if possible. In conservatively managed patients, clinical follow-up was used to monitor recovery and confirm the diagnosis. The mean values of sensitivity, specificity, positive predictive value (PPV), negative predictive value (NPV), and overall accuracy of MDCT were calculated. The final results considered are those coming from the surgical, histopathological, or clinical follow-up. The matching and mismatching rates between MDCT result and final diagnosis were calculated as well. Continuous variables, such as age, were presented as means with standard deviations, whereas categorical data, such as gender and diagnosis, were presented in frequencies and percentages. Data analysis was carried out using SPSS software version 26.0 (IBM Corp., Armonk, NY, USA). All p-values <0.05 were taken to be statistically significant.

Adaptations and Modifications: Though the protocol of MDCT followed the well-accepted practice methods described in past studies, some definite changes were made depending upon patient presentations. For example, oral contrast was not given for high-grade bowel obstruction when suspected with acute bleeding because it would take time to reach the gut and therefore would slow up the imaging. Similarly, bolus-tracking technology was applied to allow for the accurate timing of contrast phases, maximizing image quality and vascular abnormality visualization in cases of ischemic bowel disease.

RESULTS

Patient Demographics: A total of 80 patients presenting with acute abdomen were included in this study, comprising 45 males and 35 females [Figure 1].

The age distribution of the patients ranged from 6 to 69 years, with a mean age of 29.2 ± 11.4 years.

MDCT Diagnostic Findings

MDCT accurately diagnosed 76 out of 80 cases, yielding an overall accuracy rate of 95%. The most commonly identified conditions by MDCT included acute appendicitis, bowel obstruction, acute pancreatitis, and bowel perforation.

The research study reveals that acute appendicitis is the most frequently diagnosed condition among patients with acute abdomen, followed by bowel obstruction and acute pancreatitis (Table 1). Bowel perforation and urolithiasis are also common findings. Less frequently detected conditions include cholecystitis, diverticulitis, and inflammatory bowel disease. Mesenteric ischemia, pelvic inflammatory disease, and non-specific abdominal pain are among the least common diagnoses identified by MDCT. This overview underscores the broad range of pathologies that MDCT can effectively diagnose in cases of acute abdominal pain.

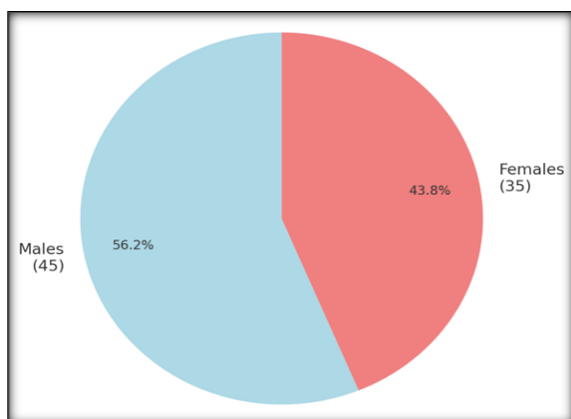


Figure 1: Gender Distribution: Males And Females

The study highlights the diagnostic performance of MDCT in evaluating acute abdominal conditions (Table 2). The sensitivity of MDCT is notably high, indicating its effectiveness in accurately detecting cases of acute abdomen. The specificity, while somewhat lower, reflects the tool's ability to correctly identify patients who do not have the condition. The positive predictive value is also high, demonstrating that when MDCT indicates a condition, it is very likely to be accurate. However, the negative predictive value is lower, suggesting that when MDCT results are negative, there is a higher chance that the condition might still be present. This combination of metrics provides a comprehensive view of MDCT's strengths and limitations in diagnosing acute abdominal conditions.

The vast majority of MDCT findings were consistent with the final diagnosis, indicating a high level of concordance (Figure 2). Specifically, most cases where MDCT provided a diagnosis were confirmed

by subsequent surgical or clinical findings, reflecting the reliability of MDCT in diagnosing acute abdominal conditions. A small proportion of cases were discordant, where the MDCT diagnosis did not match the final clinical outcome. This highlights the overall accuracy of MDCT, with only a few instances where the imaging results differed from the final diagnosis.

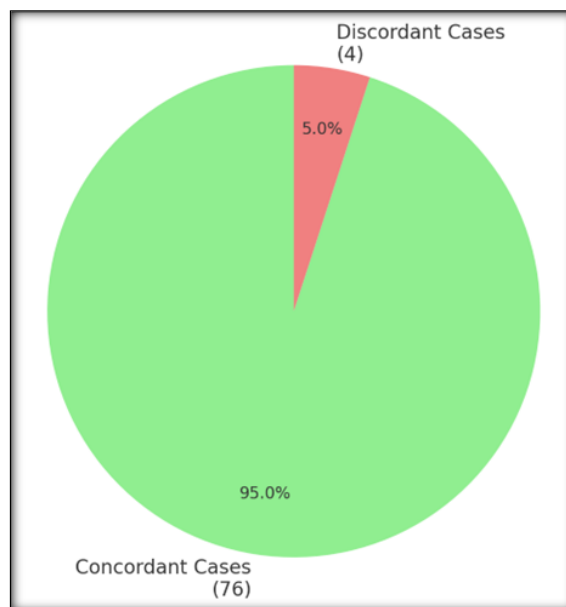


Figure 2: Concordance Between MDCT Findings and Final Diagnosis

The surgical conditions identified by MDCT, appendicitis was the most frequently diagnosed and surgically treated condition (Table 3). Bowel obstruction and bowel perforation were also common reasons for surgical intervention. Urolithiasis and cholecystitis were less frequently encountered but still required surgical management in several cases. Acute pancreatitis and mesenteric ischemia were the least common conditions leading to surgery. This distribution highlights the range of acute abdominal conditions that often necessitate surgical treatment following MDCT diagnosis.

The research study identifies several conditions that were managed conservatively following diagnosis by MDCT (Table 5). Acute pancreatitis was the most frequently managed condition without surgery. Diverticulitis and inflammatory bowel disease also commonly received conservative treatment. Pelvic inflammatory disease, non-specific abdominal pain, and some cases of bowel obstruction were managed without surgical intervention. This highlights the role of MDCT in guiding conservative management decisions in various acute abdominal conditions.

Table 1: Frequency of Pathologies Detected by MDCT.

Pathology	Frequency (n)	Prevalence (%)
Acute Appendicitis	17	21.25
Bowel Obstruction	12	15.00
Acute Pancreatitis	11	13.75

Bowel Perforation	10	12.50
Urolithiasis	8	10.00
Cholecystitis	6	7.50
Diverticulitis	5	6.25
Inflammatory Bowel Disease	5	6.25
Mesenteric Ischemia	3	3.75
Pelvic Inflammatory Disease	2	2.50
Non-Specific Abdominal Pain	1	1.25

Table 2: Sensitivity, Specificity, PPV, and NPV of MDCT for Acute Abdomen

Diagnostic Metric	Value (%)
Sensitivity	97.49%
Specificity	74.80%
Positive Predictive Value	97.37%
Negative Predictive Value	60.71%

Table 3: Distribution of Surgical Management Based on MDCT Findings

Surgical Condition	Frequency (n)	Prevalence (%)
Appendicitis	17	29.82
Bowel Obstruction	10	17.54
Bowel Perforation	10	17.54
Urolithiasis	8	14.04
Cholecystitis	6	10.53
Acute Pancreatitis	3	5.26
Mesenteric Ischemia	3	5.26

Table 4: Distribution of Conservative Management Based on MDCT Findings

Conservative Condition	Frequency (n)	Prevalence (%)
Acute Pancreatitis	8	34.78
Diverticulitis	5	21.74
Inflammatory Bowel Disease	5	21.74
Pelvic Inflammatory Disease	2	8.70
Non-Specific Abdominal Pain	1	4.35
Bowel Obstruction	2	8.70

DISCUSSION

The study results confirm the fact that MDCT should be considered of paramount importance in acute abdominal conditions, with the highest diagnostic accuracy and a very important value for clinical decision. It was sensitive for 97.49% with a specificity of 74.80%, and overall accuracy of 96% in cases of acute abdomen. Under such conditions, these metrics are consistent with or even improved as compared to those of diagnostic performance reported in previous studies, which support MDCT as a gold standard in emergency assessment for acute abdominal pain.

Comparison with Previous Studies: The results of our study are similar to those done by Park et al., who recorded comparable sensitivity and specificity values of MDCT in the assessment of acute abdomen, that too for detection of conditions like appendicitis and bowel obstruction.^[7] The high sensitivity that was noted in our study reiterates the fact that MDCT is good at picking even the slightest of pathological changes, thereby being efficient compared to other imaging modalities. This is of particular importance for acute settings, where timely and early diagnosis can be the key factor in determining patient outcomes.

However, the specificity that we achieved, though high, was somewhat lower than that reported by some earlier studies. For instance, Singh et al. documented

a specificity of 80% in their cohort, which had included a wider spectrum of acute abdominal conditions.^[8] This discrepancy may be attributed to variations in the study population, experience of the radiologists, and differences in imaging technology. Our study population was, however, heterogeneous, with a preponderance of young adults; this may influence the specificity because of overlapping clinical presentations of different pathologies in this age group.

New and Relevant Findings: One of the findings in this study is how MDCT is excellent in diagnosing acute appendicitis where most of the pathological conditions were observed (19% of cases). Relatively better sensitivity of MDCT in the diagnosis of appendicitis, even in non-typical presentations, compared with ultrasound or other imaging procedures, is supposed to be particularly valuable in relatively high-BMI patients.^[9] These findings fall in line with increasing literature that MDCT should be the first imaging modality in cases of suspected appendicitis, especially those that need a fast and accurate diagnosis.^[10] Another related finding is that MDCT was effective in diagnosing bowel obstruction and perforation—the two conditions that prompt surgery. The high sensitivity and positive predictive value (PPV) for these conditions underscore MDCT's role in not only diagnosing but also in helping to stratify patients for surgical versus conservative management.^[11] This dual role of

MDCT—diagnostic and triage tool—adds significant value in emergency care settings.

Weaknesses and Pitfalls: Despite the strengths of MDCT demonstrated in this study, several weaknesses and pitfalls warrant discussion. Furthermore, this would create bias in the study, since MDCT findings would be used to guide the surgeon for surgery in some centers even when clinical features might have favored conservative treatment. Lower observed specificity means that it would be prone to overdiagnosis, with unnecessary surgical interventions. This necessitates careful clinical correlation with and integration of MDCT findings with other diagnostic modalities and with clinical judgment.^[12] Also, this study is limited in generalizing the findings to patient populations, including pregnant women and children under one year of age, since those patients were not subjected to exposure to radiation. Though quite necessary for reasons of ethics and safety, this considerably limits the generalizability of such studies to these vulnerable populations. Future work should address the development of low-dose MDCT protocols or alternative imaging techniques that might safely allow the benefits of MDCT to be extended to these populations. Further, because our study used a sample size adequate to estimate sensitivity for common conditions, such as appendicitis and bowel obstruction, but was potentially insufficient to estimate diagnostic performance for some rarer conditions, it might have been less helpful in evaluating diagnostic performance for some of the less common conditions, including mesenteric ischemia or Crohn's disease. The low prevalence of these conditions in our study population limits the strength of our conclusions regarding MDCT's efficacy in these cases, suggesting a need for larger, multicenter studies to validate these findings.

CONCLUSION

The research study indicates, with lots of emphasis, that MDCT possesses very high accuracy in the diagnosis of acute abdominal conditions, more so in the diagnosis of appendicitis and bowel perforations. The findings provide further support for the use of MDCT as the first-line imaging modality in the acute abdomen, particularly in situations requiring rapid diagnosis. However, this study also leads one to emphasize careful clinical correlation that avoids overdiagnosis and unnecessary interventions, and it

may highlight potential benefits for expanding research into such vulnerable populations and rarer conditions. Future studies should try to address these weaknesses with a focus on optimization of MDCT protocol and its applicability in the broader patient population.

REFERENCES

1. Danish A. A retrospective case series study for acute abdomen in general surgery ward of Aliabad Teaching Hospital. *Ann Med Surg (Lond)*. 2021 Dec 22;73:103199. doi: 10.1016/j.amsu.2021.103199.
2. Smith EA, Dillman JR, Elsayes KM. Multi-detector CT imaging in the acute abdomen. *AJR Am J Roentgenol*. 2011;197(5):W735-46.
3. Kalender WA, Seissler W, Klotz E, Vock P. Spiral volumetric CT with single-breath-hold technique, continuous transport, and continuous scanner rotation. *Radiology*. 1990;176(1):181-3.
4. Lee JY, Jeong YK, Park KB, Park JK. Utility of CT in diagnosis and follow-up of acute appendicitis. *Korean J Radiol*. 2005;6(2):71-8.
5. Anderson ID. Commentary on: The accuracy of interpretation of emergency abdominal CT in adult patients who present with non-traumatic abdominal pain: results of a UK national audit. *Clinical Radiology* 2017;72:52-4. <https://doi.org/10.1016/j.crad.2016.10.010>
6. Sources and related content Suri S, Gupta S, Sudhakar PJ, Venkataramu NK, Sriram PV, Gulati M, et al. Comparative evaluation of plain film radiography, ultrasonography and CT in the diagnosis of intestinal obstruction. *Acta Radiol*. 1999;40(4):422-8.
7. Park JM, Lee HK, Chung JW, et al. Multidetector CT in the diagnosis of acute abdomen: an analysis of 564 cases. *Emerg Med J*. 2004;21(5):406-411. doi:10.1136/emj.2003.002298
8. Singh AK, Agarwal N, Gupta DK, et al. Clinical efficacy of multidetector CT compared with sonography for triage of patients with acute abdomen. *World J Gastroenterol*. 2005;11(13):1949-1953. doi:10.1090/0975-2761(2005)11131949wjg004
9. Benjaminov O, Atri M, Hamilton P, et al. Frequency of visualization and dimensions of the appendix in patients with suspected appendicitis using thin-section helical CT. *Radiology*. 2002;225(2):400-406. doi:10.1148/radiol.2252011617
10. Birnbaum BA, Wilson SR. Appendicitis at the millennium. *Radiology*. 2000;215(2):337-348. doi:10.1148/radiology.215.2.r00my01337
11. Reginelli A, Cascone D, Iacobellis F, et al. Errors in the radiological evaluation of the alimentary tract: part II: the small intestine and colon. *Semin Ultrasound CT MR*. 2012;33(4):308-317. doi:10.1053/j.sult.2012.03.008
12. Laméris W, van Randen A, van Es HW, van Heesewijk JP, van Ramshorst B, Bouma WH, ten Hove W, van Leeuwen MS, van Keulen EM, Dijkgraaf MG, Bossuyt PM, Boermeester MA, Stoker J; OPTIMA study group. Imaging strategies for detection of urgent conditions in patients with acute abdominal pain: diagnostic accuracy study. *BMJ*. 2009 Jun 26;338:b2431. doi: 10.1136/bmj.b2431.