

## MEDIAL PLANTAR ARTERY FLAP FOR HEEL PAD RECONSTRUCTION - LOCO REGIONAL FLAP OF CHOICE AND ALTERNATIVE TO FREE FLAP/REVERSE SURAL FLAP

N. Senthilkumar<sup>1</sup>, G. Balamurugan<sup>2</sup>, N. Selvaraj<sup>3</sup>

Received : 05/01/2024  
Received in revised form : 26/02/2024  
Accepted : 13/03/2024

**Keywords:**

Medial plantar artery, Loco regional flap, Heel pad reconstruction, squamous cell carcinoma, Reverse sural flap.

Corresponding Author:  
**Dr. N. Senthilkumar,**  
Email:

DOI: 10.47009/jamp.2024.6.2.49

Source of Support: Nil,  
Conflict of Interest: None declared

*Int J Acad Med Pharm*  
2024; 6 (2); 234-237



<sup>1</sup>Assistant Professor, Department of Surgical Oncology, Government Coimbatore Medical College, Tamilnadu, India

<sup>2</sup>Professor, Department of Surgical Oncology, Government Coimbatore Medical College, Tamilnadu, India

<sup>3</sup>Associate Professor, Department of Surgical Oncology, Government Coimbatore Medical College, Tamilnadu, India

### Abstract

**Background:** Reconstruction of heel pad defects resulting from Wide Excision of malignancy is challenging because of its unique structure, which is modified to bear the entire body weight. **Materials and Methods:** We retrospectively analysed data from 12 patients who underwent surgery using a medial plantar artery flap between August 2019 and September 2023 in our department for heel pad defects. All patients were analysed for postoperative complications and clinical outcomes. The donor site was covered with SSG, the leg was immobilised with plaster of Paris Slab for 5 days, and weight-bearing was allowed after 4 weeks. **Result:** Twelve patients (eight males and 4 female patients) were included. Seven patients had acral melanoma and five had squamous cell carcinoma. The maximum healing pad defect was 5 cm × 7 cm in size. A flap infection was observed in one patient, and no flap necrosis was observed. Donor site partial skin graft loss was observed in 2 patients. Touch pain sensation was checked at the end of three months of flap reconstruction and was present in all cases. All patients were able to walk normally at the end of three months. **Conclusion:** A medial plantar artery flap or instep flap provides excellent postoperative function.

## INTRODUCTION

The heel pad is a common site of squamous cell carcinoma and acral/lentiginous melanoma. Treatment requires wide excision and reconstruction. Heel pad reconstruction is commonly performed using a reverse sural artery flap, medial plantar artery flap, and free flaps.<sup>[1]</sup> Reconstruction poses a challenge because it must withstand the entire body weight with sensation. The medial plantar flap used for the sole reconstruction has several advantages. The first flap provides solid anchoring to deep tissues to resist shearing. The second method provides optimal colour, texture, and thickness matching for the sole reconstruction. Third, a sensate flap was provided if a proper branch from the medial plantar nerve was included in the flap.

Normal weight bearing is contributed by the heel, lateral border of the foot, metatarsophalangeal joint, and toes. The instep area does not contribute to weight bearing; it extends from the distal to the heel and proximal to the first metatarsal head. Therefore, an instep area with

intact blood supply from the medial plantar artery was designed for flap reconstruction.

The skin of the foot is specialized with a thick epidermis and dermis anchored to the plantar aponeurosis by fibrous septa which in turn partition subcutaneous fat between the skin and plantar aponeurosis. This fibrous septum prevents gliding of the skin, and the partitioned subcutaneous fat acts as a shock absorber.<sup>[2]</sup>

The posterior tibial artery divides midway between the medial malleolus and heel in the medial and lateral plantar arteries. The medial plantar artery course between the abductor hallucis and flexor digitorum brevis proceeds to 1<sup>st</sup> space to join the deep plantar arch and supply to the great toe. The medial plantar nerve which accompanies the artery has a similar course. It supplies general sensation to the anterior 2/3 of the foot and medial three-and-one-half of the toes. The skin in the instep area is supplied by a separate branch from the medial plantar nerve or a separate branch from the main trunk.<sup>[3]</sup>

## Aim

To determine immediate postoperative complication of medial plantar artery flap reconstruction and delayed postoperative functional outcome of heel pad reconstruction by medial plantar artery flap.

## MATERIALS AND METHODS

We retrospectively analyzed heel pad defect reconstruction using a medial plantar artery flap in 12 patients from August 2019 to September 2023 in the Department of Surgical Oncology at Coimbatore Medical College, Coimbatore.

### Inclusion Criteria

Patients who underwent heel pad defect reconstruction using a medial plantar artery flap were included in this study.

### Exclusion Criteria

Patients with heel pad defect reconstruction using other flaps were excluded from the study.

An objective assessment of outcomes was performed in terms of flap survival, sensory recovery, and coverage durability. Functional outcomes including limitation of activity, walking distance, walking surface, and pain were assessed.

### Surgical Technique

Preoperative Doppler imaging was performed to rule out peripheral vascular disease. The posterior tibial artery is palpated and marked behind the medial malleolus. The primary tumour was surgically excised under tourniquet control. The exact size of the defect was marked in the instep area. The lateral side of the marked flap was incised to the muscle layer. The plane of dissection is between the plantar aponeurosis and the muscle layer. Distal and medial incisions are made. The medial plantar artery was identified distally, ligated, and cut after identifying and preserving the medial plantar nerve. The flap was raised distal to proximal. Proximal skin incision made, deepened to transect plantar aponeurosis insertion to calcaneum. If pedicle lengthening is needed, the incision is extended proximally until the division of the posterior tibial artery. The vessel was dissected proximally, with a complete section of the abductor hallucis muscle. Intraneural dissection is sometimes required to separate the branch that supplies the flap from the medial plantar nerve. The donor site was covered with SSG. The leg was immobilised with a plaster of Paris Slab for five days. Weight bearing was allowed after 4 weeks.

## RESULTS

Twelve patients (eight males and 4 female patients). Seven patients had acral melanoma and five had squamous cell carcinoma. The maximum heel pad defect was 5 cm × 7 cm in size. Intraoperative medial plantar nerve injury occurred in one patient. A flap infection was observed in one patient, and no flap necrosis was observed. Donor site partial skin graft loss was observed in 2 patients. Touch pain

sensation was checked at the end of three months of flap reconstruction and was present in all cases. All patients were able to walk normally at the end of three months.

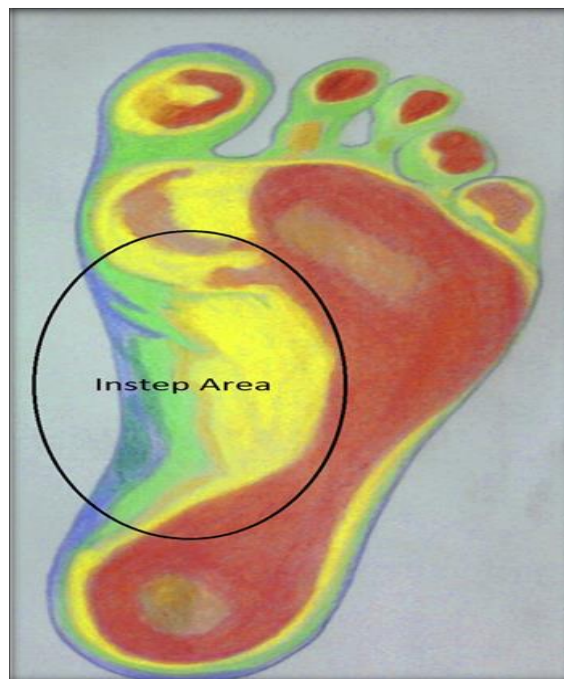


Figure 1: Instep area

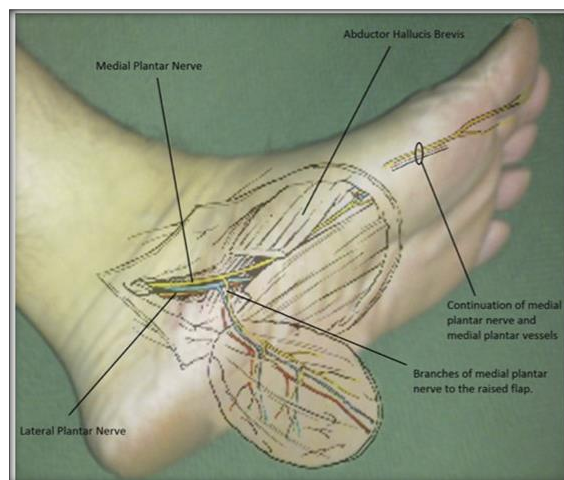
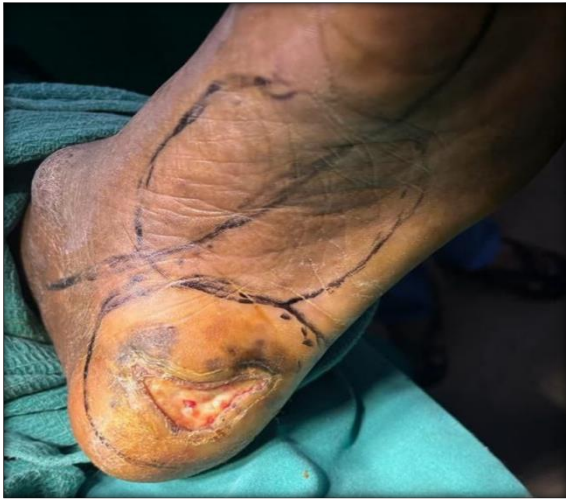
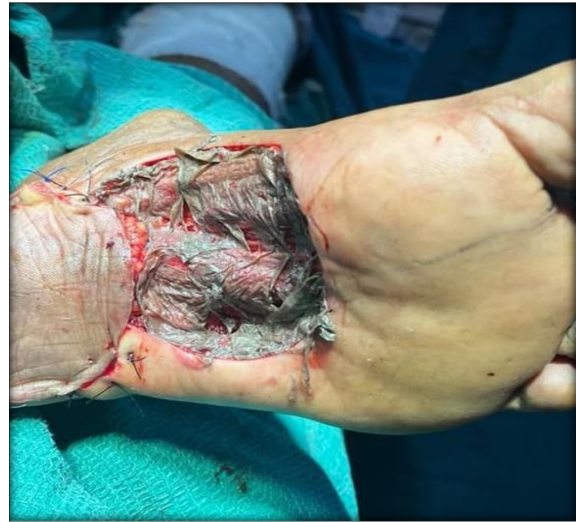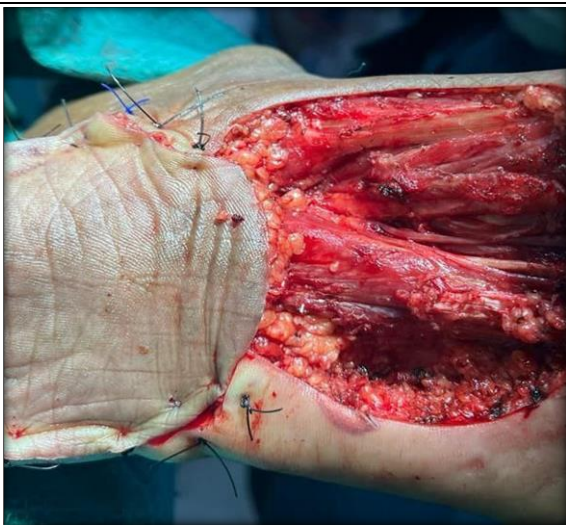Figure 2: Medial plantar artery flap with pedicle



**Figure 3: Pre-op flap marking with acral melanoma heel**



**Figure 5: Raw area in the instep region covered with a split skin graft**



**Figure 4: Reconstructed heel with medial plantar flap with raw area showing medial plantar nerve**

**Table 1: Comparison of various study results with our study**

Study/Year	Number of flaps	Percentage of complete survival	Complications
Schwarz and Negrini (2006), <sup>[8]</sup>	51	97%	One flap loss
Siddiqi et al. (2012), <sup>[9]</sup>	18	100%	Donor site morbidity
Khan et al. (2018), <sup>[10]</sup>	16	93%	Donor site morbidity
Our study (2023)	12	100%	Nerve injury

## DISCUSSION

Acral Melanoma and squamous cell carcinoma are common heel-pad malignancies in India. Treatment requires wide excision with a 1 cm margin for squamous cell carcinoma and 1–2 cm clearance, depending on the depth of invasion for melanoma. The frozen section for the margin was done, and immediate reconstruction was done.<sup>[4]</sup>

Reconstruction of heel pad defects is a great challenge, as reconstruction of the weight-bearing heel pad aims to provide sensation with a dural skin cover. It is desirable to replace like tissue with like. Of all options, the medial plantar artery flap, whether an island pedicled or free flap, can replace similar tissue with heel pad sensation. This flap was first described by Harrison and Morgan in

1981.<sup>[5]</sup> Different techniques can be used to bring the medial plantar flap to the recipient area. These include local rotation, transposition, V-Y advancement, and free flap from the opposite side. In our cases, we used the island technique for flap transfer.<sup>[6]</sup>

Among other flaps, the extended reverse sural flap provides coverage for large posterior defects and when bulky tissue is needed. The disadvantage of the reverse sural flap is venous congestion, which results in partial or complete flap loss and is also insensitive. Rashid et al. performed a comparative study comparing a medial plantar flap with a reverse sural artery flap. The study concluded that the medial plantar flap had fewer complications, an earlier return to walking, and fewer recurrent ulcerations.<sup>[1]</sup>



Among free flaps, the contralateral medial plantar free flap and free flaps from non-weight-bearing areas, such as the rectus abdominis flap, latissimus dorsi flap, scapular flap, and anterolateral thigh flap, are available. Free flaps from non-weight-bearing areas have weak anchoring power and are therefore prone to frequent ulcerations. The thoraco-dorsal artery free flap provides durable coverage and fast recovery. Krishna et al. divided heel pad defects into anterior and posterior types. Medium-sized anterior defects were ideally managed using a medial plantar artery flap. Posterior defect or total defects of the heel pad was managed by a reverse sural flap or free flaps.<sup>[7]</sup>

#### **Advantage of Medial plantar flap**

Provides adequate soft tissue coverage, reliable vascular supply, and intact nerve supply to the flap, can be used to reconstruct both the hind foot and forefoot (using a reverse medial plantar artery flap), can be used as a free flap for contralateral heel pad defects, has improved flap survival rate and fewer complications.<sup>[8]</sup>

#### **Disadvantages of Medial plantar flap**

While harvesting chance for medial plantar nerve injury, the cutaneous branch from the medial plantar flap must be dissected from the main trunk for adequate sensation and also has donor site morbidity.<sup>[9,10]</sup>

### **CONCLUSION**

The medial plantar artery is a reliable option for the reconstruction of heel pad defects. It provides a durable sensation flap with less recurrent ulceration. Meticulous dissection of the medial plantar nerve and its branches to the flap should be performed to

ensure a sensate flap and protect the distal sensation of the foot.

**Limitations:** Our sample size was small, retrospective in nature and had no comparative analysis with other locoregional flaps for heel pad reconstruction.

### **REFERENCES**

1. Rashid M, Hussain SS, Aslam R, Illahi I. A comparison of two fasciocutaneous flaps in the reconstruction of defects of the weight-bearing heel. *J Coll Physicians Surg Pak.* 2003;13:216. <https://pubmed.ncbi.nlm.nih.gov/12718778/>.
2. Masadeh SB, Liette MD. The medial plantar artery: anatomy and implications in local flaps of the foot. *Plast Aesthet Res* 2023; 10:54. <https://doi.org/10.20517/2347-9264.2023.19>.
3. Langat AS, Wan Sulaiman WA, Mat Johar SFN. Heel pad reconstruction with medial plantar flap. *Cureus* 2021;13. <https://doi.org/10.7759/cureus.13987>.
4. Bibbo C. Plantar heel reconstruction with a sensate plantar medial artery musculocutaneous pedicled island flap after wide excision of melanoma. *J Foot Ankle Surg* 2012;51:504–8. <https://doi.org/10.1053/j.jfas.2012.04.017>.
5. Harrison DH, Morgan BDG. The instep island flap to resurface plantar defects. *Br J Plast Surg* 1981;34:315–8. [https://doi.org/10.1016/0007-1226\(81\)90019-9](https://doi.org/10.1016/0007-1226(81)90019-9).
6. Opoku-Agyeman JL, Allen A, Humenansky K. The use of local medial plantar artery flap for heel reconstruction: a systematic review. *Cureus.* 2020;12:0. <https://doi.org/10.7759/cureus.9880>.
7. Krishna D, Chaturvedi G, Khan MM, Cheruvu VPR, Laitonjam M, Minz R. Reconstruction of heel soft tissue defects: An algorithm based on our experience. *World J Plast Surg* 2021;10. <https://doi.org/10.29252/wjps.10.3.63>.
8. Schwarz RJ, Negrini J-F. Medial plantar artery island flap for heel reconstruction. *Ann Plast Surg* 2006;57:658–61. <https://doi.org/10.1097/01.sap.0000235426.53175.e3>.
9. Siddiqi MA, Hafeez K, Cheema TA, Rashid H-U. The medial plantar artery flap: A series of cases over 14 years. *J Foot Ankle Surg* 2012;51:790–4. <https://doi.org/10.1053/j.jfas.2012.06.003>.
10. Khan FH, Beg MSA, Obaid-ur-Rahman. Medial plantar artery perforator flap: Experience with soft-tissue coverage of heel. *Plast Reconstr Surg Glob Open* 2018;6:e1991. <https://doi.org/10.1097/gox.0000000000001991>