

## FUNCTIONAL OUTCOME OF TITANIUM ELASTIC NAILING IN DIAPHYSEAL FEMUR FRACTURE IN CHILDREN OF AGE GROUP 7- 14 YEARS

Dilimon K<sup>1</sup>, Arun Ramanan<sup>2</sup>, Anand Narayanan<sup>3</sup>

<sup>1</sup>Senior Resident, Department of Orthopaedics, Government Medical College Hospital, Kottayam

<sup>2</sup>Assistant Professor, Department of orthopaedics, Government Medical College Hospital, Kottayam

<sup>3</sup>Assistant Professor, Department of orthopaedics, Government Medical College Hospital, Kottayam

Received : 02/10/2023  
Received in revised form : 14/11/2023  
Accepted : 26/11/2023

**Keywords:**

Titanium elastic nailing, Flynn's criteria, nail site infection, limb length discrepancy, Elastic stable intramedullary nail.

Corresponding Author:

**Dr. Arun Ramanan,**

Email: arunramanan04@gmail.com

DOI: 10.47009/jamp.2023.5.6.181

Source of Support: Nil,

Conflict of Interest: None declared

*Int J Acad Med Pharm*  
2023; 5 (6); 873-881



### Abstract

**Background:** To assess the functional outcome of titanium elastic nailing in diaphyseal femur fracture in children of age group 7-14 years. **Materials and Methods:** Observational study, conducted among randomly selected 35 children, of age 7-14 years of age who underwent titanium elastic intramedullary nailing. Patients were followed up regularly. Femur x-ray were taken immediately postop and at 4 weeks, 8 weeks, 12 weeks, 24 weeks, 32 weeks and the status of union is assessed in each visit. At these intervals, functional status of the patient was also assessed with Flynn's criteria for TENs. Data was entered in Microsoft excel and analyzed using IBM SPSS Statistics for Windows, Version 20.0. Armonk, NY: IBM Corp. IBM Corp. Numeric variables were expressed using mean and standard deviation and categorical variables will be expressed in frequencies. **Result:** Of all the cases 74.3 % showed excellent results, 22.9% showed satisfactory results whereas 2.9% had poor outcome as per by Flynn's criteria of TENs. **Conclusion:** Based on our study and results, Titanium elastic nailing System is an effective and efficient method for the treatment of diaphyseal fractures of pediatric diaphyseal femur fracture in the age group between 7 to 14 years.

## INTRODUCTION

Fracture femur is the most common fracture leading to hospitalization; constituting nearly 1.6%. Incidence is 1.6 – 2%.<sup>[1]</sup> It has got a BIMODAL distribution; increased rate of incidence in 2-4 years and adolescent age group. Boys are more affected than girls (2.6:1). Most common cause being fall in <10 years age group & road traffic accident in >10 years age group.<sup>[2]</sup>

In children less than 3 years the most reliable cause for similar fracture would be child abuse. Recently there has been an increasing trend for operative management; nevertheless, the primary aim should be to stabilize the fracture, to control length and alignment, to promote fracture healing, and to minimize the complication and morbidity for the child.<sup>[3]</sup>

Over the years there has been a growing trend of intramedullary fixation of the fracture shaft of femur due to technical development, notably of ELASTIC STABLE INTRAMEDULLARY NAILS.<sup>4</sup> Titanium Elastic Nail (TEN) is an ideal method for fixation of shaft of femur in pediatric age group due to its minimal invasive, less complication, less chance of failure. Proximal insertion site avoids the piriformis fossa and the greater trochanter, thus avoiding AVN

of femoral head and growth arrest respectively. Distal insertion site doesn't require dissection into the knee joint or violation of the distal physis.<sup>[5]</sup> It is used in most of the pediatric cases; although poor outcome has been shown in heavier children. Fifty kilograms has been proposed as a reasonably cutoff by several authors, although there had been success in treating children with specific fracture pattern of 70 kg to 80 kg using stainless steel nails. Flexible nailing may be done in a child with multiple injuries, concomitant head injury etc.<sup>[6]</sup>

The fracture pattern most amenable to this treatment is a transverse stable fracture with minimal comminution. Long spiral fractures are relative contraindication for this because, rotational deformity and shortening are more likely to occur. Flexible nails can be used with caution for long oblique and spiral fractures; however, the length and stability of the fracture site has to be evaluated at the time of surgery.<sup>[7,8]</sup> Rotational malalignment, usually an external rotation deformity after flexible intramedullary nail has been cited as a concern and may be present in 50% of patient due to inability to control rotation intraoperative. However, it is unusual that it requires treatment, implying that significant remodeling must occur in the axial plane. Postoperatively, weight bearing is generally started immediately as tolerated by the patient, especially in

children with a stable fracture pattern; although some authors wait 4 to 8 weeks before allowing full weight bearing.<sup>9</sup> We prefer to have the patient weight bearing without any external immobilization, but unstable or distal fractures may require a knee immobilizer or walking single limb hip Spica cast. We often use a knee immobilizer for comfort to assist early immobilization of the child for transport.

The flexible nails may be placed in an anterograde or retrograde fashion, depending on the location of fracture site and the overall preference and experience of the surgeon. In general, we prefer the larger of the two fragments for insertion site to promote greater stability at the fracture site however mechanical studies have shown that distal fractures can be adequately fixed with retrograde insertion. Two flexible nails of equal diameter should be used to allow three-point fixation of the fracture site. Both nails may be started through a medial window or one may be used through a medial and lateral entry. We select nail diameter based on preoperative imaging and use the general rule to attempt to fill 80% of the canal's isthmus diameter. Theoretically closed flexible intramedullary nailing with TENS can be considered superior to any other surgical fixation because it provides relative stability and functional reduction without disturbing fracture hematoma in comparison with open reduction and internal fixation methods and it also avoids disturbance to the growth plate as opposed to rigid nailing. Good functional reduction, relative axial stability, preservation of fracture hematoma, thick periosteal covering and excellent blood supply of femoral diaphysis are supposed to ensure good prognosis in terms of healing and prevention of deformity.<sup>[10,11]</sup>

In this study we report the functional outcome of titanium elastic nailing in diaphyseal femur fracture in children of age group between 7 years and 14 years.

## MATERIALS AND METHODS

Observational study, conducted in Department of Orthopedics, Government medical college, Kottayam among randomly selected 35 children, of age 7-14 years of age who underwent titanium elastic intramedullary nailing. Patients were followed up regularly. Femur x-ray were taken immediately postop and at 4 weeks, 8 weeks, 12 weeks, 24 weeks, 32 weeks and the status of union is assessed in each visit. At these intervals, functional status of the patient was also assessed with Flynn's criteria for TENs. Data was entered in Microsoft excel and analyzed using IBM SPSS Statistics for Windows, Version 20.0. Armonk, NY: IBM Corp. IBM Corp. Numeric variables were expressed using mean and standard deviation and categorical variables will be expressed in frequencies.

**Sample Size:** According to the study done by Yogendra Gupta et al,<sup>[12]</sup> on femur fracture managed with Titanium Elastic Nailing, studied on 19 cases;

the functional outcome was found to be excellent in 14 cases and satisfactory in 5 cases; no poor outcome was seen.

$$\text{Sample size, } n = \frac{(za)^2}{d^2} \times pq$$

- p - Proportion of excellent outcome
- q - Proportion of satisfactory outcome
- d - Upto 20% of p

$$p = \frac{14}{19} \times 100 = 74$$

$$q = \frac{5}{19} \times 100 = 26$$

$$d = \frac{20 \times 74}{100} = 14.8$$

$$n = \frac{4 \times 74 \times 26}{14.8 \times 14.8} = \frac{7696}{219} = 34.958$$

Hence the minimum sample size required would be  $\rightarrow 35$

### Inclusion Criteria

1. Isolated closed diaphyseal shaft of femur fracture
2. Children in age group 7-14

### Exclusion Criteria

1. Compound femur fractures
2. Age <7 years and >14 years
3. Ipsilateral tibia and fibula fracture
4. Patients who don't come for follow up
5. Severely comminuted shaft of femur fracture, supracondylar fracture, sub trochanteric fracture
6. Bilateral shaft of femur fractures
7. Metabolic bone diseases
8. Polytrauma
9. Long spiral femur diaphyseal fractures

### Methodology

The surgery would be conducted under general anaesthesia or lumbar subarachnoid block with the patient in supine position. Two titanium elastic nails of equal diameter will be used. The diameter of the nail will be selected as per Flynn et al.<sup>10</sup> formula and intraoperative assessment will be done. Nails will be inserted in retrograde fashion with medial and lateral incision two or three centimetres above the physis. The nails will be driven proximally so that both are divergent and the tips extend from the level of physis to a point approximately two centimetres distal to the capital femoral physis and one centimetre distal to the greater trochanteric physis. Injectable antibiotics will be administered for three to five days after surgery followed by oral antibiotics till suture removal. Patient will be discharged on 5th -10th day post-surgery. Active toe movements and limb elevation started at first postoperative day. Postoperative x-ray will be taken on third postoperative day. Patient will be called for first follow up on day 10, 4 weeks, 8 weeks, 12 weeks, 24 weeks and 32 weeks for radiological and clinical evaluation.

At each follow up AP and lateral x-rays will be obtained. Osseous healing will be assessed radiologically by the presence of callus formation. Absence of pain and tenderness is also an evidence of fracture healing. Functional results are assessed using Flynn's Criteria which includes limb length inequality, malalignment, pain, and other complications. Results will be allocated as excellent, satisfactory and poor.

### Ethical Consideration

The study was conducted after obtaining the ethical clearance from the Ethical Committee of Government Medical College, Kottayam and

Department of Orthopedics, Government Medical college, Kottayam. Informed written consent was obtained from the cases in the study.

## RESULTS

**Table 1: Distribution of gender**

Gender	Frequency	Percent
Male	25	71.4
Female	10	28.6

Most of the children presented with femur fracture was of male gender, constituting 71.4%.

**Table 2: Descriptive Statistics of the study population**

Variable	N	Minimum	Maximum	Mean	Std. Deviation
Age in years	35	7	14	10.26	2.28
Weight in Kg	35	18	41	28.71	7.14

**Table 3: Age Distribution**

Age group	Frequency	Percentage
7-10 years	21	60
11-14 years	14	40
Total	35	100

Majority of the children were between the age group 7-10 years, constituting 60%. Mean age was 10.26 years.

**Figure 4: Weight Distribution**

Weight (range)	Frequency	Percentage
18- 29kg	19	54.3
30-41kg	16	45.7
Total	35	100

Most of the patients presented with femur fracture were between 30-41kg, constituting 54.3%. Mean weight was 28.71kg.

**Table 5: Side involved**

Side	Frequency	Percentage
RIGHT	22	62.9
LEFT	13	37.1
Total	35	100

Most of the children had right side femur fracture accounting for 62.9%.

**Table 6: Mechanism of injury**

Mechanism of injury	frequency	percentage
ROAD TRAFFIC ACCIDENT	30	85.7
FALL FROM HEIGHT	5	14.3
Total	35	100

Most common mechanism of femur fracture in children were road traffic accident, constituting 85.7%.

**Table 7: Site of fracture**

Site	Frequency	Percentage
PROX. 1/3RD AND MIDDLE 1/3RD JUNCTION	10	28.6
MIDDLE 1/3RD	21	60
MIDDLE 1/3RD AND DISTAL 1/3RD JUNCTION	4	11.4
Total	35	100

Most common site of fracture shaft of femur seen in children were middle 1/3rd, constituting 60%.

**Table 8: Pattern of fracture**

Pattern	Frequency	Percentage
Transverse	26	74.3
Oblique	9	25.7
Total	35	100

Most of the pattern of fracture femur encountered in children in this study were transverse, constituting 74.3%.

**Table 9: Reduction technique used**

Reduction Technique	Frequency	Percentage
Closed	35	100
Open	0	0
Total	35	100

**Table 10: Site of nail entry**

Site	Frequency	Percentage
Retrograde	35	100
Anterograde	0	0
Total	35	100

All the elastic nails were inserted in a retrograde manner in all children in this study.

**Table 11: Method of immobilization postoperatively**

Immobilization	No Of Cases	Percentage
Above Knee Slab	8	22.8
Knee Immobiliser	10	28.6
None	17	48.6
Total	35	100

Most of the children underwent titanium elastic nailing 48.6 % had their gentle ROM restarted from POD 2 without any immobilization, while 28.6 % were on knee immobilizers during initial 10 days postop till pain subsided and ROM done as tolerated.

**Table 12: Time for fracture union**

Time For Union	Frequency	Percentage
8-12 Weeks	10	28.7
12-16 Weeks	15	42.8
16-20 Weeks	9	25.7
20-24 Weeks	1	2.8
>24 Weeks	0	0
Total	35	100

Most the fracture united from time period of 8- 16 weeks, 42.8 % of fracture united by 12-16 weeks followed by 8-12 weeks, with 28.7%. Mean time for union was found to be 14.11 weeks with standard deviation of 3.29.

**Table 13: Complications Encountered in the Study**

Complication	Frequency	Percentage
Pain	0	0
Nail site infection	3	8.6
Limb length discrepancy	20	57.1
Malunion	1	2.8
Nonunion	0	0
Knee stiffness	0	0
Refracture	0	0

**Table 14: Outcome as by Flynn's Grading**

Grading	Frequency	Percent
Excellent	26	74.3
Satisfactory	8	22.9
Poor	1	2.9

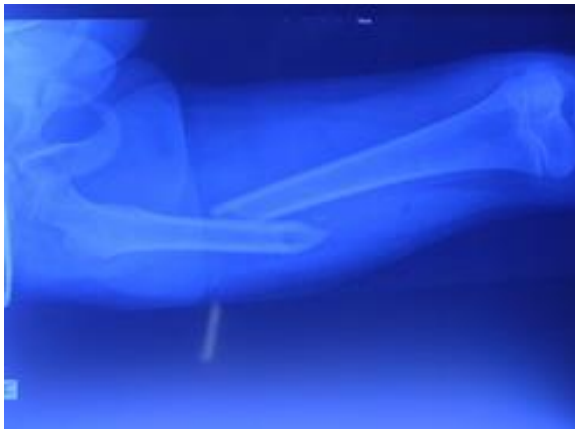
Out of the total 35 children 20 children showed limb length discrepancy constituting 57.1%. As per by the Flynn's criteria out of these children showing limb discrepancy; 14 were having limb length discrepancy less than 1cm, 5 children have less than 2cm LLD and only one child had more than 2cm LLD with varus malunion. Of the 35 cases, the one which had malunion showed better range of movement of knee and hence was left alone. Entry nail site infection were seen in 3 cases and was treated by appropriate oral antibiotics and infections subsided in all of them.

No cases showed nonunion in the study. As had satisfactory knee range of movement with no knee stiffness. Out of all the cases none had refracture.

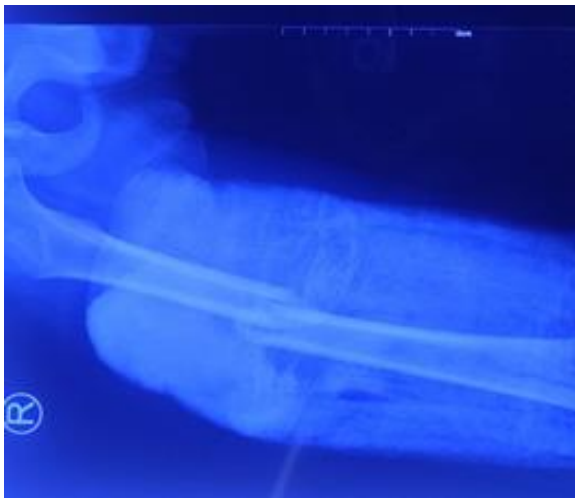**Inference:** Out of 35 patients, 74.3 % had excellent score, 22.9% had satisfactory score and 2.9% had poor score on Flynn's criteria.

**Clinical photographs**

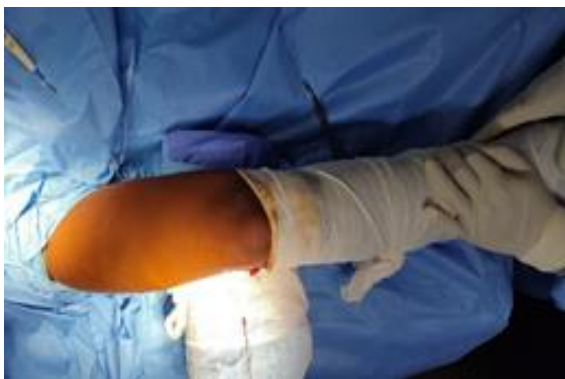**Case 1: preoperative x-ray**



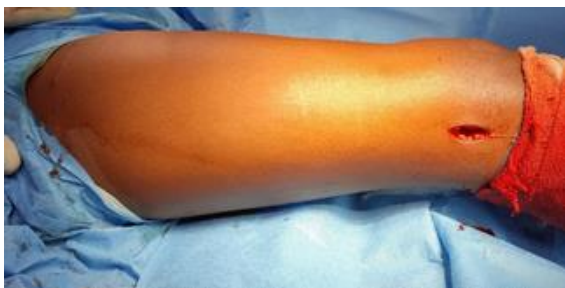**Intraoperative Pictures**



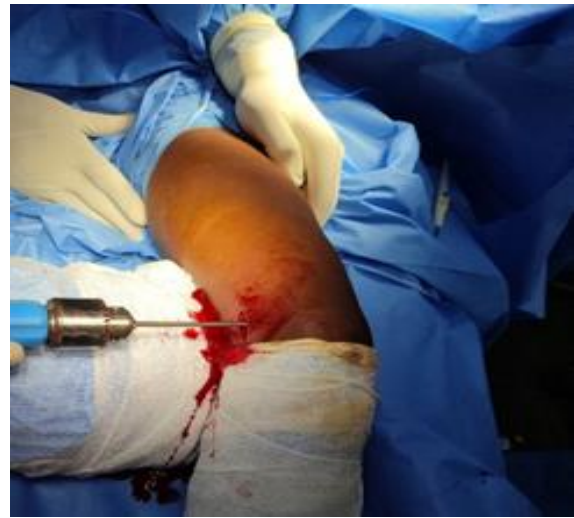**Preoperative x-ray**



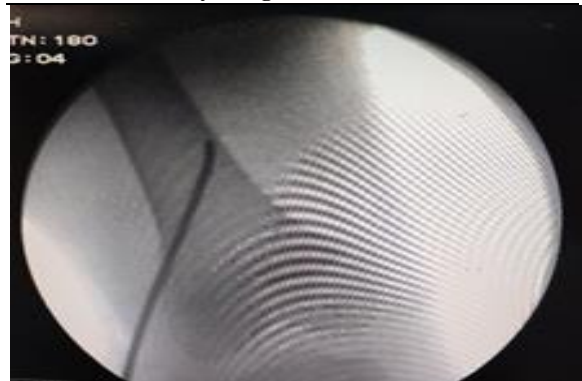
**Limb positioning**



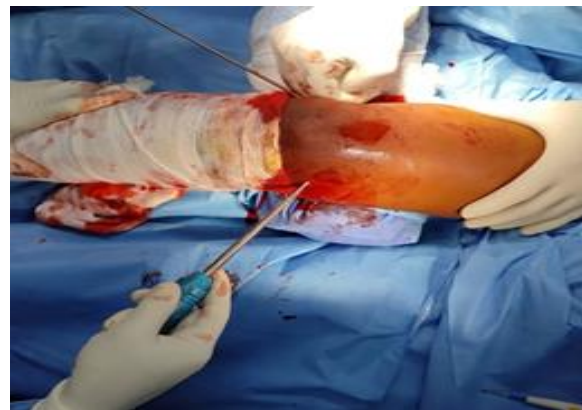**Lateral incision of size 2.5 cm**



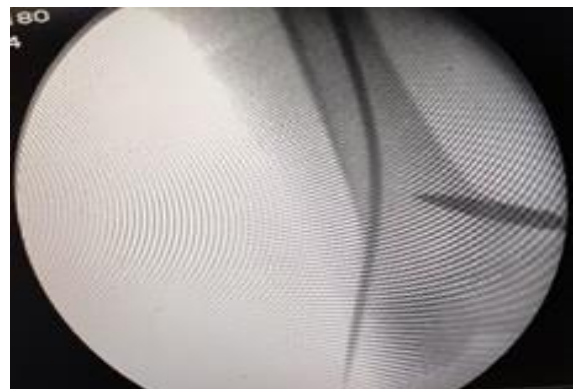**Lateral TENs entry using T- handle**



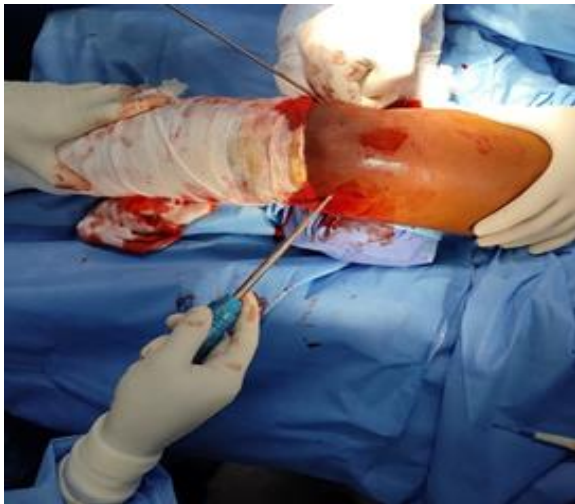**C-ARM picture of lateral entry**



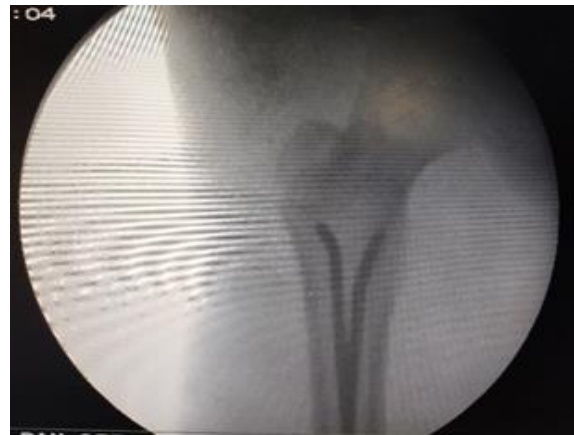**Creating a medial entry using a bone awl**



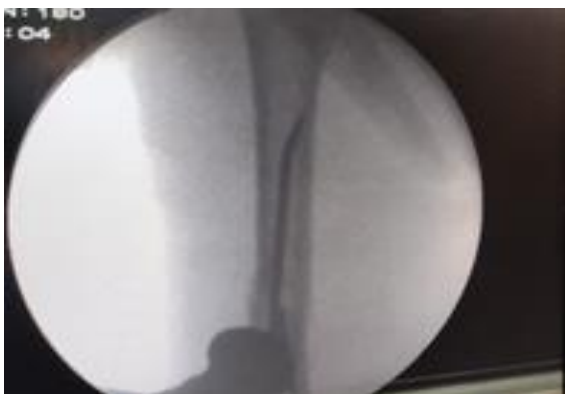**Creating a medial entry for TENs using awl**



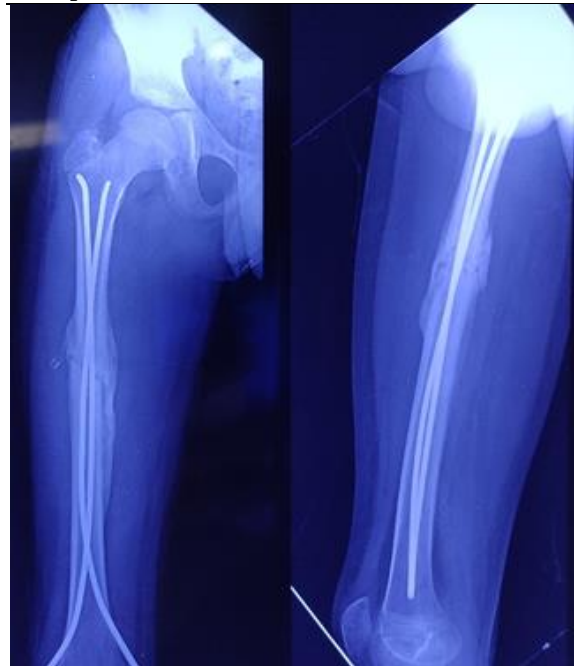**Awl angulated at 45 degrees for desired nail path**



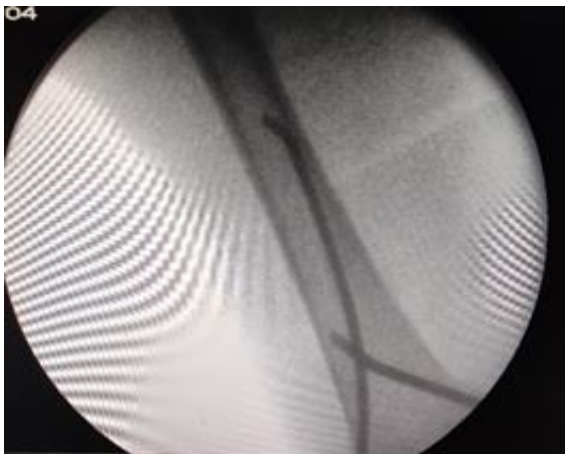**Final position of the TENS**



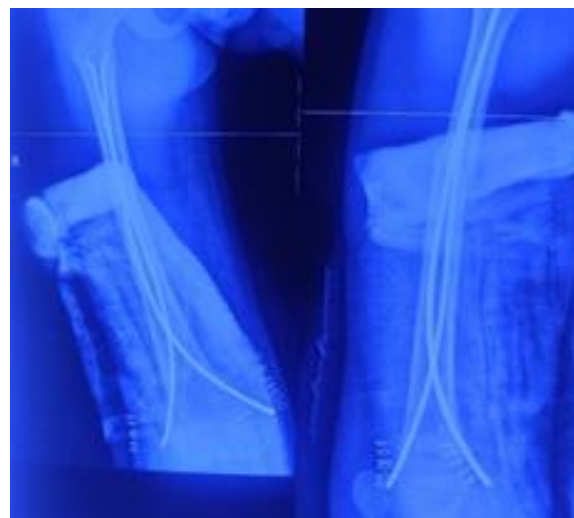
**Crossing nail one at a time to achieve reduction**



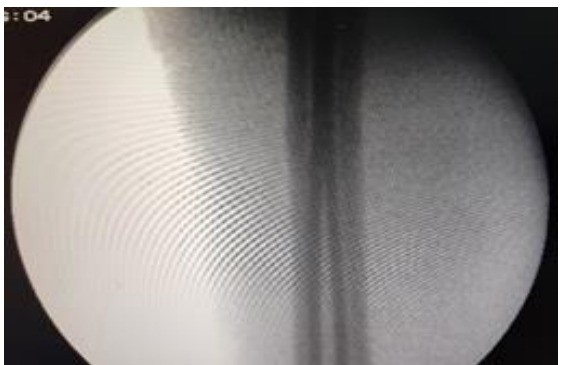**12 weeks postop**



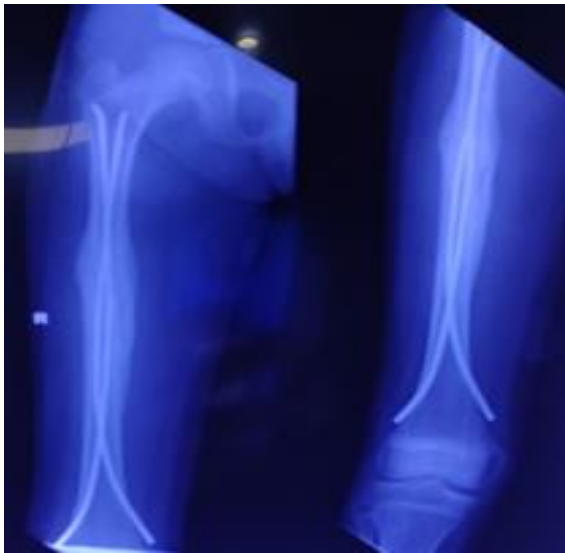
**Insertion of a medial TENS**



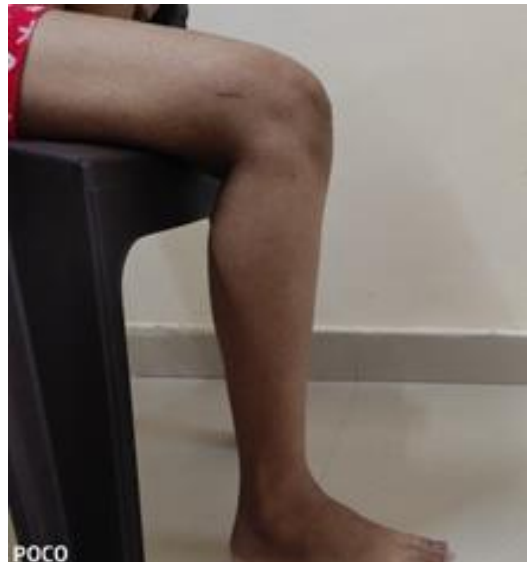**Postoperative x-ray taken on day 3**



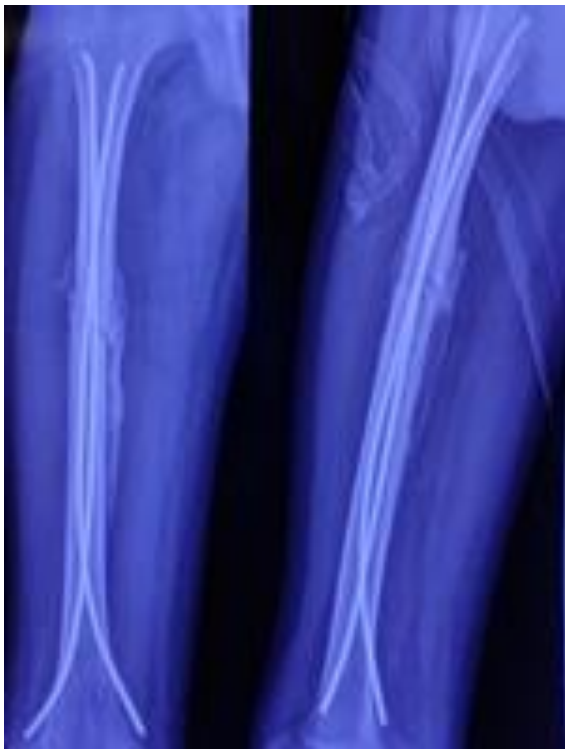**Fracture site reduced anatomically after passage of 2nd nail**



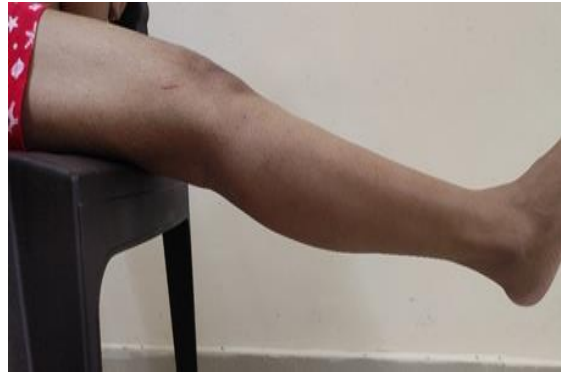**16 weeks postop shows complete union**



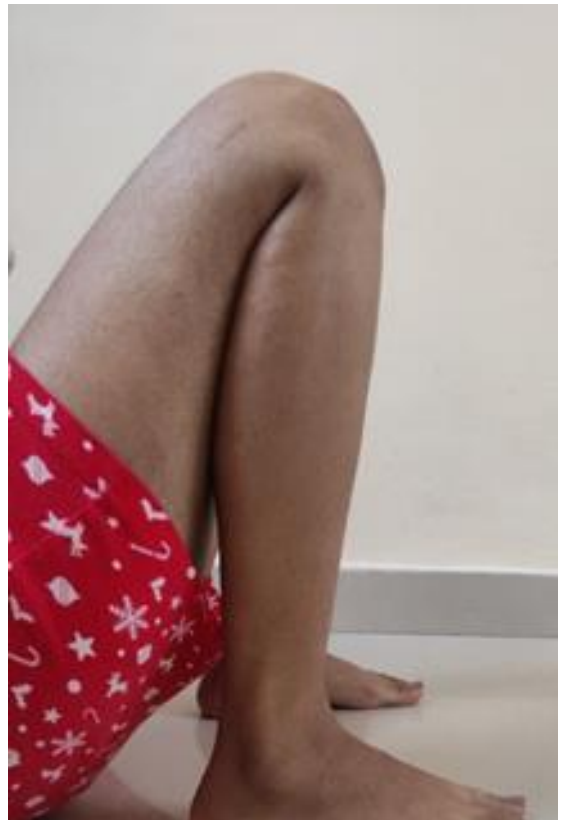**90 degrees flexion after 16 weeks postop**



**After 6 weeks postop**



**Full flexion of knee at 16 weeks postop**



**Full flexion of knee 16 weeks postop**

## DISCUSSION

Historically, fracture femur was initially treated conservatively in older times due to high potential of fracture healing in children.<sup>[13]</sup> However due to the advancement of surgical techniques has defied the conservative management and now several implants are available that allow the fracture union to be prompt and providing axial and rotational stability. This helps to provide early mobilization for the child and thereby decreasing the hospital stay and cost of treatment. Titanium elastic nail (TENs) has revolutionised the treatment of the pediatric femur fracture. One of challenges faced for surgical procedures were to prevent physal injury during the surgery. Due to the physis sparing nature of entry and its extreme malleability TENs have become a prominent fixation device.<sup>[14,15]</sup>

Titanium elastic nail are inserted in retrograde manner as it gives more stability compared to the anterograde insertion. Retrograde nail fixation has significantly less axial range of motion and more torsional stiffness than anterograde fixation particularly in transverse fracture pattern. The length and rotational control with two divergent flexible intramedullary nails may be sufficient for early mobilization. Usually medial and lateral entries are used.<sup>[16]</sup>

Our study was aimed at assessing the functional outcome of titanium elastic nailing in diaphyseal femur fracture in children aged between 7 and 14 years. We assessed 35 children of diaphyseal femur fracture at our institution.

The study showed that majority of cases (74.3%) had excellent functional outcome as by Flynn's criteria, satisfactory outcome in 8 cases (22.9%) with only one child showing poor outcome signifying that titanium elastic nailing alone is an effective and safe treatment method for the treatment of diaphyseal femur fracture in children. This study was seen to be consistent with many of the previous studies undertaken in many other institutions.

Fracture of the middle third diaphysis was the most common site of injury due to the fact that at the time of injury, the patient might have suffered direct impact and axial loading. Transverse fracture was the most common type of fracture pattern seen in our study similar to that was seen in most of the other studies.<sup>[17-20]</sup>

Limb length discrepancy is a common complication in pediatric femur fractures.<sup>[21,22]</sup> In our study limb length discrepancy was seen in 20 cases of which only one case had shortening of >2cm that resulted due to comminution of medial cortex near the fracture site occurred intraoperatively which resulted in a varus malunion in later stage. All the other cases had excellent and satisfactory results as per by Flynn's grading of TENs.

In our study most common gender involved was found to be males with a mean age of 10.26 years and mean weight of 28.71kg with standard deviation of

2.28 and 7.14 respectively. Most common mechanism of injury being road traffic incident. Nail entry site infection occurred in 3 cases which were all subsided by subsequent administration of the appropriate antibiotics. Mean time for union was found to be 14.11 weeks with standard deviation of 3.29.

Knee stiffness occurred in none of the cases in our study due to early range of movement exercise started postoperatively. This was coupled up which quadriceps strengthening exercises particularly in those whose had a period of immobilization postoperatively once the pain subsided the results coincides with few studies.<sup>[23,24]</sup>

## CONCLUSION

Based on our study and results, Titanium elastic nailing System is an effective and efficient method for the treatment of diaphyseal fractures of pediatric diaphyseal femur fracture in the age group between 7 to 14 years. It is cost effective, with minimal complications and gives excellent outcome.

## REFERENCES

1. Mangunath S Daragad, Sunilkumar P D, Chidendra M shettar, Santhosh Jeevannavar, RavirajTantry. Study of functional outcome of Titanium elastic nailing in pediatric shaft of femur; our experience in 20 cases; published March 2016
2. Sijad Ahmed Mahar , Mohammad Kashif Abbasi, AzizullahBhayo, M ShoaibChandio, Hussain Buxpalh, Sajjad Hussain Bhatti; study on functional outcome of intramedullary fixation using titanium elastic nailing in diaphyseal fracture of femur in children
3. Thapa SK, Poudel K P, Marasini R P, DhakalS, Shrestha R, Pediatric diaphyseal fracture femur treated with intramedullary titanium elastic nailing system. JCMS Nepal.2015;11(2):20-22
4. Devesh Bandil, MeghaguptaBandil. Assessment of results of treatment of pediatric femoral diaphyseal fractures with titanium elastic nails. International Journal of contemporary medicine surgery and radiology.2018;3(2):8121-8123
5. Bhuyan BK, Mohan Singh S. Titanium elastic nailing in pediatric femoral diaphyseal fractures in the age group of 5-16 years - A short term study. J ClinOrthop Trauma. 2014 Dec;5(4):203-10.
6. Kayaokay K, Aktuglu K. Titanium elastic nailing in pediatric femoral diaphyseal fractures in the age group of 6-15 years mid-term and long-term outcomes. Pak J Med Sci. 2018 Nov-Dec;34(6):1529-1533.
7. Ajay Kumar, Deepak Saxena, Nazim Mughal, Deepankar Mishra. Evaluation of diaphyseal femoral fractures in children treated with tens nailing: A clinical study. Int J Orthop Sci 2021;7(1):490-493.
8. Ligier JN, Metaizeau JP, Prévot J, Lascombes P. Elastic stable intramedullary nailing of femoral shaft fractures in children. The Journal of bone and joint surgery. British. 1988; 70(1):74-7.
9. Navdeep S, Kanav P, Suhail V, Harish D. Closed reduction and internal fixation of fractures of the shaft of the femur by the Titanium Elastic Nailing System in children. The Internet Journal of Orthopedic Surgery, 2010, 17(1).
10. Flynn JM, Hresko T, Reynolds RA, Blasier RD, Davidson R, Kasser J. Titanium elastic nails for pediatric femur fractures: a multicenter study of early results with analysis of complications. J PediatrOrthop. 2001 Jan-Feb; 21(1):4-8.
11. Houshian S, Gøthgen CB, Pedersen NW, Harving S. Femoral shaft fractures in children: elastic stable intramedullary nailing in 31 cases. Acta Orthop Scand. 2004 Jun; 75(3):249-51.



12. Gupta, Yogendra & Jha, Ranjib& Ghimire, Nischal& Mishra, Bibhuti&Kam, Navin. (2016). Retrograde titanium elastic nailing in management of length unstable paediatric femoral shaft fracture. *Indian Journal of Orthopaedics Surgery*. 2. 407-414.
13. Donati F, Mazzitelli G, Lillo M, Menghi A, Conti C, Valassina A, Marzetti E, Maccauro G. Titanium elastic nailing in diaphyseal femoral fractures of children below six years of age. *World J Orthop*. 2017 Feb 18;8(2):156-162
14. Saikia K, Bhuyan S, Bhattacharya T, Saikia S. Titanium elastic nailing in femoral diaphyseal fractures of children in 6-16 years of age. *Indian J Orthop*. 2007 Oct;41(4):381-5. doi: 10.4103/0019-5413.33876.
15. Jalan D, Chandra R, Sharma VK. Results of titanium elastic nailing in paediatric femoral diaphyseal fractures----report of 30 cases. *Chin J Traumatol*. 2013;16(2):77-83.
16. Mishra AK, Chalise PK, Shah SB, Adhikari V, Singh RP. Diaphyseal femoral fractures in children treated with titanium elastic nail system. *Nepal Med Coll J*. 2013 Jun;15(2):95-7.
17. Rajak MK, Thakur R, Choudhary A, Bhaduri I, Kumar S. Titanium elastic nailing in femoral diaphyseal fractures in children of 6-14 years age. *Acta Orthop Belg*. 2016 Dec;82(4):883-888.
18. Kumar S, Roy SK, Jha AK, Chatterjee D, Banerjee D, Garg AK. An evaluation of flexible intramedullary nail fixation in femoral shaft fractures in paediatric age group. *J Indian Med Assoc*. 2011 Jun;109(6):416-7, 425.
19. Lohiya R, Bachhal V, Khan U, Kumar D, Vijayvargiya V, Sankhala SS, Bhargava R, Jindal N. Flexible intramedullary nailing in paediatric femoral fractures. A report of 73 cases. *J Orthop Surg Res*. 2011 Dec 22;6:64.
20. Khazzam M, Tassone C, Liu XC, Lyon R, Freeto B, Schwab J, Thometz J. Use of flexible intramedullary nail fixation in treating femur fractures in children. *Am J Orthop (Belle Mead NJ)*. 2009 Mar;38(3):E49-55.
21. Pogorelič Z, Vodopić T, Jukić M, Furlan D. Elastic Stable Intramedullary Nailing for Treatment of Pediatric Femoral Fractures; A 15-Year Single Centre Experience. *Bull Emerg Trauma*. 2019 Apr;7(2):169-175.
22. Murphy JS, Koehler R, Johnson M, Hosseinzadeh P. Flexible Intramedullary Nailing of Pediatric Femoral Fractures. *JBJS Essent Surg Tech*. 2021 Mar 2;11(1):e19.00064.
23. Khan JA, Singh GP, Pandey A. Outcome of Titanium Elastic Intramedullary Nail in the Treatment of Shaft of Femur Fracture in Children. *Kathmandu Univ Med J (KUMJ)*. 2015 Jul-Sep;13(51):195-9.
24. Govindasamy R, Gnanasundaram R, Kasirajan S, Ibrahim S, Melepuram JJ. Elastic Stable Intramedullary Nailing of Femoral Shaft Fracture-Experience in 48 Children. *Arch Bone Jt Surg*. 2018 Jan;6(1):39-46.