

PREDICTIVE ACCURACY OF ULTRASONOGRAPHY IN ASSESSING THE SEVERITY OF SOLID ORGAN INJURY COMPARED TO CONTRAST ENHANCED COMPUTED TOMOGRAPHY IN 113 CASES OF BLUNT ABDOMINAL TRAUMA

Babitha Babu¹, Reeba George Pulinilkunnathil², Amilu Elsa Varghese³, Anil Raj KK⁴, Shaiji P.S⁵

Received : 12/11/2022
Received in revised form : 09/12/2022
Accepted : 22/12/2022

Keywords:

Blunt abdominal trauma, ultrasonography, CECT, solid organ injury, liver, spleen, kidney, high grade and low grade injuries.

Corresponding Author:

Dr. Shaiji P.S,
Email: shaijimehar@gmail.com
ORCID: 0000-0002-1823-2243

DOI: 10.47009/jamp.2023.5.1.158

Source of Support: Nil,
Conflict of Interest: None declared

Int J Acad Med Pharm
2023; 5 (1); 280-285



¹Assistant Professor, Department of Radiodiagnosis, Travancore Medical College Hospital, Kollam, Kerala, India

²Associate Professor, Department of Radiodiagnosis, Government Medical College, Kollam, Kerala, India

³Assistant Professor, Department of Radiodiagnosis, Government Medical College, Kottayam, Kerala, India

⁴Professor and Head, Department of Radiodiagnosis, Government Medical College, Kollam, Kerala, India

⁵Associate Professor, Department of Transfusion Medicine, Government Medical College, Kollam, Kerala, India

Abstract

Background: To evaluate the severity of solid organ injury in patients presenting with blunt abdominal trauma using ultrasonography while taking CECT abdomen as the radiological gold standard and its usefulness in the decision making of the management. **Materials and Methods:** 113 patients with blunt abdominal trauma, referred to Department of radiodiagnosis for ultrasonography and CECT were included in this study after applying the inclusion and exclusion criteria. The ultrasound scans were performed in these patients to detect the presence of free fluid and to look for evidence of solid organ injury namely liver, spleen and kidney. Those with positive scans are suggested for CECT abdomen for confirming the organ injury and its grading using AAST grading system. The ultrasonographic findings were compared with the CECT findings. **Result:** US examination were positive for free fluid in 104 patients (92%) and for solid organ injury in 50 patients (44.2%). Sensitivity, specificity, positive predictive value, negative predictive value and accuracy in detecting solid organ injury by ultrasound were 66.6%, 92.1%, 94.3%, 55.5% and 75.2% respectively. Combined sensitivity, specificity, positive predictive value, negative predictive value and accuracy in detecting a high-grade solid organ injury is 42.8%, 92.5%, 83.3%, 64.9% and 69.3% respectively. **Conclusion:** Ultrasonography can be considered the initial imaging modality in evaluation of blunt abdominal trauma patients as it has a good sensitivity and positive predictive value for detecting free fluid and is sufficient to follow up the patients with clinical observation. However, Ultrasonography is found to be less sensitive in detecting the solid organ injuries like lacerations, hematomas, vascular injuries and renal collecting system injuries and not sufficient for grading.

INTRODUCTION

Blunt abdominal trauma is a leading cause of both morbidity and mortality in patients in the emergency department. Rapid diagnosis and treatment are considered vital in the successful management of the trauma patient. The recent trend of management is in favor of non-operative or conservative surgical management of abdominal solid visceral injuries

with provided higher non-invasive radiological modalities for assessment of injury.

CT scans has become the radiological gold standard investigation in assessing blunt abdominal trauma as they produce very detailed images, and are noninvasive. It is also useful for localising, identifying and assessing severity of solid organ injury helping guide the nonoperative management or surgical planning. CT scans do however have their limitations and disadvantages, the principal one

being the need to transfer the patient to the scanner from the emergency department and is hence time consuming. The procedure also requires specialised radiographers to perform the investigation.

However, in patients with organ injuries especially when hemodynamically unstable where time is critical, ultrasound is very useful as it is quick and can be done at the bedside simultaneously with resuscitation procedures. It is undertaken after the primary survey in order to identify the presence of free fluid in the peritoneal cavity, which may represent haemoperitoneum, and thus enable early referral for further imaging (CT), and/or surgery if necessary.

Despite the popularity of USS, there remains a lack of clarity with regards to the grading and extent of the solid organ injuries like liver, kidney and/or spleen injuries and evidence around its contribution to the management of the patient and patient's survival particularly in an area like rural setup where the resources are limited with non-availability of ICU, skilled manpower and advanced imaging techniques.

The present study is carried out to assess the usefulness of ultrasonography in diagnosing the severity of solid organ injuries like liver, spleen and/or kidney injuries and its contribution in the decision of management in patients with blunt abdominal trauma and thereby to limit the need for further imaging with CT scans.

MATERIALS AND METHODS

Study design: cross sectional study

Study setting: Radiodiagnosis department, medical college, Thiruvananthapuram.

Study period: 18 months

Study Population

Inclusion Criteria

Patients with blunt abdominal trauma referred to radiology department for ultrasound scan, in whom free fluid is detected with or without evidence of liver, kidney and/or spleen injury.

Exclusion Criteria

1. Patients with obvious hollow viscus injury.
2. Those patients who cannot be followed up
3. Patients with penetrating abdominal injuries.

Technique

The ultrasound scans are performed in patients with blunt abdominal trauma using Philips ClearVue 650 machine using a 3.5 MHz curved array transducer. The presence of free fluid in the peri/subhepatic, perisplenic, perirenal and pelvis was interpreted as a positive scan. Along with it, assessment of solid organs like liver, kidneys and spleen done to look for findings like lacerations, contusions or subcapsular hematomas. Those with positive scans are suggested for CECT abdomen for confirming the organ injury and its grading using AAST grading system.

A noncontrast CT was taken initially and then these patients receive a bolus of intravenous contrast material (50-100ml) via 18- or 20-gauge cannula located in a large peripheral vein. In our institution, 128 slice multidetector CT scanner is used with which images are obtained at arterial phase (15-25s), venous phase (40-60s) and delayed phase (5-8mins).

The ultrasonographic findings were compared with the CECT findings. Then the subsequent management of the patient is followed up. The percentage of patients who required laparotomy are calculated based on the grading of injury.

Ultrasonographic diagnosis was placed in the following categories

1. **True Positives**– when ultrasonographic diagnosis is confirmed by CECT.
2. **True Negatives**– Both ultrasonography and CECT are negative
3. **False Positives**– Ultrasonography findings are positive with negative CECT findings.
4. **False Negatives**– Ultrasonography was negative with positive CECT findings.

Based on the above categories sensitivity, specificity, positive predictive value and negative predictive value were calculated for comparison between ultrasonography and CECT. P value of less than 0.05 will be significant.

Sampling

Sample Size: 113

Based on the study by Nural MS(1), Yardan T, Güven H, Baydin A, Bayrak IK, Kati C. Diagnostic value of ultrasonography in the evaluation of blunt abdominal trauma. *Diagn Interv Radiol.* 2005 Mar;11(1):41-4. In about 454 patients with blunt abdominal trauma, the sensitivity is 86.5%

Sample size is calculated by the formula: No. of positive cases = $(Z@)2X PQ/D2$

Where Z@ is a constant 1.96, P -86.5% and Q is 1-sensitivity, ie 13.5% and D is allowable error taken as 10.

Substituting in the formula,

Total no of positive cases = $(3.84 \times 86.5 \times 13.5) / 10 \times 10 = 44.86$

In a pilot study conducted in department of Radiodiagnosis, Medical College hospital, Trivandrum, where 10 patients with blunt abdominal trauma showing free fluid in ultrasound scan were subjected to CECT imaging, 4 were diagnosed to have solid organ injury.

Hence prevalence of solid organ injury by CECT in patients with positive USG to be about 40%.

Sample size = $44.86 \times 100/40 = 113$

Sampling technique: Consecutive sampling

Data Collection Tools:

Semi Structured questionnaire which includes the following variables.

1. Patients details
 2. Mode of injury
 3. Clinical examination findings: blood pressure, abdominal findings like guarding, tenderness.
 4. US findings: Presence of free fluid in hepatorenal pouch, perisplenic, cul de sac in pelvis and/ or perirenal region. Presence of alteration of echogenicity involving liver, kidney or spleen.
 5. CT findings: Presence of hemoperitoneum.
- Presence of laceration or subcapsular hematoma in liver kidney and or spleen.
 Ultrasonographic criteria for diagnosis of Liver injury

1. Laceration:

- <3cm from the capsular surface
- >3cm from the capsular surface.

2. Subcapsular hematoma

- <50% of the surface area
- >50% of the surface area

3. Intraparenchymal hematoma

- <10cm in diameter
- >10cm in diameter.

4. Vascularity

- Present
- Absent

Ultrasonographic criteria for diagnosis of splenic injury.

1. Laceration:

- <3cm parenchymal depth
- >3cm parenchymal depth

2. Subcapsular hematoma:

- <50% of the surface area
- >50% of the surface area

3. Intraparenchymal hematoma

- <5cm in diameter
- >5cm in diameter

4. Vascularity:

- Present
- Absent

Ultrasonographic criteria for diagnosis of renal injury

1. Laceration:

- <1cm depth
- >1cm depth

2. Subcapsular hematoma

- Present
- Absent

3. Vascularity

- Present
- Absent

The ultrasound criteria (i) are taken as low grade and (ii) as high grade injuries.

CECT Findings

1. Presence of hemoperitoneum.
2. Grading of liver/spleen and kidney injury by AAST grading.

Grade 1 and 2 were taken as low grade, grade 3 and higher as high grade.

Data Analysis

From the obtained data, the sensitivity, specificity, positive predictive value, negative predictive value, positive and negative likelihood ratios were calculated by comparison between ultrasonography and CECT findings. It was derived from 2x2 table with rows representing ultrasonography positive and negative cases as well as columns representing CECT positive and negative cases. All statistical analysis were performed with the help of Medcalc and DAG_stat software. Values of p less than 0.05 were considered statistically significant.

RESULTS

In this study of 113 patients, the most commonly affected age group was 21-30years with a mean age group of 26 years. Patients who sustained blunt abdominal injury were more of males accounting for 69% of total study population. 5 of the patients had recorded hypotension when referred to our department for ultrasound examination with hemodynamic supports. 4 patients had developed hypotension later and was referred for CECT study. 92% of the patients were normotensive.

All these patients had done CECT to look for intraabdominal organ injuries. Free fluid negative patients were also subjected to CECT examination due to clinical suspicion of organ injury. Hemoperitoneum was detected in 108 patients by CT examination. 3 of the patients had low grade injury with no hemoperitoneum. 2 patients were false positive. Free fluid was detected in 102/108 patients correctly by USG with 2 false positives out of 5 patients with no free fluid by CECT. Sensitivity was 94.4%, Specificity,60%PPV was 98% NPV 33.3% and Accuracy 92.9%

Apart from looking for free fluid, these patients were also evaluated for any injuries in the solid organs like liver, spleen and kidneys. Presence of laceration or contusions as change in the normal echogenicity of these organs, presence of subcapsular hematoma and vascularity of vessels in the hilum was carefully looked for. Hence by ultrasound, 50 cases were found to have findings. 3 cases were detected to have retroperitoneal hematoma. Rest of the cases didnot show any evidence of solid organ injury by USG. Out of the 50, liver was found to be affected in 18 cases, spleen in 16 cases and kidney in 16 cases. Of the 16 renal injuries detected by ultrasound, 10 were true positives and 6 were false positive.

Considering the high grade injuries of the solid organs, among the liver injuries, only 4 high grade injuries were detected by ultrasound where no false positive was found. However, 11 patients were false negative and was classified as low grade, thereby underestimating the injuries.

Out of 4 high grade splenic injuries found by USG, 1 was false positive and 4 was false negative.

Out of the 10 high grade and 6 low grade renal injury graded by USG, 2 were found to be false positive. 2 cases of high-grade renal injury were missed and 3 cases had injury to pelvicalyceal system and were mistaken as low-grade injuries. Combined sensitivity, specificity, PPV, NPV and accuracy in detecting a high-grade injury of solid organ by ultrasound were found to be 42.8%, 92.5%, 83.3%, 64.9% and 69.3% respectively. Since high grade injuries were more likely to be taken for surgical management, detection of high-grade injuries of the solid organs of interest were calculated.

The sensitivity of detecting a high-grade liver injury by ultrasound is quite low. However specificity is found to be 100%. PPV and NPV is 100% and 64.5% respectively for ultrasound detection of a high-grade splenic injury, the specificity is 93.8% and sensitivity is only 42.8%. PPV and NPV is 75% and 71.4% respectively. For detecting a high grade renal injury by ultrasound, the sensitivity and specificity is found to be low as 38% and 50% respectively. PPV is 80% and NPV is 28.5%. Results are summarized in [Table 2 and 3].

[Figure 1] shows a case of Segmental infarction of upper pole of right kidney where Longitudinal scan of right kidney appears normal in grey scale imaging. On colour doppler, absence of vascularity noted in the upper pole, suggestive of segmental infarction and graded as high-grade injury [Figure 2] shows the same case where Axial CECT confirms

the diagnosis of segmental infarction of the upper pole of right kidney which is Grade 4.

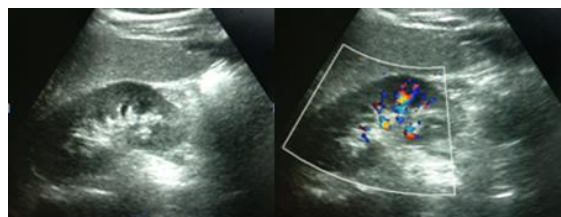


Figure 1. USG images of patient with segmental infarction of upper pole right kidney which shows normal USG but absence of vascularity in doppler.

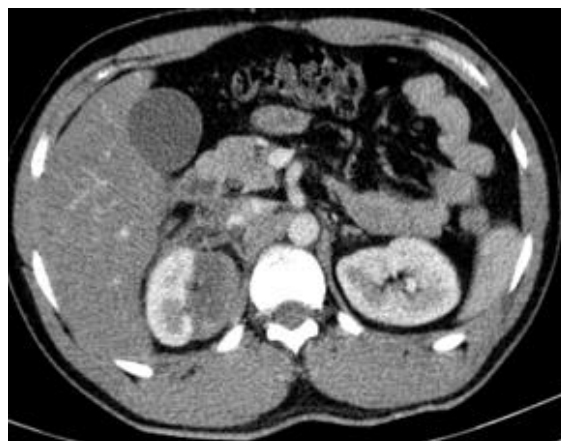


Figure 2: CECT image of the same patient with renal injury showing segmental infarction in upper pole of right kidney

Table 1: Demographic and clinical characteristics of participants

Age in years	Frequency	Percent
≤20	14	12.4
21 - 30	43	38.1
31 - 40	25	22.1
41 - 50	15	13.3
51 - 60	13	11.5
>60	3	2.7
Total	113	100.0
SEX		
Male	78	69.0
Female	35	31.0
Total	113	100.0
BP		
Normal	104	92.0
Low	9	8.0
Total	113	100.0
USG free fluid		
Negative	11	9.7
Peri/subhepatic	61	54.0
Perisplenic	17	15.0
Perirenal	8	7.1
Pelvis	14	12.4
Retroperitoneal Spaces	2	1.8
Total	113	100.0

Table 2: Predictive accuracy of USG compared to CECT in assessing solid organ injury

	COMPARISON WITH CECT		Diagnostic accuracy
	USG Positive out of CECT positive	USG Negative out of CECT negative	
Liver injury	16/35		Sensitivity 45.7% Specificity 95% PPV 88.8% NPV 66.6% Accuracy 72%

Splenic injury	12/23	48/52	Sensitivity 52.2% Specificity 92.3% PPV 75% NPV 81.3% Accuracy 80%
Renal injury	10/17	52/58	Sensitivity 58.8% Specificity 89.6% PPV 62.5% NPV 88.1% Accuracy 82.6%

Table 3: Predictive accuracy of USG compared to CECT in assessing High grade solid organ injury

	COMPARISON WITH CECT		Diagnostic accuracy
	USG Positive out of CECT positive	USG Negative out of CECT negative	
Any high-grade organ injury (liver/spleen/kidney)	15/35	37/40	Sensitivity 42.8% Specificity 92.5% PPV 83.3% NPV 64.9% Accuracy 69.3%
Liver injury High Grade	4/15	20/20	Sensitivity 26.6% Specificity 100% PPV 100% NPV 64.5% Accuracy 68.5%
Splenic injury High Grade	3/7	15/16	Sensitivity 42.8% Specificity 93.8% PPV 75% NPV 71.4% Accuracy 78.2%
Renal injury High Grade	10/17	52/58	Sensitivity 38% Specificity 50% PPV 80% NPV 28.5% Accuracy 58.8%

DISCUSSION

The use of sonography and CT for assessment in blunt abdominal trauma has been extensively reviewed in the literature. CT is viewed as the definitive technique because of its high sensitivity and specificity in injury detection, localization, and grading. In abdominal trauma cases, the completion of the CT examination within minutes is an advantage and the contrast delineating even the smallest lacerations is a further advantage, which renders CT significantly superior to US.

Sonography has some specific advantages over CT in that it is a bedside examination for those patients who are clinically unstable and also for pregnant patients.

This study revealed a male predominance of intrabdominal organ injury as reported in similar previous studies. The mean age was 27 years.

USG detected free fluid in 104 cases of which 2 were false positive. 6 cases were false negative in which 3 had organ injury confirmed by CT. Thus, the sensitivity of US for detecting intra-abdominal injury by the presence of free fluid is very good at 94.4%, which was similar to the findings of Yoshii et al.^[2] who reported a sensitivity of 94.6%. However, the specificity was found to be only 60%. 3 patients had intra-abdominal injury without hemoperitoneum. PPV and NPV for detection of free fluid was 98% and 33.3% respectively.

In a study by Richards et al,^[3] on 744 patients, out of 51 patients who detected to have free fluid by ultrasound, 9 were false positive. Of these 9 patients, 7 were female patients who had pelvic free fluid. Hence, most of these false positive results were reported to be originating from the physiological fluid observed in females. Also US results are operator dependent and the fluid that accumulates in the abdominal cavity physiologically or due to reasons other than trauma cannot be differentiated from hemorrhages due to trauma.

Only 9 patients with blunt abdominal trauma had hypotension in our study. Rest of the patients had normal/ hypertension. This was because the patients who are hemodynamically unstable and with multiple injuries may undergo laprotomy without imaging. Out of the 9 cases, 5 had hypotension at the time of presentation and were shifted to our department for imaging with hemodynamic supports. Rest of the 4 patients developed hypotension later and was referred for imaging suspecting intraabdominal organ injury.

Lee et al,^[4] claimed that hypotensive patients screened in the emergency department with positive USG findings may be transferred directly to laparotomy, depending on the results of the sonography examination, without the need for CT.

To detect the solid organ injury of liver, spleen and or kidney, the sensitivity, specificity, PPV and NPV obtained in our study was 66.6%, 92.1%, 94.3% and 55.5% respectively. The specificity was good

indicating that an altered echogenicity within a particular organ could suggest a traumatic injury of that organ to be more likely. This finding was almost similar to the result of a previous study in literature by Nural et al,^[1] which showed a sensitivity, specificity of 82.3% and 94.4% respectively. However out of the 75 cases of solid organ injury, only 50 cases were detected by ultrasound in the study of which only 38 were true positives.

Most commonly injured organ in this study was found to be liver, followed by spleen and kidney. This was not consistent with previous studies which showed spleen as the most commonly affected organ.^[5]

The sensitivity and specificity to detect the individual solid organs by ultrasound were 45.7% and 95% for liver, 52.2% and 92.3% for spleen and 58.8% and 89.6% for kidney respectively. Although the sensitivity were poor, the specificity was found to be fairly good for the detection of the injuries of solid organ. Specificity was high for liver injuries and least for renal injuries similar to other researchers.^[6-9] This could be because liver is a larger organ and the acoustic window for scanning is liver is good. While for scanning kidneys which are retroperitoneal organs, optimal patient positioning is important. Supine, lateral decubitus and occasionally prone positioning may be necessary for adequate imaging of kidneys. In trauma patients, who may have multiple other injuries adequate position may not be possible. Moreover, the bowel shadows and the obese habitus of the patient also cause difficulty in visualisation of kidneys. For detecting a high grade solid organ injury by USG the sensitivity, specificity, PPV, NPV and accuracy were 42.8%, 92.5%, 83.3%, 64.9% and 69.3%.

CONCLUSION

Ultrasonography can be considered the initial imaging modality in evaluation of blunt abdominal trauma patients as it has a good sensitivity and positive predictive value for detecting free fluid and

is sufficient to follow up the patients with clinical observation. However, Ultrasonography is found to be less sensitive in detecting the solid organ injuries like lacerations, hematomas, vascular injuries and renal collecting system injuries. Thus, for the accurate assessment of the grading of organ injury is less sensitive by ultrasound.

With evolving trend of conservative management for traumatic organ injuries, the major consideration in the need for surgery is the clinical status of the patient and conservative management is preferred for all those with stable hemodynamic status irrespective of the grade of injuries. Hence positive USG findings in a hemodynamically unstable patient can be taken for laprotomy without the need for further imaging.

REFERENCES

1. Nural MS, Yordan T, Güven H, Baydin A, Bayrak IK, Kati C. Diagnostic value of ultrasonography in the evaluation of blunt abdominal trauma. *Diagn Interv Radiol.* 2005 Mar;11(1):41-4
2. Yoshii H, Sato M, Yamamoto S, Motegi M, Okusawa S, Kitano M, et al. Usefulness and limitations of ultrasonography in the initial evaluation of blunt abdominal trauma. *J Trauma.* 1998;45:45-50.
3. Richards JR, Schleper NH, Woo BD, Bohnen PA, McGahan JP. Sonographic assessment of blunt abdominal trauma: A 4-year prospective study. *J Clin Ultrasound.* 2002;30:59-67.
4. Brett C, Lee E, Eleanor L, Ormsby J, John P, McGahan G, Giselle M, Melendres J, John R, Richards. The Utility of Sonography for the Triage of Blunt Abdominal Trauma Patients to Exploratory Laparotomy. *AJR* 2007; 188:415-421.
5. Jorge A. Soto, MD, Stephan W. Anderson, MD et al. Multidetector CT of Blunt Abdominal Trauma. *radiology.rsna.org Radiology: Volume 265: Number 3-December 2012.*
6. Renzulli P, Gross T, Schnüriger B, et al. Management of blunt injuries to the spleen. *Br J Surg* 2010;97(11):1696-1703.
7. Sirlin CB, Brown MA, Andrade-Barreto OA, et al. Blunt abdominal trauma: clinical value of negative screening US scans. *Radiology* 2004; 230:661-668.
8. Sirlin CB, Brown MA, Deutsch R, et al. Screening US for blunt abdominal trauma: objective predictors of false-negative findings and missed injuries. *Radiology* 2003; 229:766-774.
9. Rhea JT, Garza DH, Novelline RA. Controversies in emergency radiology: CT versus ultrasound in the evaluation of blunt abdominal trauma. *Emerg Radiol* 2004; 10:289-295.