

## A FOLLOW-UP STUDY BY FINE NEEDLE ASPIRATION CYTOLOGY IN SOLITARY NODULAR GOITRE IN GVMCH

R. Balakrishnan<sup>1</sup>, V. Nagarajan<sup>2</sup>

<sup>1</sup> Senior Assistant Professor, Department of General Surgery, Government Tiruvannamalai Medical College, Tamilnadu, India.

<sup>2</sup> Senior Assistant Professor, Department of General Surgery, Government Tiruvannamalai Medical College, Tamilnadu, India.

Received : 24/12/2022  
Received in revised form : 29/01/2023  
Accepted : 11/02/2023

**Keywords:**

Solitary nodular goitre, Hemithyroidectomy, Total thyroidectomy, Papillary carcinoma, Follicular carcinoma, Recurrent laryngeal nerve.

Corresponding Author:

**Dr. V. Nagarajan**

Email: drnagarajanv@gmail.com

DOI: 10.47009/jamp.2023.5.2.81

Source of Support: Nil,  
Conflict of Interest: None declared

*Int J Acad Med Pharm*  
2023; 5 (2); 386-389



### Abstract

**Background:** As an imperative tool in the pre-operative management of thyroid swellings, Fine needle aspiration cytology (FNAC) is a low-cost treatment that offers a precise diagnosis rapidly and with few complications. Patients can be monitored in situations of benign diagnosis and operated on in cases of malignant diagnosis based on cytology findings, reducing the risk of needless surgery.

**Aim:** The goal of our study is to investigate the age and gender distribution of patients in the study centre and to determine the prevalence of the most common solitary nodular goitre. **Materials and Methods:** This study included surgical OPD patients from GVMCH with a single thyroid nodule, evaluated individually using FNAC and ultrasound. The patient received appropriate therapeutic and surgical treatment, such as hemithyroidectomy or complete thyroidectomy with or without neck dissection. **Result:** Our prospective study comprised 100 patients, with a majority of female patients (92%) and the most prevalent age group in both genders being 30-60 years old. The nodule was identified more frequently in the right lobe of the thyroid (48%). Females had a greater incidence of the malignant nodule (88%). Only 14 and 7 individuals had papillary and follicular cancer, respectively, while the rest had benign lesions (79). All cancer patients had complete thyroidectomy with lymph node dissection, while those with benign lesions had Hemithyroidectomy. **Conclusion:** For the diagnosis of thyroid cancer, FNAC is a straightforward, easy-to-perform, cost-effective, and readily repeated method. It is suggested as the first line of treatment for a single thyroid nodule.

## INTRODUCTION

Thyroid nodules are relatively frequent, and about 8% of adults have clinically visible nodules. A solitary thyroid nodule (STN) is clinically described as a localised thyroid enlargement with otherwise normal thyroid function.<sup>[1]</sup> STN is a relatively frequent condition. The vast majority of these nodules are harmless. The primary purpose of examining these nodules is to identify those with cancerous potential.<sup>[2]</sup> The introduction of imaging methods, notably ultrasound, has greatly enhanced the likelihood of detecting thyroid nodules. In South India, the prevalence of palpable thyroid nodules is around 12.2%. However, the reported incidence of thyroid cancer in the general population is minimal, at approximately 1%. Thyroid cancer occurs in approximately 5% of all thyroid nodules, regardless of size. According to recent research, the incidence of thyroid cancer is growing over time.<sup>[3]</sup>

Only 5%–30% of thyroid nodules with a clinical diagnosis are malignant and require surgery; the remainder is benign thyroid nodules. Malignancy is more common in STN than in multinodular goitre.<sup>[4]</sup> It is critical to perform a pre-operative examination of thyroid nodules to distinguish between benign and malignant ones. It aids in avoiding unneeded lengthy surgery and potential surgery-related side effects such as hypothyroidism, hypocalcemia, and recurrent laryngeal nerve damage.<sup>[5]</sup> The physician can evaluate a thyroid nodule using a variety of diagnostic techniques such as ultrasound, thyroid nuclear scan, and fine needle aspiration cytology (FNAC).<sup>[6]</sup>

In examining a thyroid nodule, FNAC is regarded as the gold standard diagnostic test, and other procedures such as ultrasound and nuclear scan should be utilised in combination with FNAC.<sup>[7]</sup> The target lesion's location, a thorough examination for malignant cells, and a repeat FNAC are essential to a good diagnosis and the design of an effective surgical

therapy strategy for thyroid masses.<sup>[8]</sup> Any hard, palpable, single thyroid nodule or nodule connected to concerning clinical characteristics should be considered for FNAC. Any nodule associated with palpable or ultrasonographically abnormal cervical lymph nodes, suspicious ultrasonographic features, dominant or atypical nodules in a multinodular goitre, complex or recurrent cystic nodules, and any nodule associated with abnormal-appearing or palpable cervical lymph nodes should all undergo FNAC.<sup>[9]</sup> It is crucial to distinguish between benign and malignant thyroid nodules since surgery is required for the former. At the same time, thorough patient follow-up is needed in the event of a benign tumour. The primary goal of FNAC is to distinguish between benign nodules that may be watched clinically and nodules that require surgery and to reduce the overall rate of thyroidectomy in patients with benign illnesses.<sup>[10]</sup>

**Aim**

Our study's objective was to highlight the value of FNAC as a diagnostic tool and to examine the age and sex distribution of patients in our hospital. Also, to estimate the prevalence of benign and malignant neoplasms in STN, the study was designed.

**MATERIALS AND METHODS**

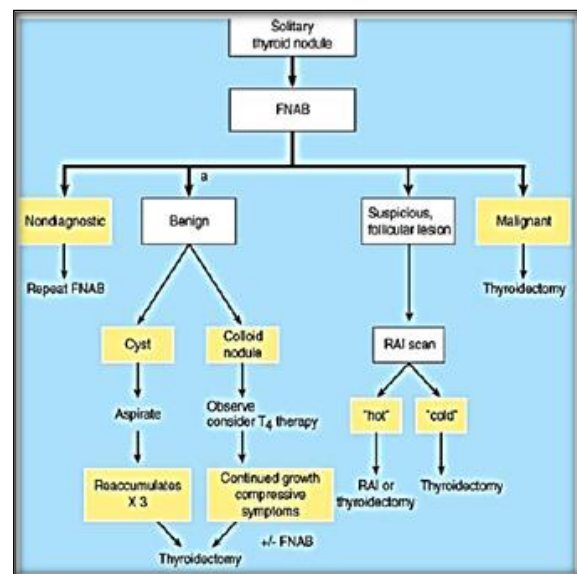
The prospective observational study was conducted at the Government Vellore Medical College's general surgery and pathology departments between October 2016 and September 2017, and it was carried out using fine needle aspiration cytology (FNC).

All age groups of males and females are included in the FNC in solitary nodular goitre. All patients that passed screening were carefully examined through clinical examination and investigation, and particular precautions were taken when FNAC or the clinical examination suggested a malignancy.

Exclusion criteria: VSA proven MNG. Proven malignancy cases.

The patient received a clinical examination, was enrolled in the trial because of a single nodular goitre, and underwent FNC (Figure 1). Minimum 2-4 aspirations were performed while supine with a cushion under the neck in the same posture. The aspirant was then moved to a glass slide, some of which were submerged in 70% alcohol, while the remainder were allowed to air dry. Papanicolaou or Wright stain is the most often used stain, and its interpretation can be classed as benign, suggestive of cancer, or malignant. Additional testing included a thyroid profile (TSH, T3, and T4), a neck ultrasound, and standard blood work. Before surgery, ENT surgeons evaluated every patient to rule out vocal cord paralysis. The workup for malignancy metastases involves a skeletal assessment and a liver function test.

Based on the FNAC testing, the patients were divided into benign (Group I), suspected malignancy (Group II), and malignant groups (Group III). All individuals exhibiting characteristics of a benign lesion on the FNAC and clinical examination were categorised under group 1; they may have adenomas or colloids. The FNAC categorised the tumour as a follicular adenoma and distinguished it from cancer was classified under group II. Patients with FNAC proved malignancy, hard swelling, Voice change, Regional lymph node involvement, Swelling fixed to the underlying structure, and Difficulty in swallowing and breathing was grouped under group III. Based on the clinical examination, fine needle aspiration cytology, and treatment such as thyroidectomy planned according to diagnosis, all 100 patients were categorised under these headings.



**Figure 1: Study design**

Statistical analysis was performed using SPSS software. The data was collected, analyzed and tabulated based on the objectives and hypothesis of the study.

**RESULTS**

In our research, eight (8%) men and 92 (92%) women out of 100 patients had solitary nodular goitres and were under 30 years old, 2 (8%) men and 22 (90%) women, aged 30 to 60, 5 (7%) men and 61 (92%) women over 60 years old, 9 (90%) women and 1 (10%) man [Figure 2, Table1].

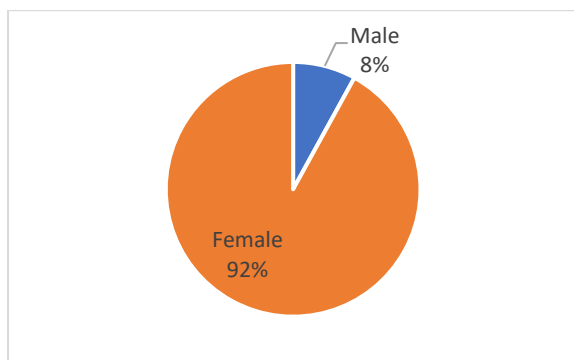
The 30 to 60-year age range is the most prevalent among men and women. Out of 100 individuals, more nodules were discovered in the right thyroid lobe in 48 (48%) cases, the left in 47 (47%) cases, and the isthmus in 5 (5%) cases [Figures 3 and 4].

**Table 1: Age-sex distribution of the study population**

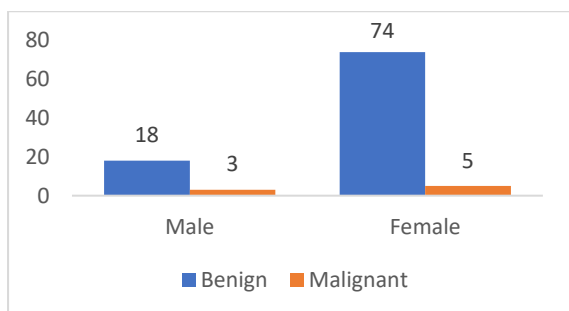
Demographic parameter	Number	Frequency
Sex		

Male	8	8%
Female	92	92%
<b>Age group</b>	<b>Male</b>	<b>Female</b>
<30	2 (8%)	22 (90%)
30 - 60	4 (7%)	61 (92%)
> 60	1 (10%)	9 (90%)

Out of 100 patients, 21 (21%) had malignant nodules, including 3 (15%) men and 18 (88%) women. One papillary carcinoma and two (66%) follicular carcinomas were found in 3 (33%) males.

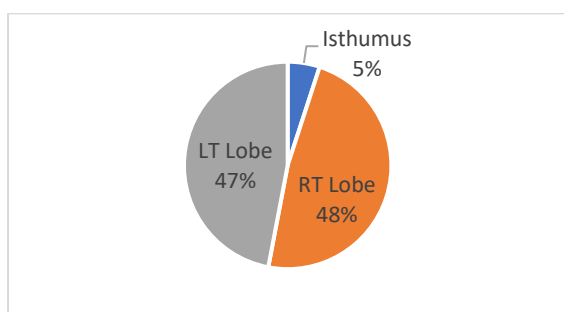


**Figure 2: Gender-wise incidence of solitary nodular goitre**



**Figure 3: Incidence of benign and malignant lesions**

Of 18 females, 13 (72%) had papillary cancer, and 5 (27%) had follicular cancer. The remaining 74 instances involved benign lesions.



**Figure 4: Location of a nodule in the thyroid gland**

While patients with benign lesions received hemithyroidectomy, all cancer patients got complete thyroid removal with lymph node dissection [Figure 5].

## DISCUSSION

The simplicity and safety of the FNAC procedure justify its use for "selected" surgery, and it is regarded

as the "gold standard" in the therapy of thyroid nodules. FNAC is the most cost-effective invasive pre-operative examination. Normally, FNAC is carried done without local anaesthetic, and the patient needs no prior preparation. According to reports, FNA is growing in popularity despite being primarily directed by palpation. Clinically significant side effects following FNA have scarcely ever been documented. The most effective and straightforward method of inquiry with the fewest complications is FNAC. In our study, the STN was aspirated, and USG and clinical examination verified this.

The age of the patients in the current research varied from 30 to 60 years. According to our findings, most patients were in their third to sixth decades of life (30-60). STN occurred more frequently in women (92%) than men (8%). This was consistent with the findings of Gupta et al., who observed that the majority of patients were female and more common in age groups over 30.<sup>[4]</sup>

Numerous studies have demonstrated the value of the FNAC treatment, its precision in the early detection of thyroid nodules, and the distinction between benign and malignant thyroid nodules. Therefore, to distinguish between the incidence of benign and malignant lesions and the histological subtypes. All the STNs in the current investigation were also exposed to FNAC analysis. Our FNAC patients were categorised into three categories: benign, probable malignancy, and malignant. According to a number of studies, most thyroid nodules found are either benign hyperplastic or malignant lesions, like the ones we found in our analysis.<sup>[11]</sup> Benign lesions were found in 79 cases out of 100, proving benign nodules are a common presentation, and this was also following the results of Rao et al.<sup>[12]</sup>

Most of the STNs were identified in the right lobe (48%) and followed by the prevalence in the left lobe (47%) and the least location in the isthmus (5%). This follows the findings of Rao et al., who reported that most of the STNs were identified in the right lobe.<sup>[12]</sup> This analysis was important as early detection produces better results for nodule identification by palpation, which also depends on the nodule's position inside the thyroid gland and the patient's neck.

STN must be surgically removed if there is any cytological suspicion or proof of cancer. All of these people who had indications of cancer and were suspected of having it underwent decisive surgical intervention. In 80% of patients, a hemithyroidectomy was performed; in the remaining

cases, those with benign lesions underwent a complete thyroidectomy. The majority of the individuals in prior STN research received hemithyroidectomy.<sup>[12]</sup> The findings of these procedures showed that follicular adenoma has the highest incidence rates compared to papillary adenoma in males. The predominance of follicular adenoma among STN cases was also reported in the observations published in a previous study.<sup>[12]</sup>

The predominance of papillary carcinoma in females was found to occur in our study. This was followed by the studies published earlier.<sup>[13,14]</sup> They also reported that papillary carcinoma is the most frequent kind of thyroid cancer, which can afflict people of any age but often manifests in the third or fourth decade of life. The patient's prognosis depends heavily on the identification of the histological subtype.<sup>[15]</sup>

## CONCLUSION

In conclusion, FNAC of thyroid nodules has evolved into one of the most effective, safe, accurate, straightforward, affordable, and time-efficient OPD procedures, almost painless, highly patient-compliant, and trustworthy instruments in the detection of thyroid pathology. While FNAC is not a replacement for traditional surgical histology, it is becoming a beneficial addition to diagnoses with the increasing incidence of malignant STN and a likely predominance in affecting females at a greater rate.

## REFERENCES

1. Walsh JP. Managing thyroid disease in general practice. *Med J Aust* 2016; 205:179–84.
2. Lawrence W Jr, Kaplan BJ. Diagnosis and management of patients with thyroid nodules. *J Surg Oncol* 2002; 80:157–70.
3. Jena A, Patnayak R, Prakash J, Sachan A, Suresh V, Lakshmi AY. Malignancy in solitary thyroid nodule: A clinico radio pathological evaluation. *Indian J Endocrinol Metab* 2015; 19:498–503.
4. Gupta M, Gupta S, Gupta VB. Correlation of fine needle aspiration cytology with histopathology in diagnosing a solitary thyroid nodule. *J Thyroid Res* 2010; 2010:379051.
5. Williams A, Christie J. Hepatic disease. *Oxford Handbook of Anaesthesia*. 2016: 129.
6. Mahar SA, Husain A, Islam N. Fine needle aspiration cytology of thyroid nodule: diagnostic accuracy and pitfalls. *J Ayub Med Coll Abbottabad* 2006; 18:26–9.
7. Sinna EA, Ezzat N. Diagnostic accuracy of fine needle aspiration cytology in thyroid lesions. *J Egypt Natl Canc Inst* 2012; 24:63–70.
8. Raniwala A, Wagh DD, Dixit-Shukla A, Shrikhande N, Padmawar M. Study and correlation of clinical, radiological, cytological, and histopathological findings in the diagnosis of thyroid swellings. *J Datta Meghe Inst Med Sci Univ* 2017; 12:138.
9. Yaprak Bayrak B, Eruyar AT. Malignancy rates for Bethesda III and IV thyroid nodules: a retrospective study of the correlation between fine-needle aspiration cytology and histopathology. *BMC endocrine disorders*. 2020; 20:1-9.
10. Pacini F, Schlumberger M, Dralle H, Elisei R, Smit JWA, Wiersinga W, et al. European consensus for managing patients with differentiated thyroid carcinoma of the follicular epithelium. *Eur J Endocrinol* 2006; 154:787–803.
11. Arora N, Scognamiglio T, Zhu B, Fahey TJ 3rd. Do benign thyroid nodules have malignant potential? An evidence-based review. *World J Surg* 2008; 32:1237–46.
12. V R, B V, M K, Durbesula P, Rao P. A study on the clinical manifestations and the incidence of benign and malignant tumors in a solitary thyroid nodule. *Int J Res Med Sci* 2013; 1:429.
13. Sengupta A, Pal R, Kar S, Zaman FA, Basu M, Pal S. Clinicopathological correlates of incidentally revealed thyroid swelling in Bihar, India. *J Pharm Bioallied Sci* 2012; 4:51–5.
14. Correat P, Chen VW. Endocrine gland cancer. *Cancer*. 1995; 75:338-52.
15. Rao R, Giriyan SS, Rangappa PK. Clinicopathological profile of papillary carcinoma of the thyroid: A 10-year experience in a tertiary care institute in North Karnataka, India. *Indian J Cancer* 2017; 54:514–8.