

## STUDY ON HUMAN EMBRYO FOR CONGENITAL ANOMALIES IN 11-13 WEEKS OF PREGNANCY IN HIGH RISK CASES

Neelu Prasad<sup>1</sup>, Sagar Dulal Sinha<sup>2</sup>, Mahesh Prasad<sup>3</sup>, Usha Singh<sup>4</sup>, Subhodh Kumar<sup>5</sup>

Received : 10/01/2023

Received in revised form : 09/02/2023

Accepted : 25/02/2023

**Keywords:**

Anencephaly, down syndrome, ultrasound, cystic hygroma, Nuchal translucency.

Corresponding Author:

**Dr. Mahesh Prasad**

Email: drmahesh25d@gmail.com

DOI: 10.47009/jamp.2023.5.2.71

Source of Support: Nil,

Conflict of Interest: Nondeclared

*Int J Acad Med Pharm*

2023; 5 (2); 346-349



<sup>1</sup>Assistant Professor, Department of Anatomy, Nalanda Medical College, Patna, India.

<sup>2</sup>Senior Resident, Department of Obstetrics & Gynaecology, Nalanda Medical College, Patna, India.

<sup>3</sup>Associate Professor, Department of Orthopaedics, Patna Medical College, Patna, India.

<sup>4</sup>Radiation Oncologist Mahavir Cancer Sansthan Phulawari Sharif, Patna, India.

<sup>5</sup>Associate Professor, Department of Anatomy, Nalanda Medical College, Patna, India.

### Abstract

**Background:** The ideal time to determine gestational age, quantify nuchal translucency thickness, and perhaps acquire a thorough anatomic assessment is between 11 and 13 weeks of gestation. **Objectives:** To determine the benefit of undertaking a thorough evaluation of the human embryo for both structural defects as part of a standard ultrasound scan between 11 and 13 weeks. **Materials and Methods:** It was a one-year prospective study conducted in the Department of Gynecology at Nalanda Medical College under (AKU), Patna and AasthaLok Hospital, Patna. Among 300 high-risk women who attended the antenatal clinic at OPD from April 2021 to March 2022. Out of the 300 antenatal mothers who had an ultrasonogram, 16 patients were excluded from the study due to the fact that 22 patients were lost to follow-up and were not seen during the second trimester, and 3 of them had findings that suggested missed abortions at the time of the 11–13-week scan, making the sample size for the study total 275. Analysis was conducted using SPSS 22.0. **Result:** According to Table 1, the majority of the prenatal moms in the study group (52.8%) were between the ages of 21 and 25. About 5 of the abnormalities found (or 55.6%) were between the ages of 21 and 25. In the study population, there were 9 embryo with anomalies (3.2%); all were found by ultrasound screening. Of the total 9 anomalous fetuses, 3 (1.1%) were found at the 11–13 week scan, and the other 6 (3.2%) were found at the second trimester follow-up scan. The majority of anomalies found in the first trimester were cranial, and all of them were aborted (TOP). There are just 3 abnormalities (2 anencephaly and 1 cystic hygroma). **Conclusion:** The parents have the choice of an earlier, safer, and psychologically less traumatic termination of the pregnancy if the significant defects are discovered at this early gestation (11–13 wks). The regular 18–22 week anomaly scan might be supplemented with the effective ultrasound screening at 11–14 weeks to screen for embryo abnormalities

## INTRODUCTION

Every expectant mother hopes for a child who is normal and healthy. Major malformations in newborns occur in roughly 3-5% of cases. The use of an ultrasonogram is crucial for prenatal screening and diagnosis. According to the Radius Trial, the standard anomaly scan was performed between 18 and 22 weeks, but now the emphasis for screening for embryo abnormalities has been shifted to between 11 and 14 weeks in the first trimester.<sup>[1,2,3]</sup> Until recently, only high-risk and carefully chosen populations have been subjected to attempts to

detect embryo abnormalities during the first trimester. Evidence supports the value of routine early ultrasonography for detecting embryo abnormalities in low-risk pregnancies. The ideal time to determine gestational age, quantify nuchal translucency thickness, and perhaps obtain a thorough anatomical image is between 11 and 13 weeks of gestation.<sup>4,5</sup> A more thorough examination of the embryo anatomy is performed when mandated by the patients' history of an abnormal finding on a screening examination.

## MATERIALS AND METHODS

It was a one-year prospective study conducted in the Department of Gynecology at Nalanda Medical College, Patna, AasthaLok Hospital, Patna. Among 300 high risk mothers who attended the antenatal clinic at OPD between April 2021 and March 2022.

### Inclusion Criteria

- Pregnant women at 11-13.6 weeks GA.
- H/o previous anomalies.
- H/o anomalies in the family
- H/o diabetes H/o Anticonvulsants medication
- H/o. radiation exposure

### Exclusion Criteria

- GA <11 Weeks
- GA >14 Weeks
- Multiple gestation

### Methodology

A skilled radiologist used a 2 to 6MHZ curvilinear transducer and a VITUS ultrasound system to do trans-abdominal ultrasound screening. 6 Transvaginal scans were always carried out whenever the transabdominal scan's ability to visualize the embryo's anatomy was less than ideal or when a structural anomaly was detected. All 300 pregnant women underwent ultrasound screening between 11 and 13 weeks of pregnancy. A confirmation scan was performed at 18–22 weeks for individuals who had normal scans. Crown rump

length was measured, and embryo viability was evaluated. In addition to evaluating the anatomy, the Embryo Medicine Foundation produced criteria for measuring nuchal translucency in fetuses with CRL between 45mm and 84mm at 11 to 13.6 weeks gestation. The NT measuring cutoff value was set at > 3 mm. The NT measurement was deemed abnormal when it exceeded 3 mm, and additional confirmatory testing was done. The patient was given the option to choose between the first trimester serum indicators (free hCG, PAPP-A), chorionic villous sample, amniocentesis, triple screening, or quadruple screening. Prior to their ultrasound examination, women had thorough counseling, and signed informed consent was obtained. Patients received advice about whether to end or continue their pregnancies based on the anomalies found. We monitored every patient right up to birth.

### Statistical Analysis

Data so obtained were subjected to statistical analysis. Results were evaluated for the best modality through which benign and malignant lesions can be differentiated. Data analysis was done by SPSS software ® version 22.0. Descriptive statistical analysis, which included frequency and percentages, was used to characterize the data. Chi-square test was used for association between factors and  $p < 0.05$  was considered statistically significant.

## RESULTS

**Table 1: Age wise distribution with anomalies of study participants**

Agegroup	Normal	Anomalies	Total
<20yrs	49 17.3%	1 0.4%	50 17.6%
21-25yrs.	145 51.1%	5 51.1%	150 52.8%
26-30yrs	62 21.8%	3 1.1%	65 22.9%
>30yrs	19 6.7%	0 .	19 6.7%
Total	275 96.8%	9 3.2%	284 100%

According to Table 1, the majority of the prenatal moms in the study group (52.8%) were between the ages of 21 and 25. About 5 of the abnormalities found (or 55.6%) were between the ages of 21 and 25. Not significant ( $P=0.729$ ). Out of the 300 antenatal mothers who had an ultrasonogram, 16 patients were excluded from the study because 19 patients were lost to follow-up and were not seen during the second trimester. Three of these patients also had findings that suggested missed abortions at the time of the 11–13-week scan, making the final sample size of 278.

**Table 2: Anomalies detected between 11-13 weeks**

Study group	Frequency (n)	Percentage
Normal	275	96.8%
Anomalies	3	3.2%
Total	278	100%

According to Table 2, there were 9 embryos with anomalies in the study population (3.2%) that were all found using ultrasound screening. Of the total 9 anomalous fetuses, 3 (1.1%) were found during the 11–13 week scan, and the other 6 (3.2%) were found after the second trimester follow-up scan.

**Table 3: Types of Anomalies detected between 11-13 weeks**

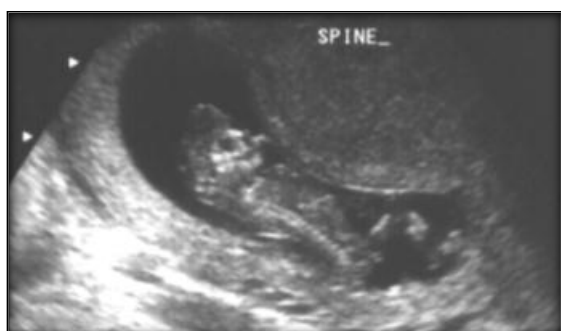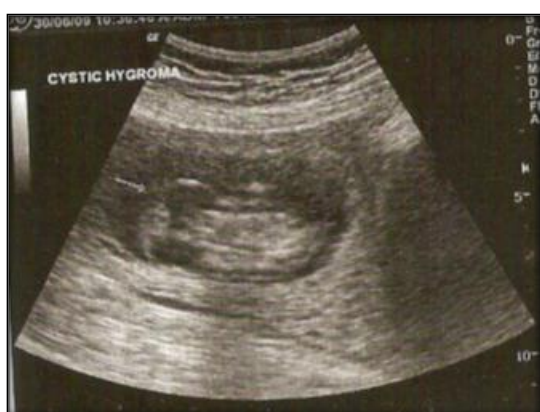
S. No.	Anomalies	GA(wks)	Outcome
1.	Cystichygroma	13	TOP
2.	Anencephaly	13.2	TOP
3.	Anencephaly	12.2	TOP

As per table 3 Cranial abnormalities was the most common abnormality detected in the first trimester and all of them were terminated (TOP). Only 3 anomalies seen (2 anencephaly and 1 cystic hygroma).

**Table 4: Types of Anomalies detected between 11-13 weeks**

Variable Name	Chi-Square	P Value
Family H/O. Of Anomalies	5.983	0.014
H/O Drug Intake	10.946	0.001

As per table 4 it was found that family H/O anomalies and positive history of drug intake (anticonvulsants and other teratogenic drugs) had a very high risk for presence of anomalies. Hence first trimester ultrasound is useful in early diagnosis of structural anomalies.

**Figure 1 (a): First Trimester scan anomalies- Anencephaly****Figure 1 (b): First Trimester scan anomalies- Cystic Hygroma**

by inadequate training and insufficient examination time. High detection rates of roughly 50% and 70%, respectively, were reported by Soukaet al.<sup>[11]</sup> and Chen et al.<sup>[12]</sup> This high detection rate of structural abnormalities at 11-13.6 wks of gestation reflects the fact that experienced obstetrician or radiologist has a major role and good training is mandatory with high resolution ultrasound machine.

Routine first trimester scanning will have significant effects on second trimester scans. Nuchal translucency thickness, which is utilized for the first trimester scan (11–13 weeks), detects the majority of chromosomal abnormalities, and is therefore used to test for Down's syndrome and other abnormalities. When a screen positive result is obtained, a confirmative test such chorionic villous sample or amniocentesis is performed.<sup>[13,14]</sup>

Early amniocentesis is no longer ideal at 11 to 13 weeks of gestation because of its higher correlation with embryo loss, embryo club foot, and procedure failure. Chorionic villous sampling performed at 11 to 13 weeks of gestation aids in the earlier detection of aneuploidy. The results of cell culture and karyotype analysis used to take two to three weeks. However, the FISH method now makes it possible to receive the karyotype results in less than 48 hours. Therefore, early fetal termination is possible when an embryo is abnormal. When an anomaly is identified, parents might choose to have their child terminated. Prenatal diagnosis not only permits abortion but also has significant effects on prenatal and postpartum care, including the treatment of diaphragmatic hernia in utero and other embryotherapies.<sup>[15]</sup>

## DISCUSSION

In this study, there were roughly 3.2% of serious embryo abnormalities, which is within the range noted in the literature.<sup>[7,8]</sup> 33.3% of serious structural abnormalities were found in low risk pregnant women in this study after a careful analysis of the embryo's architecture between 11 and 13.6 weeks of pregnancy. This outcome is consistent with those of other studies that have been reported. About 38% of structural malformations were reported to be detected in the first trimester by Carvalho et al.<sup>[9]</sup> According to Taipale et al.<sup>[10]</sup> a low detection rate of roughly 18% in the first trimester was mostly caused

## CONCLUSION

The parents have the choice of an earlier, safer, and psychologically less traumatic termination of the pregnancy if the significant defects are discovered at this early gestation (11–13 wks). The regular 18–22 week anomaly scan might be supplemented with the effective ultrasound check at 11–14 weeks to look for embryo abnormalities. Therefore, it is imperative

to make first trimester ultrasound (11–13 weeks) mandatory for the diagnosis of multiple pregnancies as well as aberrant pregnancies such as missed abortion, molar pregnancy, and ectopic pregnancy in addition to the detection of serious embryo defects.

**Source of Funding** None

**Conflict of Interest** None declared.

## REFERENCES

1. Whitlow BJ, Economides DL. The optimal gestational age to examine fetal anatomy and measure nuchal translucency in the first trimester. *Ultrasound ObstetGynecol* 2018;11:258-61
2. Green JJ, Hobbins JC: Abdominal ultrasound examination of the first trimester fetus. *AJOG* 2018;159:165-175.
3. RottemS.Bronshtein M: Transvaginalsonographic diagnosis of congenital anomalies between 9 weeks and 16 weeks, menstrual age *J. Clin. Ultrasound* 2014;18:307-314
4. Quashie C, Weiner S, Bolognese R. Efficacy of first trimester transvaginalsonography in detecting normal fetal development *Am.J. Prenatal* 2012;9:209-213
5. Braithwaite JM, Armstrong MA, Economides: Assessment of fetal anomaly at 12 to 13 wks of gestational by transabdominal and transvaginalsonography. *BJOG* 2016;130:82-85.
6. Chitty L, Pandya P: ultrasound screening for fetalabnormalities in the first trimester. *PrenatDiag* 2017;17:1269- 1281.
7. Dhapate S.S, Shingare A. K, Sanja Desai. Early diagnosis of Aneuploidy –Value of ultrasound in Rural Areas. *J of Anatomical society of India.* 2009; 56(2)4-7
8. Balkumar K. Major fetal anomalies among singleton pregnancies of Kara la. *Ultrasound international* .2015;5(4) 198-207.
9. Carvalho MHB, Brizot ML, Lopes LM, Chiba EH. Detection of fetal structural abnormalities at the 11-14 weeks ultrasound scan. *Ultrasound obstetGynecol* 2012;22:1-4.
10. Taipale P, Ammala M, Solonen R, Hiilesmaa V. Two –stage ultrasonography in screening for fetal anomalies at 13-14 and 18-22 weeks of gestation. *ActaobstetGynecolScand* 2018; 83:141-6.
11. Souka AP, Krampf E, Bakalis, et al. Outcome of pregnancy in chromosomally normal fetuses with increased nuchal translucency in the first trimester. *Ultrasound Obstet. Gynecol* 2019;128:9-17.
12. Chen M,Lam YH, Lee CP, Tang MHY. Ultrasound screening of fetal structural abnormalities at 12 to 14 wks in Honk Kong. *PrenatDiagn* 2014;24:92-7.
13. Hernadi L, Torocsik M. Screening for fetal anomalies in the 12th week of pregnancy by transvaginalsonography in an unselected population. *PrenatDiagn* 2017; 17:753:9.
14. Brown DL, Emerson DS, Shulamn LP, Carson SA. Sonographic diagnosis of omphalocele during the 10th weeks of gestation *AM J Radiol* 2019; 153:825-6.
15. Bronshtein M, Amit A, Achiron R, Noy I, Blumenfeld Z. The early prenatal sonographic diagnosis of renal agenesis ;techniques and possible pitfalls. *PrenatDiagn* 2014; 14:219-7.