

ROLE OF TIRADS IN THE CHARACTERISATION OF THYROID NODULES IN CORRELATION WITH FNAC

Vigneshwar Adhithiya¹, Ashwin Kumar A², C.Saravanan³, Saravanan K⁴

Received : 22/01/2023
Received in revised form : 26/02/2023
Accepted : 09/03/2023

Keywords:

Thyroid gland, Nodules, Ultrasonography, FNAC, BETHESDA score, Tumours, TI-RADS.

Corresponding Author:

Dr. Saravanan K.
Email: dr.saravana.k@gmail.com

DOI: 10.47009/jamp.2023.5.2.137

Source of Support: Nil,
Conflict of Interest: None declared

Int J Acad Med Pharm
2023; 5 (2); 653-658



¹Assistant Professor, Department of Radiodiagnosis, Melmaruvathur Adhiparasakthi Institute of Medical Sciences and Research, Tamilnadu, India

²Assistant Professor, Barnard Institute of Radiology, Madras Medical College, Tamilnadu, India

³Assistant Professor, Department of Radiodiagnosis, Government Thoothukudi Medical College, Tamilnadu, India

⁴Assistant Professor, Department of Radiodiagnosis, Melmaruvathur Adhiparasakthi Institute of Medical Sciences and Research, Tamilnadu, India

Abstract

Background: Thyroid nodules are a common problem in clinical practice, caused by congenital anomalies, inflammatory pathologies, and tumours. The study aims to determine the diagnostic accuracy of thyroid ultrasound in differentiating benign and malignant thyroid nodules using Fine Needle Aspiration Cytology (FNAC), a reference standard. **Materials and Methods:** This hospital-based cross-sectional study was conducted at the department of Radiodiagnosis, MAPIMS, Melmaruvathur, Tamil Nadu for 18 months, from July 2021 to December 2022. All patients referred for thyroid ultrasound imaging with a clinically suspected thyroid nodule and incidentally detected thyroid nodule were included. The study included one hundred twenty-one patients who fulfilled the inclusion criteria. **Result:** The majority (85%) of the participants were females, aged 30-40 (29%), with a mean age of 38 years and a standard deviation of 13.34. Hypothyroidism was the most common symptom found in 40%. The majority of the nodules are of mixed composition (70%), have Hyper or Iso Echogenicity (64%), are Wider than tall in shape (97%), have smooth margins (94%), and have no echogenic foci (95%). Almost 48% of thyroid nodules were classified as Grade 2 by TIRADS, 35% as Grade 3, and 17% as Grade 4 or 5. The sensitivity and specificity of the TIRADS Score in predicting malignancy was 93%. The negative predictive value of TIRADS to detect those scores less than or equal to three was 99%. **Conclusion:** In conclusion, Thyroid high-resolution ultrasonography based on TIRADS is an accurate technique to assess a thyroid nodule's location, type, morphology and malignant risk.

INTRODUCTION

The thyroid gland is a major endocrine gland affected by various congenital anomalies, inflammatory pathologies and tumours, both benign and malignant, which can present clinically as thyroid nodules. These thyroid nodules are a commonly encountered problem in day-to-day clinical practice. Ultrasonography is a valuable, non-invasive, non-ionizing, relatively cheap and widely available imaging tool for diagnosing clinically suspected nodules.^[1] High-resolution ultrasound is very suitable for imaging superficial structures like the thyroid gland with exquisite detail. Hence clinical suspicion, along with ultrasound features, can categorize the thyroid nodules into high risk or low risk to a great extent. Cost-effectiveness is essential in a developing

country like India, where the patient load and workforce available in health care are proportionally low. Hence ultrasonography renders a very important role in the evaluation of thyroid nodules. Many studies have suggested that a Thyroid Imaging Reporting and Data System (TIRADS) with suitable modifications derived from the widely used Breast Imaging Reporting and Data System (BIRADS) has revealed a handful of significant parameters for the quantitative and qualitative analysis of the ultrasound features.^[1] This system was proposed initially by Horvath et al., who summarized the different ultrasound characteristics of thyroid nodules into TIRADS classes based on their malignant potential.^[1] Thus, TIRADS is a risk stratification system for classifying thyroid lesions based on ultrasonography. US thyroid gland characteristics strongly correlated with malignancy

include intra-nodular vascularity, micro-calcification, a taller-than-wider pattern, hypoechoogenicity and speculated margins.^[2]

All the thyroid nodules on ultrasound are characterized according to the internal component (solid, mixed or cystic), the margins, shape, echogenicity and evidence of echogenic foci within.^[3] TIRADS scoring system classifies thyroid nodules into six categories based on the above-mentioned sonographic features and helps differentiate benign from malignant lesions. Nevertheless, ultrasound has limitations, such as differences in the resolution of the equipment, observer variations and overlapping of findings. TIRADS classification is used to minimize these limitations.^[3]

This study was conducted to investigate the diagnostic reliability of prospectively the daily use of the TIRADS system in differentiating between benign and malignant lesions, taking Fine Needle Aspiration Cytology (FNAC) findings as reference standards. FNAC was used as a reference standard for evaluating thyroid nodules. Still, its post-operative histopathological results were mostly malignant or probably malignant, leading to bias in the TIRADS scoring system. FNAC is now the "gold standard" preoperative test for diagnosing thyroid cancer.^[2] Hence FNAC is used as a reference standard.

Aim

The study aims to determine the diagnostic accuracy of thyroid ultrasound in differentiating benign and malignant thyroid nodules using Fine Needle Aspiration Cytology (FNAC), a reference standard.

MATERIALS AND METHODS

This hospital-based cross-sectional study was conducted at the department of Radiodiagnosis, MAPIMS, Melmaruvathur, Tamil Nadu for 18 months, from July 2021 to December 2022.

All patients referred for thyroid ultrasound imaging with a clinically suspected thyroid nodule and incidentally detected thyroid nodule were included. Patients classified under TIRADS 1 - Normal thyroid gland, patients already diagnosed with thyroid malignancy – TIRADS 6, patients below 12 years of age, patients who don't consent to fine needle aspiration cytology, and patients with bleeding diathesis were excluded.

The study included one hundred twenty-one patients who fulfilled the inclusion criteria. After obtaining informed consent in the patient's language, any patient queries were cleared, and information was collected using questionnaires. After receiving the history, the patient was subjected to ultrasound-thyroid followed by fine needle aspiration cytology. An ultrasonography study was performed with high resolution, 7.5 – 12 MHz, near the array transducer. Initially, imaging was done to localize the nodule, and then the nodule was categorized under ACR-TIRADS classification based on specific sonographic features. The definition for each TIRADS category is mentioned in [Table 1].

Table 1: TIRADS category

TI-RADS	DEFINITION
1	Normal
2	Benign
3	Probably benign
4	Low suspicion
5	Probably malignant
6	Biopsy proven malignancy

The data were entered in Excel and analysed using R version 3.4.1 and Statistical Package for Social Sciences (SPSS) version 17. Data were summarized as frequency, percentage, or mean and Standard deviation as appropriate. Wilcoxon signed-rank test was performed in SPSS. The Kappa value was calculated to estimate the agreement between the classification of Thyroid nodules by USG and FNAC. As the classification was as ordered categories, weighted kappa with 95% CI was calculated using the package "psy", and kappa values are interpreted as follows.

RESULTS

A total of 121 participants were included in the study. The majority (85%) of the participants were females, aged 30-40 (29%), with a mean age of 38 years and a standard deviation of 13.34. The minimum age was 13 years, and the maximum was 75 years.

Almost one-third of participants were incidentally discovered as asymptomatic during a routine checkup. Hypothyroidism was the most common symptom found in 40%, followed by neck swelling (25%), Hyperthyroidism (6%) and change in voice (5%) [Table 2].

Table 2: Demographic data of the study

		Frequency	Percentage
Gender	Male	18	14.9
	Female	103	85.1
Age group	12-20	10	8.26
	20-30	31	25.62
	30-40	35	28.93
	40-50	23	19.01
	>50	22	18.18
Clinical features	None	30	24.79
	Hypothyroidism	48	39.67
	Hyperthyroidism	7	5.79

	Neck swelling	30	24.79
	Change in voice	6	4.96

The majority of the nodules are of mixed composition (70%), have Hyper or Iso Echogenicity (64%), are Wider than tall in shape (97%), have smooth margins (94%), and have no echogenic foci (95%). Almost 48% of thyroid nodules were classified as Grade 2 by TIRADS, 35% as Grade 3, and 17% as Grade 4 or 5. However, 62% of nodules were classified as Grade 2 by Bethesda classification, 26% as Grade 3 and 12% as Grade 4 or 5 [Table 3].

Table 3: Distribution of USG features and classifications

		Frequency	Percentage	
USG Features with TIRADS scoring	Composition	Mixed Cystic and Solid (1)	85	70.2
		Solid or almost completely solid (2)	36	29.8
	Echogenicity	Hyper or iso echoic (1)	77	63.64
		Hypoechoic (2)	36	29.75
		Very Hypoechoic (3)	8	6.61
	Shape	Wider than tall (0)	117	96.69
		Taller than wide (3)	4	3.31
	Margin	Smooth (0)	114	94.21
		Ill-defined (0)	5	4.13
		Lobulated or Irregular (2)	2	1.65
	Echogenic Foci	None (0)	115	95.04
		Macrocalcifications (1)	4	3.31
		Peripheral or Rim calcifications (2)	1	0.83
Punctate echogenic foci (3)		1	0.83	
Classification	TIRADS	2	58	47.93
		3	42	34.71
		4	16	13.22
		5	5	4.13
		BETHESDA	2	75
	3		31	25.62
	4		6	4.96
	5		9	7.44

Wilcoxon Signed rank test reveals that both scoring systems were concordant in 92 nodules' classification of thyroid nodules. In six nodules, the BETHESDA scoring system gave a higher classification in TIRADS, while in 23, BETHESDA gave a lower score than TIRADS [Table 4].

Table 4: Cross tabulation of classification of thyroid nodules by TIRADS and BETHESDA Score

TIRADS Score		BETHESDA Score			
		2	3	4	5
2	Actual	57	1	0	0
	Expected	36	14.9	2.9	4.3
3	Actual	16	25	1	0
	Expected	26	10.8	2.1	3.1
4	Actual	2	5	5	4
	Expected	9.9	4.1	0.8	1.2
5	Actual	0	0	0	5
	Expected	3.1	1.3	0.2	0.4

Agreement analysis (Kappa) showed that there was a moderate level of agreement (0.6) between the classification by BETHESDA and TIRADS Score, which was significant (p-value 0.0001) [Table 5].

Table 5: Agreement between the classification of thyroid nodules by BETHESDA and TIRADS

	Value	Asymp Std. Error	Approx T	Approx. Sig
A measure of Agreement (Kappa)	0.603	0.060	9.716	0.0001
Weighted Kappa	0.81	95% CI: 0.697 to 0.878		

Weighted kappa analysis shows strong agreement (0.81) with a 95% CI ranging from 0.697 to 0.878. The scores above three in both classifications were aggregated for diagnostic accuracy calculation, indicating a greater probability of malignancy. In comparison, the rest have a greater probability of being benign [Table 6].

Table 6: 2 X 2 table for diagnostic statistics calculation

		BETHESDA		TOTAL
		Score >3	Score <=3	
TIRADS	Score >3	14	7	21
	Score <=3	1	99	100
Total		15	106	121

The sensitivity and specificity of the TIRADS Score in predicting malignancy was 93%. The negative predictive value of TIRADS to detect those scores less than or equal to three was 99% [Table 7].

Table 7: Diagnostic statistics for scores more than three in both classifications

Statistic	Value	95% CI
Sensitivity	93.33%	68.05 - 99.83%
Specificity	93.40%	86.87 - 97.3%
Positive Likelihood Ratio	14.13	6.82- 29.29
Negative Likelihood Ratio	0.07	0.01 - 0.47
Positive Predictive Value	66.67%	49.11 - 80.56%
Negative Predictive Value	99%	93.71 - 99.85%
Accuracy	93.39%	87.39 - 97.1%

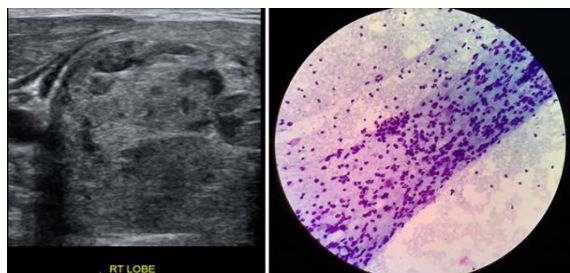


Figure 1: Axial ultrasound image and FNAC specimen of the thyroid nodule. USG shows a solitary nodule in the right lobe. Based on TIRADS, the nodule is mixed solid and cystic (1), iso Echoic (1), wider than taller (0), has smooth margin (0) and no echogenic foci (0)

TIRADS Category: 2

FNAC specimen of the same nodule shows a benign lesion: Bethesda II category.

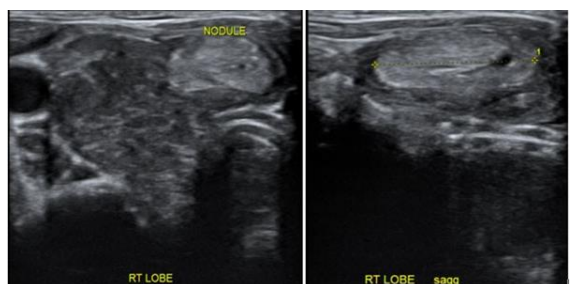


Figure 2: Axial and longitudinal ultrasound images of the thyroid shows a solitary nodule in the right lobe. Based on TIRADS, the nodule is almost completely solid (2), hyperechoic (1), wider than taller (0), has smooth margin (0) and no echogenic foci (0). TIRADS Category: 3

FNAC report of the nodule showed Bethesda III category.

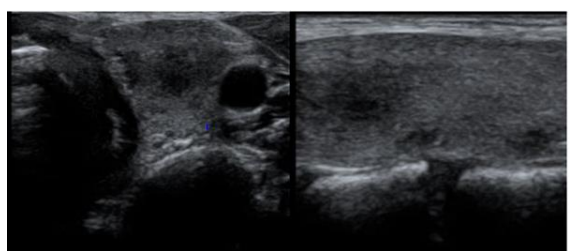


Figure 3a: Axial and longitudinal ultrasound images of the thyroid shows a solitary nodule in the left lobe. Based on TIRADS, the nodule is almost completely solid (2), hypoechoic (2), wider than taller (0), has smooth margin (0) and no echogenic foci (0).

TIRADS Category: 4.

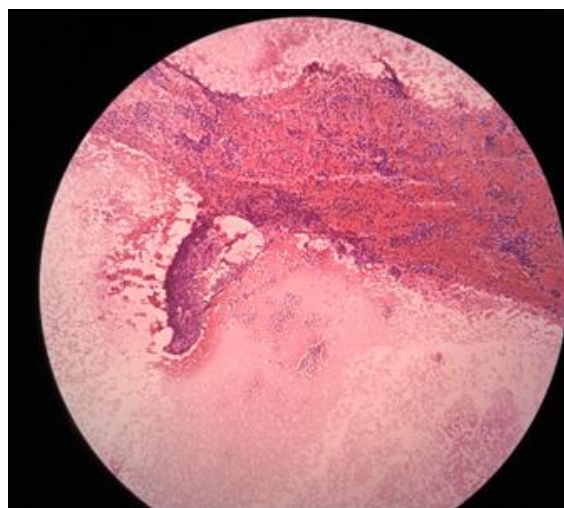


Figure 3b: FNAC specimen of the nodule shows follicular neoplasm - Bethesda IV category.

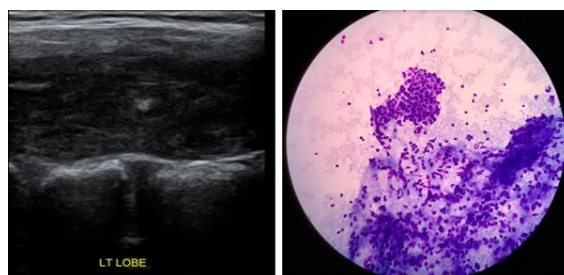


Figure 4: Sagittal ultrasound image of the thyroid and FNAC specimen: USG shows a solitary nodule in the left lobe. Based on TIRADS, the nodule is almost completely solid (2), very hypoechoic (3), taller than wider (3), has smooth margin (1) and presence of echogenic foci (3).

TIRADS Category: 5.

FNAC report of the nodule is suggestive of suspicious for malignancy: Bethesda V category.

DISCUSSION

Ultrasonography is a non-invasive, easily available technique that provides excellent information about the thyroid gland and its pathologies. This study aims to evaluate the diagnostic accuracy of TIRADS ultrasound scoring in differentiating benign from malignant thyroid nodules based on certain sonographic features of the nodule.

This study had a sample size of 121 participants, among which females (85.1%) had more thyroid nodules than males (14.9%). This observation was similar to the study done by Joanna G et al. in which the female patients (87%) were more in the sample size.⁴ Similar findings were observed in the study by Azab EA et al., in which there were more female patients (82.5%) with thyroid nodules.⁵ The most common age group with thyroid nodules in this study were from 30 to 40 years (28.9%), followed by the 20 to 30 age group (25.6%), with a mean age of 38 years. This observation was similar to the Albair et al. study, which showed the mean age of patients with thyroid nodules as 38 years.⁶ Sermin TU et al. showed the mean age in patients with thyroid nodules to be 48 years.⁷

39.6% of patients in the sample presented with hypothyroidism, followed by patients who came for a routine checkup and were incidentally found to have thyroid nodules (24.7%). Regarding the nodule's characteristics, composition-wise, mixed cystic and solid nodules were the most common (70.2%). These nodules are categorised under TIRADS 2 and TIRADS 3. [Figure 1,2] This finding was similar to the Albair et al. study, which showed 77% of the nodules to be solid and mixed cystic in composition.⁶ Echogenicity-wise, iso-to-hyperechoic nodules were more common (63.6%), followed by thyroid nodules with hypoechogenicity (29.7%). Albair et al. showed 46.6% of the nodules to be iso-hyperechoic among the thyroid nodules in their sample size.⁶ Most of the markedly hypoechoic nodules were found to have a TIRADS score 4 and 5, [Figure 3a,3b,4] thus having a higher risk of malignancy.

Regarding the shape of the nodule, in this study, the most common shape of the thyroid nodule is wider-than-taller, constituting 96.6%. Taller than wider shaped nodules were very less, but all those nodules had a corresponding score of TIRADS 5, which points more towards malignancy. Margin-wise, nodules with smooth margins were the most common (94.2%). Nodules with lobulated margins were found to have a higher TIRADS score pointing towards malignancy. About 95.1% of thyroid nodules showed no evidence of echogenic foci. In nodules with echogenic foci, macro-calcifications were predominant (3.3%). This observation was also found in the Albair et al. study in which macro-calcifications were predominant in the presence of echogenic foci (23.1%).⁶

Upon applying TIRADS scoring, most of the nodules corresponded to a score of TIRADS 2 (47.9%), followed by TIRADS 3 (34.7%). Only 4.1% of patients had thyroid nodules corresponding to TIRADS 5. This finding was similar to the study by Periakaruppan et al, in which the nodules with TIRADS 2 and 3 accounted for 92% of the sample size. 93 % of the sample corresponded to BETHESDA 1 and 2.⁸

In our study, following FNAC results, according to the BETHESDA system, most patients

corresponded to a BETHESDA 2 (61.9%) score, followed by a BETHESDA score 3 (25.6%). Agreement analysis (Kappa) showed that significant association between the classification by BETHESDA and TIRADS Score with p-value=0.0001. Periakaruppan et al. showed a significant association between TIRADS and BETHESDA classification with a p-value <0.001.⁸ On correlating TIRADS with BETHESDA scoring, the sensitivity of TIRADS detecting the malignant risk of thyroid nodules is 93.3%, and the specificity is 93.4%. Ha, et al. reported a sensitivity of 95.5 % higher than our study.⁹ Sensitivity of TIRADS was even higher in Yoon et al., which showed 97.4%.¹⁰ Keeping FNAC as a reference standard, TIRADS scoring had a positive predictive value (PPV) of 66.6% and a negative predictive value (NPV) of 99%. Horvath et al. showed a PPV of 49%, which was lower than the present study.¹¹ In this study, the diagnostic accuracy of TIRADS scoring classification in differentiating malignant from benign thyroid nodules, in this study is 93.3%. The diagnostic accuracy of TIRADS was 69% in Ha et al. study, which is also low compared to this study.⁹ Similarly, this finding was higher than Russ et al., which showed an accuracy of 62%.¹¹

CONCLUSION

In conclusion, Thyroid high-resolution ultrasonography based on TIRADS is an accurate technique to assess a thyroid nodule's location, type, morphology and malignant risk. By following the TIRADS lexicon, the following can be achieved.

Objectivity in thyroid ultrasound reporting can be achieved, which helps in better clinical decision-making. Malignant lesions can be identified accurately, and FNAC/biopsy can be warranted. Benign thyroid lesions can be identified with high sensitivity and specificity, which helps us prevent avoidable FNACs.

Limitations

In this study, a few thyroid nodules corresponding to a TIRADS score of 3 were given as a TIRADS score of 4 and vice versa. This error may be due to inter-observer variation, as a single radiologist didn't review all the sample cases. Inter-observer variation may have occurred while differentiating hypoechoic nodules from markedly hypoechoic nodules, which depends upon the radiologists' experience.

REFERENCES

1. Horvath E, Majlis S, Rossi R, Franco C, Niedmann JP, Castro A, et al. An ultrasonogram reporting system for thyroid nodules stratifying cancer risk for clinical management. *J Clin Endocrinol Metab* 2009; 94:1748–51.
2. Kim KM, Park JB, Kang SJ, Bae KS. Ultrasonographic guideline for thyroid nodules cytology: single institute experience. *J Korean Surg Soc* 2013; 84:73–9.
3. Moifo B, Takoeta EO, Tambe J, Blanc F, Fotsin JG. Reliability of thyroid imaging reporting and data system (TI-

- RADS) classification in differentiating benign from malignant thyroid nodules. *Open J Radiol* 2013; 03:103–7.
4. Dy JG, Kasala R, Yao C, Ongoco R, Mojica DJ. Thyroid Imaging Reporting and Data System (TIRADS) in stratifying risk of thyroid malignancy at The Medical City. *J ASEAN Fed Endocr Soc* 2017; 32:108–16.
 5. Azab EA, Abdelrahman AS, Ibrahim MEA. A practical trial to use Thyroid Imaging Reporting and Data System (TIRADS) in differentiation between benign and malignant thyroid nodules. *Egypt J Radiol Nucl Med* 2019; 50.
 6. Albair Ashamalla G, EL-Adalany MA. Risk for malignancy of thyroid nodules: Comparative study between TIRADS and US-based classification system. *Egypt J Radiol Nucl Med* 2016; 47:1373–84.
 7. Sermin TU, Furkan K, Mehmet K. Evaluation of ultrasonographic thyroid imaging reporting and data system and color doppler imaging findings in thyroid nodules. *Int Med J* 2020; 9:343-6.
 8. Periakaruppan G, Seshadri KG, Vignesh Krishna GM, Mandava R, Sai VPM, Rajendiran S. Correlation between ultrasound-based TIRADS and Bethesda system for reporting thyroid-cytopathology: 2-year experience at a tertiary care centre in India. *Indian J Endocrinol Metab* 2018; 22:651–5.
 9. Ha EJ, Moon W-J, Na DG, Lee YH, Choi N, Kim SJ, et al. A multicenter prospective validation study for the Korean Thyroid Imaging Reporting and Data System in patients with thyroid nodules. *Korean J Radiol* 2016; 17:811–21.
 10. Yoon JH, Lee HS, Kim E-K, Moon HJ, Kwak JY. Malignancy risk stratification of thyroid nodules: Comparison between the Thyroid Imaging Reporting and Data System and the 2014 American Thyroid Association management guidelines. *Radiology* 2016; 278:917–24.
 11. Russ G, Royer B, Bigorgne C, Rouxel A, Bienvenu-Perrard M, Leenhardt L. Prospective evaluation of thyroid imaging reporting and data system on 4550 nodules with and without elastography. *Eur J Endocrinol* 2013; 168:649–55.