

INSTITUTIONAL ANALYSIS OF BRAIN METASTASES IN CARCINOMA BREAST

Selvalakshmi S¹, Senthilkumaran M², Durga Prasad R², Ragavendra A⁴, Ananthi P³

Received : 19/01/2023
Received in revised form : 25/02/2023
Accepted : 07/03/2023

Keywords:

Breast cancer, HER2 positive, triple negative, brain metastasis, chemotherapy, radiotherapy, survival, clinical staging.

Corresponding Author:

Dr. Ragavendra A,

Email: drragavendra84@gmail.com

DOI: 10.47009/jamp.2023.5.2.136

Source of Support: Nil,

Conflict of Interest: None declared

Int J Acad Med Pharm
2023; 5 (2); 647-652



¹Assistant Professor, Department of Radiation Oncology, Government Stanley Medical College Hospital, Tamilnadu, India

²Assistant Professor, Department of Radiation Oncology, Rajiv Gandhi Government General Hospital, Tamilnadu, India

³Professor, Department of Radiation Oncology, Government Stanley Medical College Hospital, Tamilnadu, India

⁴Assistant Professor, Department of Radiation Oncology, Government Coimbatore Medical College, Tamilnadu, India

Abstract

Background: Carcinoma breast is the second most common cause of brain metastasis after lung cancer. The present study aimed to analyze various clinicopathological parameters associated with brain metastases and their impact on the time interval between diagnosis of carcinoma breast and brain metastases. **Materials and Methods:** In this retrospective study conducted at the Department of Radiation Oncology, Stanley medical college hospital, Chennai, carcinoma breast patients with brain metastases presented to OP during 2013-2022 were included. Various demographic and clinical parameters were assessed and analysed. **Result:** In this study, most of the patients were of 30-50 years, predominantly premenopausal females. More than 90% were of locally advanced stage. The most common histopathology reported was ductal carcinoma of moderately differentiated histology. 31% of patients were HER2 positive molecular subtype followed by Triple Negative. Among the patients who developed Brain metastases, 47% had undergone a complete course of treatment – Surgery in the form of breast conservation surgery or Modified Radical Mastectomy, Neoadjuvant or Adjuvant Chemotherapy followed by Radiotherapy. Only 2 patients in our study presented with Brain Metastases at the time of diagnosis. 29% of patients develop Brain Metastases within 1-2 years of diagnosis of Carcinoma Breast followed by 6 – 12 months and 3 – 4 years each comprising 18% respectively. Headache was the predominant symptom seen in 53% of patients when diagnosed with Brain Metastases followed by weakness of lower limbs. **Conclusion:** Regular metastatic workup is being insisted on for all breast cancer patients who are in regular follow-up so that even asymptomatic patients can be detected at an earlier stage. Though multiple modalities are available for brain metastases, Radiotherapy still plays a vital role in treating Brain Metastases.

INTRODUCTION

Carcinoma Breast is the second most common cancer in females in developing countries like India. Metastatic breast cancer shows an increased trend nowadays because of early detection of breast cancer due to increased awareness at present and effective treatment protocols with multiple modalities such as surgery, chemotherapy, and radiotherapy and increased survival. Carcinoma breast is the second most common cause of brain metastasis after lung cancer. 10-15% of carcinoma breast patients develop brain metastases.^[1]

Various risk factors have been identified for the development of Brain Metastases such as

overexpression of HER2, Triple Negative subtype, higher Histological grade and presence of extracranial metastases. Usually, brain metastases occur along with metastases to other organs such as the lung, spine, liver, and bones. Isolated brain metastases are also seen in 17% of metastatic breast disease. This study aimed at analyzing various epidemiological parameters in association with brain metastases, appropriate investigations and different treatment modalities. The main objective was to analyze various clinicopathological parameters associated with brain metastases and their impact on the time interval between diagnosis of carcinoma breast and brain metastases. The secondary objective was to describe the features of brain metastases.

MATERIALS AND METHODS

This was a retrospective study conducted in the Department of Radiation Oncology, Stanley medical college hospital, Chennai. Data were obtained from clinical records of the patients maintained in our department. This study was conducted following institutional guidelines. All Carcinoma breast patients with Brain Metastases either at diagnosis or during the treatment registered in our department between 2013-2022 were enrolled in our study. Various parameters taken for analysis included the age of the patient at diagnosis, menopausal status, family history, stage grouping at diagnosis, tumour stage, nodal stage, histopathological type and molecular subtypes, treatment modalities, the time interval between diagnosis of breast cancer and brain metastases, symptoms of brain metastases, isolated or combined with other metastases, the total number of lesions and location, investigations that identified brain metastases, treatment options for brain metastases.

Clinical staging was performed according to the 7th edition of the TNM staging of breast cancer by the American Joint Committee on Cancer (AJCC). ER, PR, and HER2 status were assessed by Immunohistochemistry or in situ hybridization analysis. A positive ER or PR status was defined as $\geq 1\%$ of tumor cells with immunostaining. HER2 overexpression/amplification was determined as a 3+ immunohistochemical score ($>30\%$ homogeneous and intense membrane staining of tumor cells) or a positive in situ hybridization result.

RESULTS

In this study, most of the patients were of 30-50 years, predominantly premenopausal females. Male breast cancer patients do not commonly develop brain metastases. More than 90% were of locally advanced stage. The most common histopathology reported was ductal carcinoma of moderately differentiated histology. 31% of patients were HER2 positive molecular subtype followed by Triple Negative. Among the patients who developed Brain metastases, 47% had undergone a complete course of treatment – Surgery in the form of breast conservation surgery or Modified Radical Mastectomy, Neoadjuvant or Adjuvant Chemotherapy followed by Radiotherapy. 53% of them had undergone only one or two modalities. Only 2 patients in our study presented with Brain Metastases at the time of diagnosis. 29% of patients develop Brain Metastases within 1-2 years of diagnosis of Carcinoma Breast followed by 6 – 12 months and 3 – 4 years each comprising 18% respectively [Table 1].

Headache was the predominant symptom seen in 53% of patients when diagnosed with Brain Metastases followed by weakness of lower limbs. MRI Brain was the preferred modality for diagnosing Brain Metastases. Most of the lesions were multiple and commonly seen in the cerebral and cerebellar hemispheres. Also, Brain Metastases were commonly seen combined with metastases to other organs namely the spine, lung, liver, bone, and adrenals. Only 3 of our patients underwent surgery for a single large lesion followed by Whole Brain Radiotherapy. 41 patients were given Whole Brain Radiotherapy. 5 patients were not started on the treatment due to poor general condition and were given symptomatic treatment [Table 2].

Table 1: Patient and tumour characteristics

		Frequency	Percentage
Age Grouping	21-30	1	2%
	31-40	12	24%
	41-50	16	33%
	51-60	12	24%
	61-70	6	12%
	>70	2	4%
Stage Grouping	I	3	6%
	II	13	27%
	III	23	47%
	IV	10	20%
Tumour Stage	T1	4	8%
	T2	18	37%
	T3	7	14%
	T4	19	39%
	Tx	1	2%
Nodal Stage	N0	12	24%
	N1	18	37%
	N2	14	29%
	N3	5	10%
Molecular Subtype	Her2 positive	13	27%
	Luminal	6	12%
	NK	20	41%
	Triple-negative	8	16%
	Triple positive	2	4%

Initial Treatment	Complete	23	47%
	Incomplete (Surgery)	4	8%
	Incomplete (Surgery+Chemotherapy)	9	18%
	Incomplete (Chemotherapy)	4	8%
	Palliative	9	18%
Time of diagnosis to brain metastasis	<6 months	5	10%
	6-12 months	9	18%
	1-2 years	14	29%
	2-3 years	9	18%
	3-4 years	5	10%
	>4 years	5	10%
	At diagnosis	2	4%

Table 2: Characteristics of Brain Metastases

		Frequency	Percentage
Symptoms	Giddiness	4	8%
	Headache	29	60%
	Vomiting	3	6%
	Rt. Orbital pain	1	2%
	Seizures	5	10%
	Slurring of speech	1	2%
	Weakness	6	12%
Isolated or combined	Combined	33	67%
	Isolated	16	33%
No. of Lesions	1	2	4%
	2	12	24%
	3	18	37%
	>3	17	35%
Location	Cerebellum	1	2%
	Cerebellum, Medulla	1	2%
	Cerebellum, Pons	1	2%
	Cerebrum	33	67%
	Cerebrum, Cerebellum	11	22%
	Cerebrum, Pons	1	2%
	Medulla	1	2%
Investigations	CT Brain	10	20%
	MRI Brain	29	59%
	PET CT	10	20%
Treatment for brain metastases	No	5	10%
	Surgery	1	2%
	Surgery + Whole-brain RT	2	4%
	whole brain RT	41	84%

[Table 3] explains the time interval of developing brain metastases among different stages.

Table 3: Stage grouping, Tumour stage, Nodal stage Vs Time interval

	<6 months	6-12 months	1-2 years	2-3 years	3-4 years	>4 years	At diagnosis	Grand Total
I				1	1	1		3
T1				1	1	1		3
N0				1	1	1		3
II	1	4	2	1	2	3		13
T1					1			1
N1					1			1
T2	1	3	1	1	1	2		9
N0		3			1			4
N1	1		1	1		2		5
T3			1			1		2
N0			1			1		2
Tx		1						1
N1		1						1
III	4	4	9	4	2			23
T2		1	5	2				8
N2			3	1				4
N3		1	2	1				4
T3	2	1		1	1			5
N1	1			1	1			3
N2	1	1						2
T4	2	2	4	1	1			10
N0				1	1			2
N1		2	1					3
N2	2		2					4
N3			1					1

IV		1	3	3		1	2	10
T2				1				1
N1				1				1
T4		1	3	2		1	2	9
N0							1	1
N1			2	1			1	4
N2		1	1	1		1		4

DISCUSSION

Breast cancer patients most commonly metastasize to the lungs, spine, liver, bones, and brain.^[2] Isolated brain metastases are also seen in 17% of patients. This leads to a significant increase in morbidity and mortality thereby affecting the quality of life of patients.^[3] Most of them are symptomatic with neurocognitive impairment while few are asymptomatic.

The blood-brain barrier (BBB) has got a significant impact on the development of brain metastases. BBB is a complex network of capillary endothelial cells surrounded by a basement membrane, astrocytes, and pericytes with specific characteristics such as tight intercellular junctions and lack of fenestrations thereby facilitating low pinocytosis and high electrical sensitivity.^[4] Many chemotherapeutic drugs are not able to cross BBB because of their complex nature even after the tumour invasion into brain parenchyma.

The median age group involved in this study was 30-40 years, predominantly premenopausal females. The most common histopathology was ductal carcinoma of Grade II. Almost most of them have undergone multimodality treatment comprising Surgery, Chemotherapy, Radiotherapy, and Hormonal therapy if needed. Hence these parameters did not have any significant effect on the time interval between the diagnosis of breast cancer and the development of brain metastases. Among 49 patients, 33 patients were presented in locally advanced stage (stage III and IV) during the diagnosis of primary breast carcinoma. 39% of them were T4 and 39% of them were N2 N3 disease. Ten of them were already metastatic with extracranial metastases such as lung, liver, spine and bone metastases.

One of the most important prognostic factors is the Molecular subtype. They are broadly classified into Luminal (ER, PR +ve), HER2 Positive (ER, PR +ve or ER, PR -ve) and Triple Negative. A good prognosis is usually found in the Luminal subtype followed by HER2 Positive and Triple Negative subtypes. Triple Negative is more commonly seen among young premenopausal females which accounts for the highly aggressive nature of tumour in these patients.^[5] The time interval between primary diagnosis to brain metastases is shorter for HER2 Positive and Triple Negative subtypes when compared to the Luminal subtype which is reciprocated in this study too.^[6] The main limitation was immunohistochemistry which was not done in our institute during the early study period of our study and they were classified as the Not Known category

in whom the time interval for developing Brain Metastases was around 6-12 months. [Figure 1].

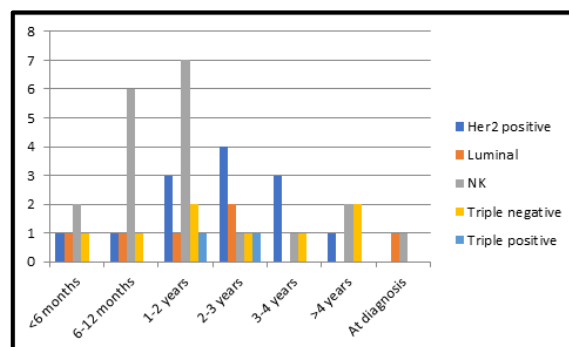


Figure 1: Molecular Subtype and Time Interval

Half of the patients with HER2 Positive subtype develop brain metastases over time.^[7] Previous studies have shown HER2 Positive subtype develops brain metastases with controlled extracranial disease progression after the advent of Trastuzumab whereas the Triple Negative subtype has both cranial and extracranial disease progression.^[8,9] In our study, both the subtypes show isolated lesions and combined lesions. In the Luminal subtype metastases to the spine are commonly seen and later they either progress to cranial or extracranial metastases.

Most of the patients in our study presented with headache, giddiness, and seizures followed by weakness of limbs, ataxia, and blurring of vision and only a few were asymptomatic with an incidental finding during their regular follow-up. Only three patients presented with a single large lesion in the cerebrum which on excision showed metastatic carcinomatous deposits. Few of them had two lesions and most of them had multiple lesions mainly in the cerebral and cerebellar hemispheres. One study validated the breast cancer-specific Graded Prognostic Assessment and refined it with the addition of several brain metastases.^[10]

Investigations used for diagnosing brain metastases are Contrast-enhanced CT Brain, MRI Brain preferably with contrast and MR Spectroscopy, PET-CT. MRI Brain is mostly preferred for symptomatic patients. Stereotactic biopsy is also done if the lesion is single and large and suspicious of primary CNS tumour. MRI Spine screening is also preferred in patients with brain metastases.

Treatment modalities for brain metastases include surgery, stereotactic radiosurgery (SRS) and whole-brain radiotherapy. Advantages of surgery include complete excision of the lesion if feasible, relief of intracranial tension and histopathological evidence of secondary carcinomatous deposits. Surgery is widely

preferred for a single large lesion. Surgical excision followed by Whole-brain RT has improved survival than excision alone.^[11]

SRS is preferred for small lesions, usually less than 3 lesions and lesions in eloquent areas. SRS delivers high-precision photon radiation to a small target volume sparing most of the normal brain tissue thereby causing less toxicity.^[12] Whole Brain Radiotherapy is given for multiple lesions. SRS followed by Whole Brain RT has got improved survival than SRS alone.^[13] Whole Brain Radiotherapy is preferred for multiple lesions to achieve the control of macroscopic metastases and eradicate the microscopic seeding of the brain.

Hippocampal sparing RT has been now developed which reduces neurocognitive toxic effects compared to WBRT thereby preserving memory and quality of life.^[14] [Figure 2]. A drug named Mimantine is also given to preserve neurocognitive function. Steroids to reduce edema, Anti epileptics for patients with seizures are also given. WBRT also alters brain parenchyma and BBB thereby increasing its permeability for chemotherapy and targeted therapy.

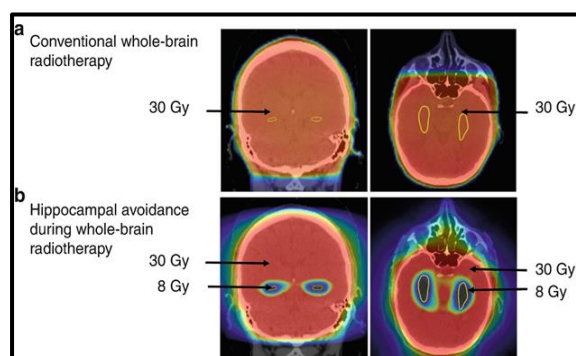


Figure 2: Comparison of Isodoses between WBRT and Hippocampal sparing RT

Palliative Chemotherapy also has an important role after diagnosing brain Metastases. Various chemotherapeutic drugs are administered either as palliative or maintenance chemotherapy. HER2-positive patients have been treated with Trastuzumab and anti-HER2 Targeted agents namely lapatinib and TDM which had shown improvement in survival.^[15] Triple Negative patients are treated with platinum analogues, capecitabine, etc. Luminal patients are given alternate hormonal therapy along with chemotherapy. Nowadays PARP inhibitors are also used. Novel drug delivery systems such as nanoparticles that can cross the BBB to deliver cytotoxic agents are also being explored.^[16]

Brain metastases in breast cancer patients with the Triple Negative subtype have shorter survival periods ranging from 3-6 months.^[17] Although the HER2 Positive subtype has a higher chance of developing brain metastases, their survival is longer about 12-18 months when compared to the Triple Negative subtype.

The performance status of the patient at the time of brain metastases is another factor in determining the

survival of the patient. Most studies have stated that patients with brain metastases who had longer survival had a good performance status of Karnofsky Performance Score of > 70. Also, the location of brain metastases and the number of lesions play a vital role.

CONCLUSION

Brain metastases are nowadays commonly seen among both premenopausal and postmenopausal females. Since performance status plays a vital role in their survival, premenopausal women have longer survival and thereby the quality of life of patients should be taken care of. Many studies insist on analyzing the change of molecular subtypes after the development of brain metastases. Regular metastatic workup is being insisted on for all breast cancer patients who are in regular follow-up so that even asymptomatic patients can be detected at an earlier stage. Though multiple modalities are available for brain metastases, Radiotherapy still plays a vital role in treating Brain Metastases.

REFERENCES

1. Lin NU, Bellon JR, Winer EP. CNS metastases in breast cancer. *J Clin Oncol Off J Am Soc Clin Oncol*. 2004;22(17):3608–17. doi:10.1200/JCO.2004.01.175.
2. Nguyen DX, Bos PD, Massague J. Metastasis: from dissemination to organ-specific colonization. *Nat Rev Cancer*. 2009;9(4):274–84. doi:10.1038/nrc2622
3. Klos KJ, O'Neill BP. Brain metastases. *Neurol*. 2004;10(1):31–46. doi:10.1097/01.nrl.0000106922.83090.71.
4. Fong CW. Permeability of the Blood-Brain Barrier: Molecular Mechanism of Transport of Drugs and Physiologically Important Compounds. *J MembrBiol* 2015;248:651–69. doi:10.1007/s00232-015-9778-9
5. Nam BH, Kim SY, Han HS, Kwon Y, Lee KS, Kim TH, et al. Breast cancer subtypes and survival in patients with brain metastases. *Breast Cancer Res BCR*. 2008;10(1):R20. doi:10.1186/bcr1870.
6. Sperduto PW, Kased N, Roberge D, Chao ST, Shanley R, Luo X, et al. The effect of tumor subtype on the time from primary diagnosis to development of brain metastases and survival in patients with breast cancer. *J Neuro-Oncol*. 2013;112(3):467–72. doi:10.1007/s11060-013-1083-9.
7. Aversa C, Rossi V, Geuna E, Martinello R, Milani A, Redana S, et al. Metastatic breast cancer subtypes and central nervous system metastases. *Breast*. 2014;23(5):623–8. doi:10.1016/j.breast.2014.06.009.
8. Dawood S, Broglio K, Esteva FJ, Ibrahim NK, Kau SW, Islam R, et al. Defining prognosis for women with breast cancer and CNS metastases by HER2 status. *Ann Oncol Off J Eur Soc Med Oncol/ESMO*. 2008;19(7):1242–8. doi:10.1093/annonc/mdn036.
9. Lin NU, Claus E, Sohl J, Razzak AR, Arnaout A, Winer EP. Sites of distant recurrence and clinical outcomes in patients with metastatic triple-negative breast cancer: high incidence of central nervous system metastases. *Cancer*. 2008;113(10):2638–45. doi:10.1002/cncr.23930.
10. Subbiah IM, Lei X, Weinberg JS, Sulman EP, Chavez-MacGregor M, Tripathy D, et al. Validation and development of a modified breast graded prognostic assessment as a tool for survival in patients with breast cancer and brain metastases. *J Clin Oncol Off J Am Soc Clin Oncol*. 2015;33(20):2239–45. doi:10.1200/JCO.2014.58.8517.
11. Rades D, Kieckebusch S, Haatanen T, Lohynska R, Dunst J, Schild SE. Surgical resection followed by whole brain radiotherapy versus whole brain radiotherapy alone for single

- brain metastasis. *Int J RadiatOncolBiol Phys.* 2008;70(5):1319–24. doi:10.1016/j.ijrobp.2007.08.009.
12. Yamamoto M, Serizawa T, Shuto T, Akabane A, Higuchi Y, Kawagishi J, et al. Stereotactic radiosurgery for patients with multiple brain metastases (JLGK0901): a multi-institutional prospective observational study. *Lancet Oncol.* 2014;15(4):387–95. doi:10.1016/S1470-2045(14)70061-0.
 13. Tsao M, Xu W, Sahgal A. A meta-analysis evaluating stereotactic radiosurgery, whole-brain radiotherapy, or both for patients presenting with a limited number of brain metastases. *Cancer.* 2012;118(9):2486–93. doi:10.1002/cncr.26515.
 14. Gondi V, Pugh SL, Tome WA, et al. Preservation of memory with conformal avoidance of the hippocampal neural stem-cell compartment during whole-brain radiotherapy for brain metastases (RTOG 0933): a phase II multi-institutional trial. *J Clin Oncol* 2014;32:3810-6. 10.1200/JCO.2014.57.2909
 15. Xiao W, Zheng S, Yang A, Zhang X, Zou Y, Tang H, et al. Breast cancer subtypes and the risk of distant metastasis at initial diagnosis: a population-based study. *Cancer Manag Res.* 2018; 10:5329–38. doi: 10.2147/CMAR.S176763
 16. Brosnan EM, Anders CK. Understanding patterns of brain metastasis in breast cancer and designing rational therapeutic strategies. *Ann Transl Med.* 2018;;6(9):163. doi:10.21037/atm.2018.04.35.
 17. Hung MH, Liu CY, Shiao CY, Hsu CY, Tsai YF, Wang YL, et al. Effect of age and biological subtype on the risk and timing of brain metastasis in breast cancer patients. *PloS One.* 2014;9(2):e89389. doi:10.1371/journal.pone.0089389.