

CLINICAL AND RADIOLOGICAL OUTCOME OF INTRAMEDULLARY CANNULATED HEADLESS COMPRESSION SCREW FIXATION OF METACARPAL AND PHALANGEAL FRACTURES

R. Arokiya Amalan,¹ S. Dinesh², A. Suresh Kumar³, N. Manikandan⁴

Received : 22/01/2023
Received in revised form : 19/02/2023
Accepted : 02/03/2023

Keywords:

Metacarpal, Phalangeal fracture fixation, Midshaft, Minimal invasive, Herbert screw, Headless cannulated compression.

Corresponding Author:

Dr. S. Dinesh

Email: dinesngl@yahoo.com

DOI: 10.47009/jamp.2023.5.2.115

Source of Support: Nil,

Conflict of Interest: None declared

Int J Acad Med Pharm
2023; 5 (2); 552-556



¹Associate Professor, Department of Orthopedics, Tirunelveli Medical College, Tamilnadu, India.

²Assistant Professor, Department of Orthopedics, Tirunelveli Medical College, Tamilnadu, India.

³Professor, Department of Orthopedics, Tirunelveli Medical College, Tamilnadu, India.

⁴Professor, Department of Orthopedics, Tirunelveli Medical College, Tamilnadu, India.

Abstract

Background: Displaced metacarpal and phalangeal fractures with clinical deformity are commonly treated operatively with reduction. Recent studies have shown good functional outcomes with surgical management of metacarpal and phalangeal fractures using headless cannulated compression screws. Benefits include an early range of motion, faster recovery, limited dissection, and reduced complications. Improper technique, which is readily avoidable, can lead to suboptimal results. This study evaluates the radiological and functional outcomes of patients treated with headless cannulated compression screws for metacarpal and phalangeal fractures. **Materials and Methods:** This study is conducted in the Department of Orthopaedics, Medical College Hospital, Tirunelveli, from December 2020 to November 2022 and is a prospective study. The patient's demographics, the fracture's cause, the pattern, and the surgical results were all noted. X-ray radiographs were used to evaluate every patient before surgery. We used 3.5 Herbert and 2.7 Herbert screws. **Result:** Our study showed metacarpal and phalangeal fractures treated with intramedullary screws; all the cases showed bone union (100%). The functional result assessed by the Total Active Flexion score showed excellent results in 86% of the patients (26 of 30 cases), good in 2% of cases (2 of 30 cases), and fair in 2 cases (2 of 30 cases). Intramedullary fixation is a trusted and safe procedure for metacarpal and phalangeal shaft fractures. **Conclusion:** Transverse and short oblique metacarpal shaft and proximal phalanx fractures can be surgically treated using headless compression screws. This intramedullary fixation is not recommended for long oblique and comminuted fractures due to the excessive compression that causes shortening.

INTRODUCTION

Hand bone fractures are among the most frequent fractures in people, yet treatment differs greatly worldwide. Less costly techniques for treating hand fractures are more frequently used in developing nations.^[1] Early adolescence, immediately after the most rapid bone development, is when hand fractures often happen in both male and female patients. 3–8 Men are twice as likely as women to experience hand fractures in their lifetime, and most of these fractures happen between the ages of 15 and 40 when people are most active and productive in the workforce.^[2]

14–28% of all visits to the emergency room are for metacarpal and phalangeal fractures. The severity of the initial injury and how it is treated can impact the

functional result of fractures of the small hand bones. The functional outcome is paramount; mending the fracture in hand is not a standalone objective.^[3] Treatment options for metacarpal and phalangeal fractures are varied. Orthoses or early-protected mobilization are effective treatments for stable fractures. One of the several surgical methods discussed is excellent for treating unstable fractures. 10% of all fractures in hand and forearm are metacarpal and phalanx fractures.^[4]

If, during a clinical examination, the fractured finger can be actively moved by 50% of its range of motion without hurting, the fracture is deemed functionally stable. Radiographs of the shattered fragment in two planes with the least angulation and displacement are regarded as radiologically stable.^[4] A single intramedullary headless screw (IMHS) may

not be sufficient to provide appropriate fixation for some fracture patterns, even though IMHS fixation represents a potential minimally invasive surgical treatment option for unstable proximal phalanx fractures.^[5]

Surgical reduction is a typical treatment for clinically deformed displaced metacarpal and phalangeal fractures. Recent investigations employing headless cannulated compression screws for surgical therapy of metacarpal and phalangeal fractures have demonstrated satisfactory functional success outcomes.^[6]

This study evaluated the radiological and functional outcomes of patients treated with headless cannulated compression screws for metacarpal and phalangeal fractures.

MATERIALS AND METHODS

A prospective study was conducted in the Department of Orthopaedics, Medical College Hospital, Tirunelveli, from December 2020 to November 2022. The patients were prospectively enrolled after institutional board permission. The patient's demographics, the fracture's cause, the pattern, and the surgical results were all noted. X-ray radiographs were used to evaluate every patient before surgery. Around 30 patients with intramedullary cannulated headless compression screws were included in the research.

Inclusion criteria: Patients aged 18 to 70 years, Individuals with unstable extra-articular metacarpal and middle and proximal phalange fractures, transverse fractures, little comminution, short oblique fractures, and compound grade 1 and 2 fractures were included in the research.

Exclusion criteria: Extensive wound contamination, segmental metacarpal bone loss, lengthy oblique and spiral shaft fractures, metacarpal neck, compound grade 3 fractures, intra-articular fractures, subchondral fractures, and open epiphyses were among the exclusion criteria for research participants.

All patients were surgically treated in the orthopaedics department. After surgery, every patient was monitored for a minimum of 6 months. A detailed post-operative rehabilitation program was supplied to the patients. QuickDASH score and total active motion were used to evaluate clinical outcomes over 6, 12, and 24 weeks. A radiological evaluation was performed every six, twelve, and twenty-four weeks. Herbert screw of 3.5 and 2.7mm was used in this study [Figure 1].



a. 3.5 Herbert screw b. 2.7mm Herbert screw
Figure 1: Implants used in the fixation

Surgical Technique

Metacarpal fractures-Retrograde technique: The patient is in the supine position. The proximal phalanx was maximally flexed to expose the head of the metacarpal. 3. A 0.5- to 1-cm transverse incision was made over the metacarpal phalangeal joint, and the extensor tendon retracted medially or laterally. Under fluoroscopic guidance, after fracture reduction, we inserted a 1.0-mm guidewire along the longitudinal axis of the metacarpal. The entry point should be on the dorsal part of the metacarpal head for optimal positioning of the screw inside the intramedullary canal. Once the position of the guidewire was confirmed with fluoroscopy, medullary canal reaming was done using a cannulated drill bit. Appropriate screw length was calculated based on preoperative Imaging. Ultimately, we ensured the head threads were buried below the cartilage line [Figure 2].

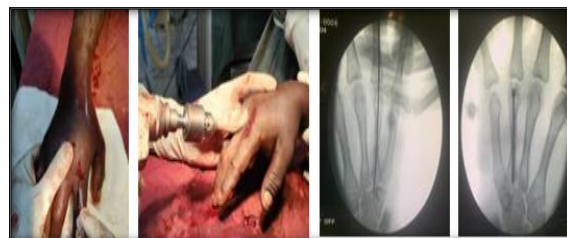

Figure 2: Metacarpal fractures- Retrograde technique

Proximal phalanx fractures Intra-articular technique: A 0.5- to 1-cm transverse incision was made over the metacarpal phalangeal joint, and the extensor tendon retracted. The base of the proximal phalanx is pushed dorsally to provide a dorsal subluxation. The guidewire is advanced across the fracture site. The following steps are the same as above [Figure 3].

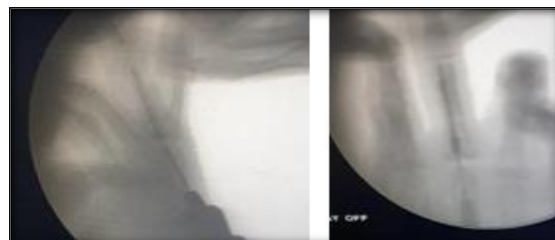


Figure 3: Proximal Phalanx fracture- Retrograde technique

Retrograde intra-articular technique for proximal phalanx: 3.0 mm incision is made over the proximal interphalangeal (PIP) joint, which is flexed 90°. The wire is then advanced into the base of the proximal phalanx along its longitudinal axis. This is an easier and technically faster procedure but creates a larger area of chondral damage to the joint surface of the head of the proximal phalanx. (Figure 3)

Post-op protocol: Early mobilization is encouraged immediately after the surgery (POD 1). No splint is needed. Sutures are removed on a post-operative day 10-12. Strengthening exercises and

weightlifting can be initiated with radiographic and clinical evidence of union.

RESULTS

In this study, 30 patients were included. Five patients (17%) were female patients, whereas 25 patients (83%) were men. The right hand was affected in 23 cases (or seven patients, or 77%). For metacarpal and phalangeal fractures, closed reduction with intramedullary headless compression screws resulted in 100% bone union in all 30 patients. Traffic accidents were the most common cause of injuries (73%). Additional causes were violence and machine-cut injuries. Of 30 cases, 10 had proximal phalanx fractures, and 19 suffered metacarpal fractures. One person's phalanx and metacarpals were broken. Bony union was often observed between 6 and 8 weeks, with an average time of 7.2 weeks (range 6-10 weeks). No instances included non-union labor. Around 55% of patients only have a metacarpal or phalangeal fracture. Injuries to the tendon, the ipsilateral upper limb, or the lower limb occur in 45% of cases. In our study, one patient had a traumatic amputation at the level of the distal interphalangeal joint. For the same finger PPX#, she had screw fixation. MCP and PIJ's ROMs were excellent. TAM score as a whole was impacted, though. There were no extensor lag, infection, non-union, or malrotation issues. By six weeks, 63% of patients were back at work. Where the majority of patients just suffered hand fractures. It was not just the hand fractures that caused a late return to work; there were other ailments. There was a two-week waiting period before returning to work. QuickDASH and the TAF (Total Active Flexion) score from the American Society Score of Hand (ASSH) are used to evaluate the functional outcome. Out of 30 patients, 26 (or 86%) had great outcomes, two (or 6%) had acceptable ones, two (or 6%) had fair ones, and one patient had no results at all. Overall, the outcomes are satisfactory. Metacarpophalangeal joint stiffness initially appeared in 6 cases. Three individuals had great results from rigorous physical treatment. Because of concurrent ailments, including tendonitis and ipsilateral forearm fractures, the other three patients had not improved.

Case 1

An 18-year-old male patient presented with a fractured shaft of the right-hand 2nd PPX and 2nd and 3rd metacarpal managed with closed reduction.

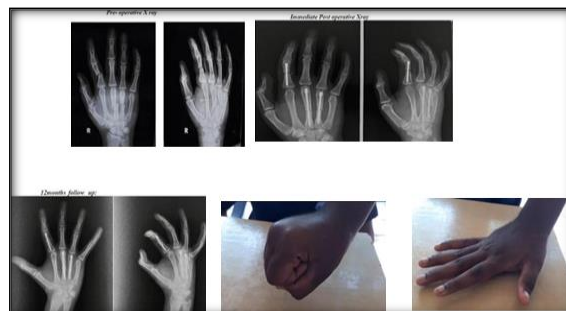


Figure 4: Right second PPX shaft and 2nd and 3rd metacarpal shaft fracture

Case 2

A 34-year-old male with a closed 3rd metacarpal fracture of the left hand.

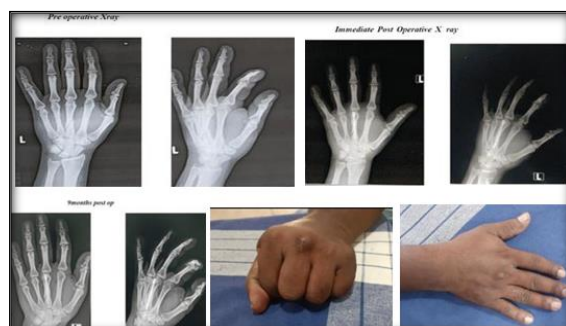


Figure 5: Left third metacarpal fracture

Case 3

A 39-year-old right-hand male sustained closed fractures of the 2nd and 3rd PPX.

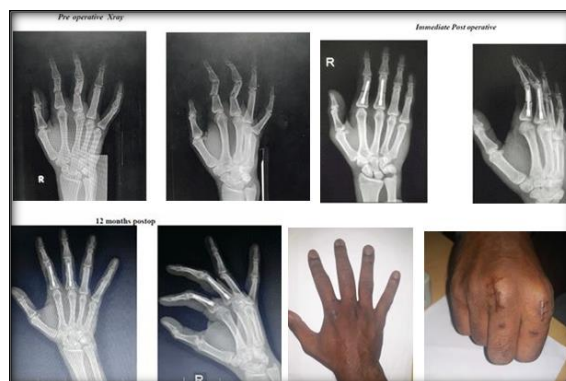

Figure 6: Right 2nd and 3rd PPX fracture

DISCUSSION

The hands are used for mechanical and dexterous grasping, pinching, and hooking activities. Suppose a hand injury causes severe functional limitation, such as a fracture or tendon damage. Thus, it's vital to lessen disability after hand fractures. Several treatments for metacarpal and phalangeal fractures are available, including volar below elbow slab, closed or open reduction with K wire fixation, lag screws, micro plating, and external fixators. Metacarpal fractures treated with intramedullary

treatment have been demonstrated to have positive results.^[7]

The classic volar slab method must immobilise all hand and wrist joints for a long time. It causes all of the fingers to stiffen. Also, it is not suitable for displaced or unstable fractures.^[8] K-wire fixation has the advantage of requiring only modest surgical dissection. Still, it also requires greater post-operative immobilization related to worse-than-optimum functional outcomes, increased tendon adhesions, and articular contractures.^[9] 77% of fingers using the closed method for unstable fractures lost function, according to James et al. Open reduction and internal fixation with K wire is one therapeutic option for these unstable fractures. However, it gives a less stiff fixation and is rotationally unstable.^[10]

In contrast to dorsal plating, which requires a more extensive dissection, and the intramedullary screw can be put by a modest dorsal incision. Moreover, the whole piece of hardware for the compression screw is buried inside the metacarpal, making it unlikely to irritate adjacent soft tissue or rip tendons. Lastly, unlike K-wires, the compression screw allows early active motion workouts to decrease stiffness. Due to these advantages, intramedullary compression screws are a popular approach for repairing fractures of the metacarpal and phalanx shafts.^[11]

The diameter and length of the screw are critical in avoiding the spread of an existing fracture or the formation of a new fracture. The screw's outer diameter must be less than the isthmus of the shaft at the metacarpal isthmus. Dorsal access via the fracture site is required to remove the other portion of the screw, especially for metacarpal fractures. Although executing a new intramedullary screw fixation is technically feasible afterwards, osteosynthesis with a plate is typically advised due to the danger of further joint injury and screw loosening. Additionally, the screw may bend in situations involving new trauma. Making a dorsal approach via the fracture site is required in instances with extensive flexion and rotational deformity to mobilize the screw and remove it through the joint with a second incision.^[12]

During our radiological examinations of the head of the proximal phalanx, a single screw damaged around 20% of the surface. The hole in the metacarpal is also dorsally, at an area of the proximal phalanx that is largely not load-bearing, as most of our movements are performed with the fingers in flexion. Faster return to normal activities of daily living and employment is the main advantage of IMF over other treatments. Compared to K-wire fixation, early range of motion and restricted immobilization benefits include a much-reduced stiffness rate.^[13]

Many studies demonstrate that intramedullary screw fixation of metacarpal and phalangeal fractures yield excellent outcomes. The whole active MCP joint range of motion was shown by Ruchelesman et al.,

and a metacarpal neck and shaft fracture had a 100% union rate.^[14] Jann et al. studied screw treatment for unstable metacarpal fractures and found that 16 of 20 patients had satisfactory outcomes. One has a 15-degree extensor lag. There were two incidences of stiffness. Another requires screw replacement owing to proximal screw movement.^[6] Giesen et al. tracked 30 patients with proximal and middle phalanx fractures and found that they had satisfactory outcomes.^[15]

Our study showed the metacarpal and phalangeal fractures treated with an intramedullary screw; all patients (100%) demonstrated bone union. The Total Active Flexion score revealed an exceptional outcome in 86% of the patients (26 of 30 cases), a good result in 2% of cases (2 of 30 instances), and a fair result in 2 cases (2 of 30 cases). Intramedullary fixation is a reliable and safe treatment for fractures of the metacarpal and phalangeal shafts. This type of secure internal fixation, in particular, avoids the need for immobilization and the attendant stiffness, reoperation, and problems. It also allows for early post-operative mobility while not impacting union rates.

CONCLUSION

Headless compression screws can be used successfully in surgery to treat transverse and short oblique metacarpal shaft and proximal phalanx fractures. This intramedullary treatment is not advised for long oblique and comminuted fractures due to severe compression that results in shortening. This method has an advantage over the others because it doesn't require later hardware removal and immediately provides rotational stability. So mobilization can start sooner. This would benefit those who need to resume their normal activities and jobs sooner.

REFERENCES

1. Bernstein ML, Chung KC. Hand fractures and their management: an international view. *Injury* 2006; 37:1043–8.
2. Feehan LM, Sheps SS. Treating hand fractures: a population-based study of acute health care use in British Columbia. *Can Fam Physician* 2008; 54:1001–7.
3. Gupta R, Singh R, Siwach R, Sangwan S, Magu NK, Diwan R. Evaluation of surgical stabilization of metacarpal and phalangeal fractures of the hand. *Indian J Orthop* 2007; 41:224–9.
4. Kamath JB, Harshvardhan, Naik DM, Bansal A. Current concepts in managing fractures of metacarpal and phalanges. *Indian J Plast Surg* 2011; 44:203–11.
5. Gaspar MP, Gandhi SD, Culp RW, Kane PM. Dual antegrade intramedullary headless screw fixation for treatment of unstable proximal phalanx fractures. *Hand (N Y)* 2019; 14:494–9.
6. Jann D, Calcagni M, Giovanoli P, Giesen T. Retrograde fixation of metacarpal fractures with intramedullary cannulated headless compression screws. *Hand Surg Rehabil* 2018; 37:99–103.
7. Doarn MC, Nydick JA, Williams BD, Garcia MJ. Retrograde headless intramedullary screw fixation for displaced fifth metacarpal neck and shaft fractures: short term results. *Hand (N Y)* 2015; 10:314–8.

8. Barton NJ. Fractures of the hand. *J Bone Joint Surg Br* 1984; 66:159–67.
9. Eisenberg G, Clain JB, Feinberg-Zadek N, Leibman M, Belsky M, Ruchelsman DE. Clinical outcomes of limited open intramedullary headless screw fixation of metacarpal fractures in 91 consecutive patients. *Hand (N Y)* 2020; 15:793–7.
10. James JI. Fractures of the proximal and middle phalanges of the fingers. *Acta Orthop Scand* 1962; 32:401–12.
11. Dyrna FG, Avery DM, Yoshida R, Lam D, Oeckenpöhler S, Cote MP, et al. Metacarpal shaft fixation: a biomechanical comparison of dorsal plating, lag screws, and headless compression screws. *BMC Musculoskelet Disord.* 2021; 22:1-8.
12. Guidi M, Frueh FS, Besmens I, Calcagni M. Intramedullary compression screw fixation of metacarpal and phalangeal fractures. *EFORT Open Rev* 2020; 5:624–9.
13. Chao J, Patel A, Shah A. Intramedullary screw fixation comprehensive technique guide for metacarpal and phalanx fractures: Pearls and pitfalls. *Plast Reconstr Surg Glob Open* 2021; 9: e3895.
14. Ruchelsman DE, Puri S, Feinberg-Zadek N, Leibman MI, Belsky MR. Clinical outcomes of limited-open retrograde intramedullary headless screw fixation of metacarpal fractures. *J Hand Surg Am* 2014; 39:2390–2395.
15. Giesen T, Gazzola R, Poggetti A, Giovanoli P, Calcagni M. Intramedullary headless screw fixation for fractures of the proximal and middle phalanges in the digits of the hand: a review of 31 consecutive fractures. *J Hand Surg Eur Vol.* 2016; 41:688–694.