

ANTERIOR MEDIASTINAL MASS - HOW DO WE MANAGE IT? - OUR INSTITUTIONAL EXPERIENCE- CASE SERIES

B. Karthikeyan¹, K. J. Vignesvaran², A. Senthilkumar³, B. Rajesh Kumar⁴ Joshinth Joseph⁵

Received : 06/01/2023

Received in revised form : 11/02/2023

Accepted : 27/02/2023

Keywords:

Thymoma, Myasthenia Gravis, Thymectomy, Plasmapheresis, IVIG.

Corresponding Author:

Dr. B. Rajesh Kumar

Email: karthikeyanctsmbs@gmail.com

DOI: 10.47009/jamp.2023.5.2.111

Source of Support: Nil,

Conflict of Interest: None declared

Int J Acad Med Pharm

2023; 5 (2); 529-531



¹Senior Resident, Department of Cardiovascular and Thoracic Surgery, Madurai Medical College, Tamilnadu, India.

²Senior Resident, Department of Cardiovascular and Thoracic Surgery, Madurai Medical College, Tamilnadu, India

³Assistant Professor, Department of Respiratory Medicine, Madurai Medical College, Tamilnadu, India

⁴Assistant Professor, Department of Respiratory Medicine, Madurai Medical College, Tamilnadu, India

⁵Postgraduate, Department of Cardiovascular and Thoracic Surgery, Madurai Medical College, Tamilnadu, India

Abstract

Background: A variety of conditions can cause anterior mediastinal masses. In this study, we discuss how we evaluate and manage the patients admitted to the Department of Cardiovascular and Thoracic Surgery (CVTS) and Department of Respiratory Medicine, Govt Rajaji Hospital (GRH) Madurai Medical College, Madurai. The 21 patients included in the study total 14 thymomas and seven lymphoma cases after the final biopsy. About 50% of patients with thymoma have myasthenia gravis, and approximately 10%–20% of patients with MG have thymoma. AChR antibodies are the main reason for muscle weakness in thymoma MG patients. Thymectomy can be done transsternal or through a VATS video-assisted thoracoscopic approach. In most patients, the total thymectomy of a thymoma cures the thymic neoplasia. But patients will continue to suffer from MG after thymectomy. So it is needed for continuing follow-up of patients and pharmacological treatment. Our department gives plasmapheresis or IVIG treatment to all patients with thymoma MG before thymectomy surgery.

INTRODUCTION

Various benign and malignant conditions, including thymoma, lymphoma, thyroid mass, germ cell tumours, etc., can cause anterior mediastinal masses. The management of anterior mediastinal mass is mainly based on imaging studies and biopsy.^[1]

Large mediastinal masses often have surgical challenges due to compression and invasion of nearby vital structures. Also, produce mediastinal mass syndrome characterized by acute respiratory and hemodynamic decompensation due to mechanical compression of mediastinal structures.

Therefore, meticulous pre-operative assessment, preparation and planning are needed. In this study, we discuss how we evaluate and manage the patients admitted to our hospital.^[2]

MATERIALS AND METHODS

A study involved patients admitted in the Department of Cardiovascular and Thoracic Surgery (CVTS) and Department of Respiratory Medicine, Govt Rajaji Hospital (GRH) and Madurai Medical College, Madurai, as an anterior mediastinal mass on imaging studies. Patients with an anterior mediastinal mass on imaging studies with no history of trauma to the chest, previous radiation and sternotomy were included.

Pre-Operative Assessment

All patients with the above criteria undergo Contrast Enhanced CT (CECT) chest, MRI in a selected case, and guided biopsy. Respiratory function test, routine blood investigation and in case of thymoma, serum Ach receptor antibodies level were evaluated for signs and symptoms of myasthenia gravis. If there is an elevated level of Ach receptor antibodies or signs of myasthenia gravis, the patient undergoes two to three cycles of plasmapheresis before surgery.^[3]

RESULTS

Totally 21 patients included in the criteria were evaluated. 13 patients are female and eight male patients, aged from 10 years to 72 years, with a mean of 42. Six patients were found to have lymphoma, and 15 patients were found to have thymic mass (Figure 1). Of the 15 patients, five patients had signs of myasthenia gravis (Figure 2), with elevated Ach receptor antibodies in 3 patients (Figure 3). All 15 patients got operated on through sternotomy with extended total thymectomy done. Six patients with lymphoma send for chemotherapy. One patient's post-op biopsy came as thymic scirrhous Hodgkin's lymphoma; all others are benign thymoma, totalling 14 thymoma and seven lymphoma cases after the final biopsy. In the case of thymoma, 11 patients are female, and three are male (Figure 4). All patients with myasthenia gravis signs are female, aged 20 to 40 years, three patients and 60 to 70 years two. In the case of lymphoma, the 5 patients are males and 2 females.

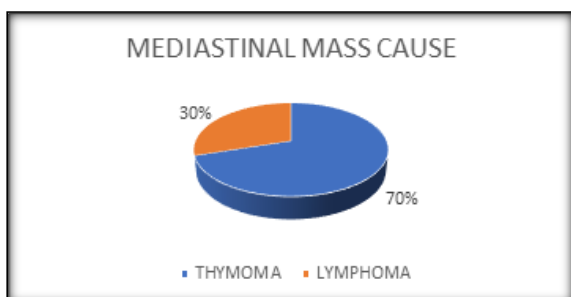


Figure 1: Distribution of mediastinal mass cause

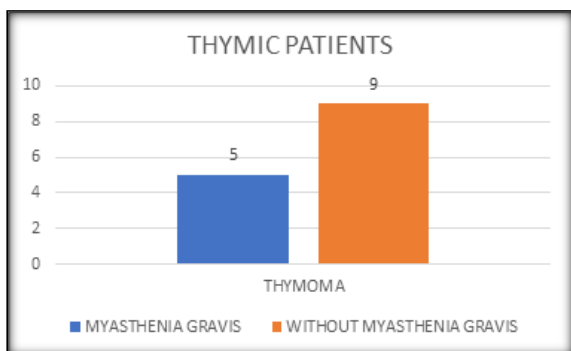


Figure 2: Distribution of thymic patients

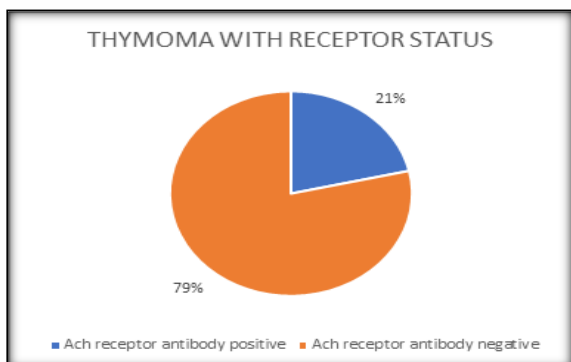


Figure 3: Distribution of thymoma with receptor status

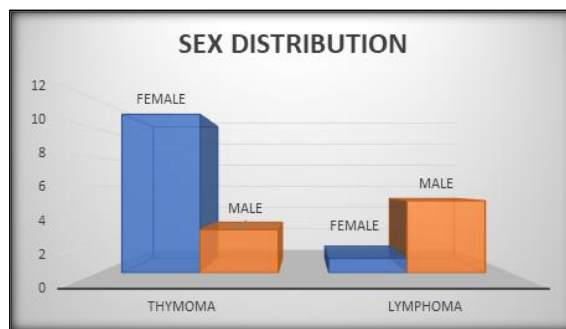


Figure 4: Distribution of gender

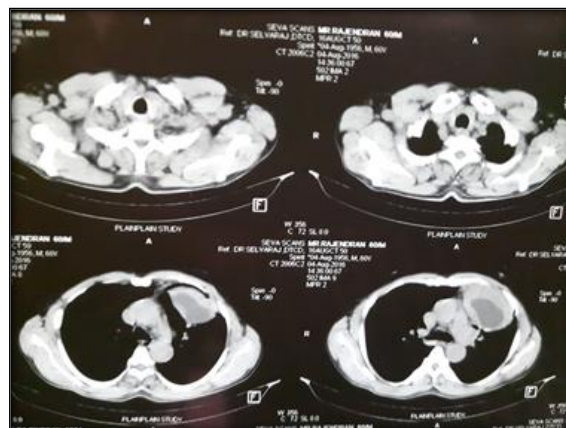
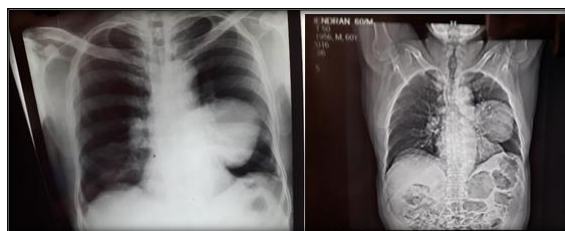


Figure 5: Pre-operative X-ray and CT chest showing Anterior mediastinal mass

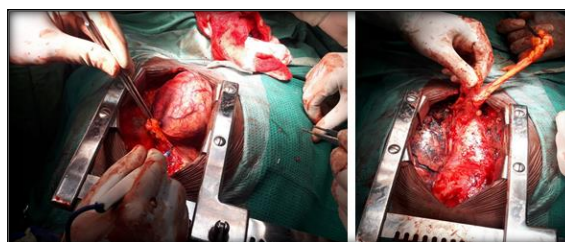


Figure 6: Intra-operative picture showing resection of Anterior mediastinal mass by Extended Total Thymectomy

DISCUSSION

The anterior mediastinum contains the thymus, fat, and lymph nodes, corresponding with the most common aetiologies of associated primary tumours.^[4] Although two-thirds of mediastinal masses are benign, about 59% of masses in the anterior compartment are malignant. Thymomas are the most common tumour of the thymus in adults and the most common primary tumour of the anterior mediastinum in adults. Thymomas are mostly benign or low-grade slow, growing

malignant tumours of thymic epithelial tissue. The average age at the diagnosis is approximately fifty years, earlier in those who present with symptoms of myasthenia gravis. Thymomas are not common below the age of 15 and very rare under 20. Thymomas may be well encapsulated (non-invasive) or extend beyond the thymic capsule (invasive). Many syndromes are seen in patients with thymoma, like hypogammaglobulinemia and pure red cell aplasia.

Myasthenia gravis is a neuromuscular junction disease characterized by muscular weakness and fatigue. It is caused in 85% of cases by AChR antibodies. When Myasthenia gravis (MG) occurs together with a thymoma, Myasthenia gravis is a paraneoplastic disease caused by the presence of the thymoma. About 50% of patients with thymoma have myasthenia gravis, and approximately 10%–20% of patients with MG have thymoma. AChR antibodies are the main reason for muscle weakness in thymoma MG patients. When the diagnosis of thymoma in MG patients is established, it should be removed surgically. It is crucial to ensure the radical excision of the tumour in toto. Thymectomy can be done transsternal or through a VATS video-assisted thoracoscopic approach. Extended total thymectomy of a thymoma done in most patients cures thymic neoplasia. But patients will continue to suffer from MG after thymectomy. So, it is needed for continuing follow-up of patients and pharmacological treatment. When the tumour invades beyond the thymus involving the pleura or the pericardium, surgery with radical excision may not be possible in a few cases, and further oncological treatment is necessary. Pre-operative plasmapheresis (PLAX) or intravenous immunoglobulin (IVIG) infusion removes circulating pathogenic antibodies.^[7-10]

Our department gives plasmapheresis or IVIG treatment to all patients with thymoma MG before thymectomy surgery to minimize the risk of post-thymectomy MG exacerbation and myasthenic crisis.

Lymphomas are responsible for approximately 15% of all primary mediastinal masses and 45% of anterior mediastinal masses in children. Only 10%

of lymphomas that involve the mediastinum are primary (i.e., mediastinal involvement, not part of systemic disease), and the majority are Hodgkin lymphomas (~60%). Management of lymphoma is primarily by chemotherapy only; decompression is rarely needed in case of compression of major vital structures.^[5]

CONCLUSION

Most anterior mediastinal masses are benign, primarily due to thymic neoplasm followed by lymphomas. Most thymic neoplasms are treated surgically with good results. Proper pre-operative evaluation of thymic neoplasm for myasthenia gravis is important for the best outcome. Although thymectomy reduces the symptoms of myasthenia gravis not completely curable. Lifelong medical management is needed to control the disease.

REFERENCES

1. Carter BW, Marom EM, Detterbeck FC. Approaching the patient with an anterior mediastinal mass: a guide for clinicians. *J Thorac Oncol.* 2014; 9: S102-9.
2. Juanpere S, Cañete N, Ortuño P, Martínez S, Sanchez G, Bernado L. A diagnostic approach to the mediastinal masses. *Insights Imaging.* 2013; 4:29-52.
3. Gilhus NE. Myasthenia Gravis. *N Engl J Med.* 2016; 375:2570-2581.
4. Duwe BV, Sterman DH, Musani AI. Tumours of the mediastinum. *Chest.* 2005; 128:2893-909.
5. Johnson PWM, Davies AJ. Primary mediastinal B-cell lymphoma. *Hematol Am Soc Hematol Educ Program.* 2008; 2008:349-58.
6. Marx A, Willcox N, Leite MI, Chuang W-Y, Schalke B, Nix W, et al. Thymoma and paraneoplastic myasthenia gravis. *Autoimmunity* 2010; 43:413-27.
7. Nagayasu T, Yamayoshi T, Matsumoto K, Ide N, Hashizume S, Nomura M, et al. Beneficial effects of plasmapheresis before thymectomy on the outcome in myasthenia gravis. *Jpn J Thorac Cardiovasc Surg* 2005; 53:2-7.
8. El-Bawab H, Hajjar W, Rafay M, Bamousa A, Khalil A, Al-Kattan K. Plasmapheresis before thymectomy in myasthenia gravis: routine versus selective protocols. *Eur J Cardiothorac Surg* 2009; 35:392-7.
9. Iváñez V, Díez-Tejedor E, Lara M, Barreiro P. Usefulness of plasmapheresis before thymectomy in the management of myasthenia gravis. *Neurologia* 1994; 9:277-81.
10. Vucic S, Davies L. Safety of plasmapheresis in the treatment of neurological disease. *Aust N Z J Med* 1998; 28:301-5.