

## MASQUERADERS OF MALIGNANCY-A CLINICOPATHOLOGICAL CASE SERIES

Johnsy Merla J<sup>1</sup>, Gayathri G<sup>2</sup>, S.Vinodhini<sup>3</sup>, Selin Sofiah C<sup>4</sup>, Selin Sofiah C<sup>5</sup>

Received : 19/01/2023  
Received in revised form : 15/02/2023  
Accepted : 27/02/2023

**Keywords:**  
Histopathology, Masqueraders, Malignancy.

Corresponding Author:  
**Dr. Selin Sofiah C**  
Email: sofiahherman@gmail.com

DOI: 10.47009/jamp.2023.5.2.109

Source of Support: Nil,  
Conflict of Interest: None declared

*Int J Acad Med Pharm*  
2023; 5 (2); 522-525



<sup>1</sup>Associate Professor, of Pathology, Tirunelveli Medical College, Tamilnadu, India.

<sup>2</sup>Associate Professor, of Pathology, Tirunelveli Medical College, Tamilnadu, India.

<sup>3</sup>Assistant Professor, of Pathology, Tirunelveli Medical College, Tamilnadu, India.

<sup>4</sup>Assistant Professor, of Pathology, Tirunelveli Medical College, Tamilnadu, India.

<sup>5</sup>Professor of Pathology, Tirunelveli Medical College, Tamilnadu, India.

### Abstract

**Background:** The study aims to illustrate the wide spectrum of benign hyperplastic, metaplastic, inflammatory, infectious, and reactive lesions that masquerade as malignancy. This is a retrospective case series study of six patients who presented with clinical and imaging findings suggestive of malignancy and were later diagnosed with benign conditions on detailed pathological examination. The pathologist's awareness of the vast array of benign lesions mimickers is important for the systematic approach to make a definitive diagnosis and avert a false-positive malignancy interpretation.

## INTRODUCTION

The clinical presentation of several benign lesions can mimic malignancy. Suspicious imaging studies may be part of the spectrum, making them indistinguishable from malignancy. Benign tumors that mimic malignancy include desmoid fibromatosis, hamartomas, pseudoangiomatous hyperplasia etc. Also, lesions like tuberculosis, fat necrosis, sclerosing adenosis, actinomycosis, endometriosis and stromal fibrosis may be misinterpreted as malignant tumors.<sup>[1]</sup> and require extensive surgical procedures. Definitive diagnosis of these lesions is essential to ensure accurate radiological and clinicopathological correlation, which is vital for formulating an appropriate clinical management plan.

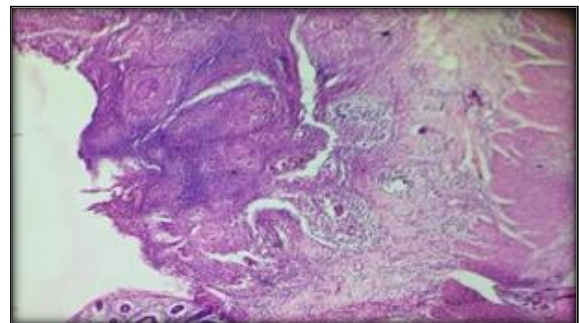
## MATERIALS AND METHODS

This is a retrospective case series study of different cases reported at the Department of Pathology, Tirunelveli Medical College, between 2019 and 2021. Clinical records and imaging studies were obtained. The cases initially diagnosed as malignancy clinically were included in the study. In addition, the histopathological study of tissues from the lesion was done and analyzed.

## RESULTS

### Case -1

A 43-year-old female complained of abdominal pain for 3 months. The pain was not associated with menstruation. CT scan revealed a complex ovarian mass measuring 6x4x3 cm. CA 125 was elevated to 200 units/ml. The findings were suggestive of ovarian malignancy. The patient underwent laparoscopic removal of the mass, followed by histopathological examination. The mass was diagnosed to be Ovarian Endometriosis.

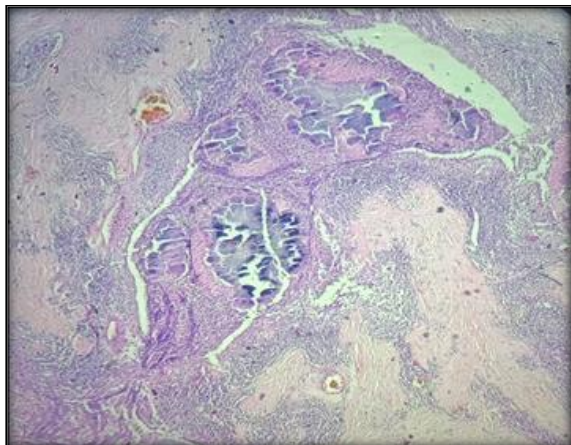


**Figure 1: Pancreatic Tuberculosis - Caseating granuloma: typical epithelioid cell granuloma with central caseation, peripheral lymphocytes and Langhans type of giant cells. (H and E, 10 X)**

### Case -2

A 47-year-old female complained of abdominal pain, jaundice, weight loss, and appetite for 2 months. Ultrasonography and CT scan of the abdomen showed dilatation of the bile duct and an

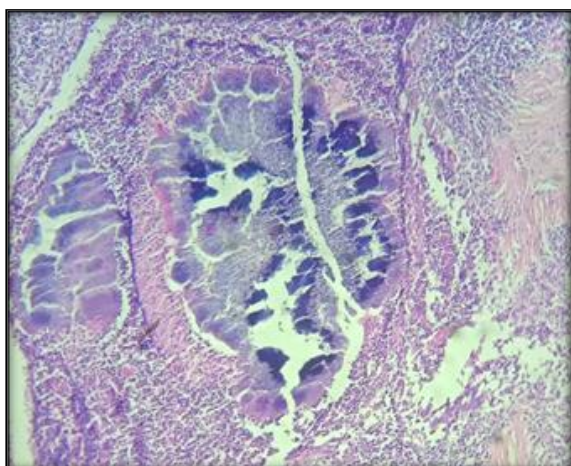
irregular, hypodense lesion measuring 3x2x2 cm in the head of the pancreas. Thus, preoperative imaging studies and laboratory findings suggested a resectable pancreatic head neoplasm. The patient underwent surgical removal of the mass, followed by a histopathological examination. The mass was diagnosed to be pancreatic tuberculosis.



**Figure 2: Ovarian Actinomycosis - Suppurative inflammation with colonies of actinomycosis (H and E, 10 X)**

#### Case -3

A 37-year-old male complained of painless swelling in the left cheek for 6 months with insidious onset and gradual progression. On examination, a swelling of size 5x3x2 cm was present in the left cheek. The swelling was hard in consistency. The swelling was removed by excision biopsy and reported initially in a private laboratory as mucoepidermoid carcinoma of the parotid. The biopsy slides were received for review at our institution. On detailed histopathological examination, it was diagnosed as Proliferating Trichilemmal tumor.



**Figure 3: Ovarian Actinomycosis - Suppurative inflammation with colonies of actinomycosis (H and E, 40 X)**

#### Case -4

A 19-year-old female complained of swelling in the right shoulder for 1 year. On examination, the right shoulder presented with an ulceroproliferative, hard swelling of 8x5x4 cm with restricted mobility. A biopsy from the swelling was reported in a private laboratory as ulcerated squamous cell carcinoma. Wide local excision was done, and a histopathological examination revealed the diagnosis of Proliferating Trichilemmal tumor.

#### Case -5

A 46-year-old male complained of abdominal pain and mild fever for 1 month. On clinical examination, the spleen was mildly enlarged by 2 cm. Ultrasonography showed mild splenomegaly. Clinically the findings were suspicious of splenic lymphoma. The patient underwent laparotomy with the removal of the splenic lesion. Histopathological examination revealed a greyish-yellow necrotic lesion in the spleen measuring 3x3x2 cm and was diagnosed as an Actinomycotic abscess.

#### Case -6

A 44-year-old female complained of lower abdominal pain of 1-month duration. Ultrasonography of the abdomen revealed a hypoechoic lesion of size 5.8 x 5 cm in the right adnexa, suspicious of a broad ligament fibroid. In addition, an MRI abdomen raised the possibility of a right ovarian mass lesion. CA 125 level was found to be 245.2 IU/L. Primary cytoreduction was done, and the lesion was diagnosed on histopathological examination as Ovarian actinomycosis.

## DISCUSSION

#### Case 1

Endometriosis occurs predominantly in women of childbearing age. 25–29 years is the mean age at diagnosis, but it is greater in women with infertility than in pelvic pain. It is characterized by endometrial-like tissue composed of glands and stroma. Although they are implanted ectopically, these tissues present physiological and histopathological responses similar to endometrial tissue responses.<sup>[2]</sup> The most common sites involved are the ovaries, recto- and vesicovaginal septae, uterine ligaments, pelvic peritoneum, labia, cervix, and vagina, where they present as nodules, implants, or chocolate cysts. Malignant transformation of endometriosis may occur in 1% of affected women, with the most common site affected being the ovary.<sup>[3,4,5]</sup>

The most common presenting symptoms are dysmenorrhea, lower back pain that worsens during menstruation and dyspareunia. Infertility is also reported to be the presenting feature in many cases. Patients with endometriosis often have normal pelvic findings, and laparoscopy gives a definitive diagnosis. The radiological examination also aids in

diagnosis and may reveal cystic lesions. In our case, the patient presented with pain unrelated to menstruation and elevated CA-125 levels and imaging studies showed a complex ovarian mass suggestive of malignancy. On the contrary, the histopathological diagnosis was endometriosis of the ovary, which rarely presents as a complex ovarian mass like endometriomas. Hence careful pathological examination is warranted for an accurate diagnosis.

#### Case 2

Abdominal tuberculosis (TB) is the sixth most common extra-pulmonary tuberculosis. Other sites reported are lymphatic, miliary, genitourinary, meningeal, and TB bone and joint, with increased incidence in recent years. TB can infect any part of the gastrointestinal (GI) tract, such as the ileum, hepato-biliary system, peritoneum and anus.<sup>[6]</sup> The most common site affected is reported to be the ileum.<sup>[7,8]</sup> The mycobacterium enters the gastrointestinal tract through the hematogenous spread, direct spread from infected contiguous lymph nodes and fallopian tube Tuberculosis involving the pancreas is extremely rare. In most cases, it mimics pancreatic carcinoma. Patients with pancreatic tuberculosis may be asymptomatic initially and usually present with non-specific features such as an abscess or a mass involving local lymph nodes. Pancreatic tuberculosis can present with a wide range of Radiological imaging findings, such as cystic lesions, masses or abscesses. When the presentation is a mass lesion, in most cases, it mimics pancreatic carcinoma.<sup>[9]</sup> Our case had a similar presentation, mimicking carcinoma, which prompted laparotomy and surgical removal of the mass with a clinical suspicion of malignancy, later diagnosed on histopathology as pancreatic tuberculosis [Figure 1]. Most patients achieve a complete cure with standard antituberculous therapy; hence, accurate histopathological diagnosis is vital.

#### Case 3, 4

Proliferating trichilemmal tumor is a rare cutaneous adnexal neoplasm derived from the outer root sheath of a hair follicle. The characteristic histopathological findings are trichilemmal keratinization composed of compact amorphous keratinization of epithelial cells which cover the cyst wall and are without a granular layer.<sup>[10,11]</sup> Proliferating trichilemmal tumor commonly has benign behaviour and sometimes present a malignant course. Malignant proliferating trichilemmal tumor invades neighbouring tissues and is characterised by anaplasia and necrosis. On the other hand, malignant proliferating trichilemmal tumors are invasive and demonstrate aggressive behaviour. The mimicker is Squamous cell carcinoma, as both these tumors have similar morphological characteristics. Similarly, presentation in the parotid region with a hard swelling, as in our reported case, and squamoid cells on microscopy prompted a misdiagnosis of

mucoepidermoid carcinoma, which was later found on detailed histopathological examination to be Proliferating trichilemmal tumor.

#### Case 5, 6

Actinomycosis is caused by *Actinomyces* spp., anaerobic Gram-positive bacteria which normally colonize the oral cavity, digestive and genital tracts. Typical clinical presentations include cervicofacial actinomycosis, which follows a dental infection, Pulmonary actinomycosis in smokers, and pelvic actinomycosis in women with an intrauterine device. Atypical presentations of actinomycosis may mimic malignancy in various anatomical sites. Histopathology and bacterial culture are the cornerstones of diagnosis. Prolonged bacterial culture in anaerobic conditions is needed to identify the bacterium. The salient histopathological findings include prominent necrosis with yellowish sulfur granules and a filamentous Gram-positive fungal-like organism. Actinomycosis patients require high doses of penicillin G or amoxicillin to facilitate drug penetration for a long duration (6- to 12 months). The duration of antimicrobial therapy could be reduced to 3 months in patients with optimal surgical resection. Our patients presented with mass lesions suspicious of malignancy warranting surgical removal and later diagnosed as actinomycosis on histopathology, which required appropriate antibacterial treatment [Figure 2,3].

## CONCLUSION

An incorrect diagnosis may lead to unnecessary patient anxiety, small biopsy and surgery. The increasing use of Imaging studies such as CT and MRI to diagnose various cases in different clinical settings will increase the recognition of non-neoplastic lesions that simulate malignancies. Some of these lesions are benign and self-limited, while others can be locally aggressive and require definitive treatment. It is important to understand that most of these lesions have salient imaging appearances that aid in differentiating them from malignancy. In addition, presenting signs and symptoms have a major role in narrowing down the diagnosis. Therefore, before raising suspicion of malignancy, it is prudent for the histopathologist to consider the various benign patterns and presentations that can simulate a malignancy. Knowledge of these patterns on routine light microscopy, added with ancillary techniques such as immunohistochemistry, will lead to a definitive diagnosis and avert a false-positive malignancy interpretation.

## REFERENCES

1. Philips S, Restrepo CS, Chintapalli K. Mimics of neoplasia: Common lesions and findings misdiagnosed as malignancy. *Appl Radiol* 2012;5-14.
2. Heaps JM, Nieberg RK, Berek JS. Malignant neoplasms arise in endometriosis. *Obstet Gynecol* 1990; 75:1023-8.

3. Zwierzchowska A, Panek G, Gajewska M, Barcz E. Endometriotic lesions mimicking advanced ovarian cancer - A case report and a literature review. *Eur J Gynaecol Oncol* 2017; 38:303-7.
4. Matias-Guiu X, Stewart CJR. Endometriosis-associated ovarian neoplasia. *Pathology* 2018; 50:190-204.
5. Zondervan KT, Becker CM, Koga K, Missmer SA, Taylor RN, Viganò P. Endometriosis. *Nat Rev Dis Primers*. 2018; 4:9.
6. Kandola P, Meena LS. Extra pulmonary tuberculosis: Overview, manifestations, diagnostic and treatment techniques. *Adv Mater Rev*. 2014; 1:13-9.
7. Park, K. *Park's Textbook of Preventive and Social Medicine*. 19th Edition, M/S Banarsidas Bhanot Publishers, Jabalpur. - references - scientific research publishing. Scirp.org n.d. 2007. p. 768.
8. Kapoor VK. Abdominal tuberculosis: the Indian contribution. *Indian J Gastroenterol* 1998; 17:141-7.
9. Bisht M, Agrawal R, Mohan N, Kumar P. Clinicopathological spectrum of extra-pulmonary tuberculosis in a tertiary care centre of Western Uttar Pradesh. *Ind J Pathol Oncol* 2021; 3:721-6.
10. Jones EW. Proliferating epidermoid cysts. *Arch Dermatol* 1966; 94:11-9.
11. Satyaprakash AK, Sheehan DJ, Sangüeza OP. Proliferating trichilemmal tumors: a review of the literature. *Dermatol Surg* 2007; 33:1102-8.