

BOWEL AND MESENTERIC INJURY AFTER BLUNT TRAUMA: CT FINDINGS AND SURGICAL IMPLICATIONS

Ashwin Kumar A¹, Mohideen Ashraf A², Abirami. K³, Dravid. N⁴, K. ShivaShankar⁵

Received : 18/12/2022

Received in revised form : 25/01/2023

Accepted : 06/02/2023

Keywords:

Computed tomography, mesenteric and bowel injury, laparotomy, bowel wall thickening, mesenteric bleeding, mesenteric hematoma.

Corresponding Author:

Dr. Ashwin Kumar A

Email: ashgilli@gmail.com

DOI: 10.47009/jamp.2023.5.2.41

Source of Support: Nil,

Conflict of Interest: None declared

Int J Acad Med Pharm
2023; 5 (2); 198-202



¹Assistant Professor, Department of Radiodiagnosis, Barnard Institute of Radiology, Madras Medical College, Tamilnadu, India.

²Assistant Professor, Department of Radiodiagnosis, Barnard Institute of Radiology, Madras Medical College, Tamilnadu, India.

³Assistant Professor, Department of Radiodiagnosis, Barnard Institute of Radiology, Madras Medical College, Tamilnadu, India

⁴Postgraduate, Department of Radiodiagnosis, Barnard Institute of Radiology, Madras Medical College, Tamilnadu, India.

⁵Professor, Department of Radiodiagnosis, Barnard Institute of Radiology, Madras Medical College, Tamilnadu, India

Abstract

Background: This study aimed to identify the range of CT findings of mesenteric and bowel injury (BBMI). To compare surgical findings with CT findings of BBMI and to evaluate the ability of CT to identify which patients with BBMI require laparotomy. **Materials and Methods:** Five patients included in the current study admitted to general surgery referred to department of Barnard Institute of Radiology during a period of December 1, 2022 to December 20, 2022. All patients with a surgically confirmed BBMI who had abdominal CT done before surgery were included in the study. Whether they had undergone medical treatment or surgery, patients with CT findings of BBMI during the study period were included. **Result:** Five patients fulfilling the study criteria underwent laparotomy. No significant inconsistencies were found between the retrospective CT review performed with and without knowledge of the surgical findings. Active extravasation of IV contrast material, presence and site of extra-luminal air collection and intestinal wall thickening coupled with mesenteric findings were three CT findings specific to patients whose injuries, in the opinion of the surgical team, warranted surgical correction. The nature and clinical significance of the mesenteric damage and bowel damage did not correspond well with physical findings. **Conclusion:** The CT verdict of mesenteric bleeding or bowel wall thickening, site and presence of extra-luminal free air, findings of hollow viscus injuries linked with mesenteric hematoma or infiltration in a patient with blunt trauma specifies a high possibility of a mesenteric or bowel injury demanding surgery. The outcome of focal mesenteric hematoma or infiltration without adjacent bowel wall thickening is general. It can occur in mesenteric or bowel lesions that need surgery and those that do not.

INTRODUCTION

Blunt bowel and mesenteric injuries (BBMI) are infrequent injuries with high morbidity and mortality, and Only 1-5% of abrupt abdominal traumas result in BBMI. Since delayed identification of BBMI may cause major consequences and fatality, accurate diagnosis is extremely important. In patients with acute abdominal trauma, it can be challenging to make an early diagnosis of isolated BBMI since the clinically evident signs and symptoms of peritonitis brought on by perforation can take a long time to appear, delaying diagnosis. After surgical repair,

intraabdominal complications like abscess, sepsis, and even mortality might occur as a result of a delay in detection.^[1]

The mesentery is a substantial cause of morbidity and mortality from blunt abdominal injuries, although very uncommon. The best results come from early identification and surgical intervention when necessary.^[1] According to earlier research, abdominal CT using oral contrast material effectively identifies BBMI.^[2-6] Broadly speaking, a CT scan indicates full-thickness intestinal wall damage, like pneumoperitoneum, without another known source. Oral contrast extravasation or direct observation of

the damaged intestinal wall shows an unmistakable need for surgery. It has been proposed that further signs of bowel injury, such as focal intestinal wall thickening or gut wall hematoma, call for attentive monitoring but may not require prompt surgical investigation in the absence of other clear signs.^[3] Uncertainty surrounds the clinical relevance of a mesentery injury that is isolated and unaccompanied by intestinal damage, as is the best way to handle this injury when it is discovered on a CT scan. Patients with concurrent full-thickness bowel injury who would unmistakably need surgical care, mesenteric injury or not, have been included in previous CT studies of mesenteric injury. However, small sample sizes or the inclusion of CT scans taken after diagnostic peritoneal lavage, which reduces CT sensitivity for detecting mesenteric damage, limits other CT studies of isolated mesenteric injuries.^[7,8] Our study aimed to identify the range of CT results associated with BBMI, correlate those findings to actual surgical observations, and establish whether CT findings can be useful in predicting which patients with BBMI require laparotomy versus clinical observation.

MATERIALS AND METHODS

All patients in this study were referred to department of Barnard Institute of Radiology during a period of December 1, 2022 to December 20, 2022. All patients with a surgically confirmed mesenteric injury and hollow viscus injury who had abdominal CT done before surgery were included in the study. Whether they had undergone medical treatment or surgery, patients with CT findings of mesenteric and hollow viscus damage during the study period were included. Surgical records were examined to determine whether hollow viscus resection was necessary after the surgery and whether intestinal ischemia or perforation existed. A review of the surgical records was also done to look for any indications of active mesenteric bleeding or mesentery tears that needed to be repaired. They had CT scans.

The sensitivity of CT for detecting mesenteric and hollow viscus injuries and the usefulness of CT findings for differentiating mesenteric and hollow viscus injuries requiring immediate surgical intervention from less serious injuries (partial thickness laceration, focal contusion, stable hematoma, or serosal tear with viable bowel) that may be observed were determined by correlating CT observations with surgical findings.

RESULTS

Case 1

A 16-year-old male presented to the emergency department with a history of fall from height, following which he developed severe abdominal pain. On examination, there was mild tachycardia and guarding. CT trauma series was taken, which showed

no significant abnormality. CT abdomen revealed pneumoperitoneum with free air in the right subdiaphragmatic region, prehepatic areas, and along the greater curvature of the stomach with few mesenteric air pockets. A mural defect was noted in the greater curvature of the stomach. There was no hemoperitoneum, solid organ injury, vascular injury, or portal vein gas. He was immediately taken for emergency laparotomy. A large laceration of about 3 cm was found in the greater curvature of the stomach, and repair was done.

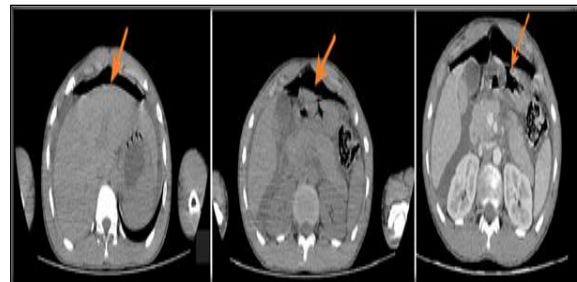


Figure 1: Image 1 shows pneumoperitoneum (arrow) in subdiaphragmatic and prehepatic areas. Image 2 shows defect in greater curvature of the stomach. Image 3 shows CECT(I.V.) of the same patient shows defect in greater curvature of the stomach (arrow)

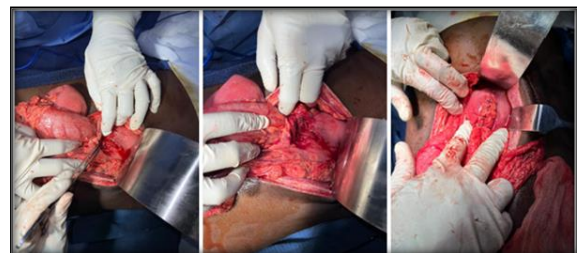

Figure 2: Images shows intra OP images of the laceration in the greater curvature and post repair

Case 2

A 31-year-old male presented to the emergency department following a road traffic accident; the victim was driving the car with seat belts fastened. A patient complained of severe abdomen pain. On examination, the patient had tachycardia, guarding, and rigidity. Abrasions were noted along the expected course of the seat belt. CT trauma series was taken given seat belt injury, which revealed pneumoperitoneum and jejunal transection and extravasation of bowel contents into the peritoneum with adjacent fat stranding. Free fluid also along the perihepatic area, bilateral paracolic gutters, and pelvis. CECT (i.v.) abdomen was done, which confirmed the complete jejunal transection. The patient was immediately taken up for emergency laparotomy, and resection of the transected segment along with jejuno jejunal anastomosis was done.

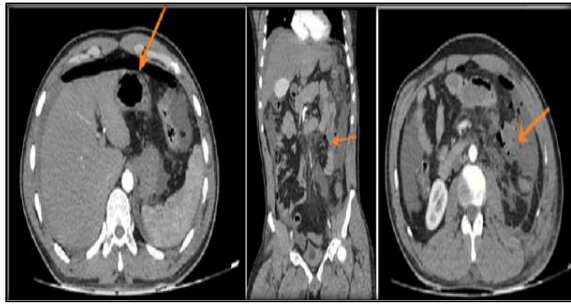


Figure 3: Image 1 shows CECT (i.v.) shows pneumoperitoneum (arrow). Image 2 and 3 shows CECET(i.v.) coronal and axial images show the complete jejunal transection with extravasation of bowel contents (arrow)

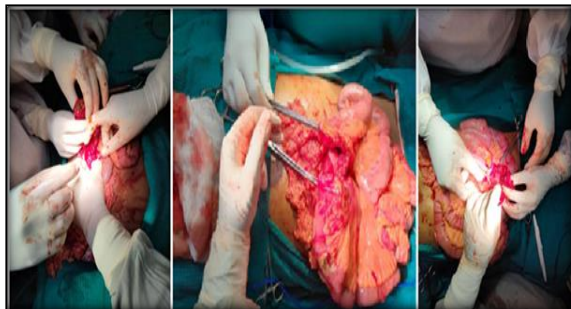


Figure 4: Image shows intra operative images of the jejunal transection

Case 3

A 22-year-old male presented to the emergency department with severe abdominal pain and distension following air pumping into his anus. On examination guarding and rigidity were present. Hollow viscus perforation was suspected. An X-ray chest was taken, which showed air under the diaphragm. X-ray abdomen erect and supine was taken, which revealed signs of pneumoperitoneum. CT abdomen was taken, which showed massive pneumoperitoneum. Proximal Sigmoid colon perforation was suspected. The patient was taken up for emergency laparotomy because of deteriorating vitals. The patient was found to have 2 perforations in the Sigmoid colon; resection of the perforated segment followed by Hartmann's procedure was done.

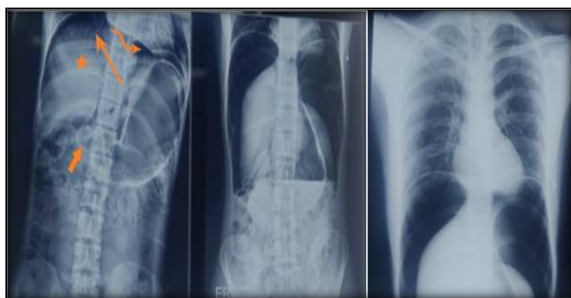

Figure 5: X ray abdomen (supine and erect) showing signs of pneumoperitoneum like air under diaphragm, Rigler's sign, Lucent liver sign, Cupola sign and X ray chest showing air under diaphragm

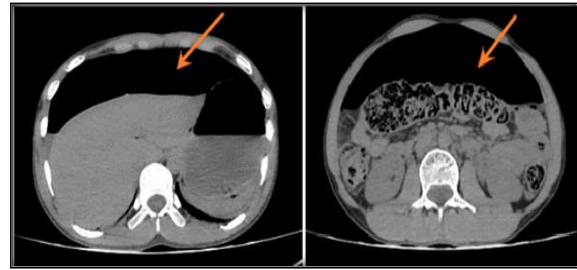


Figure 6: CT pain abdomen axial section showing massive pneumoperitoneum (arrow)

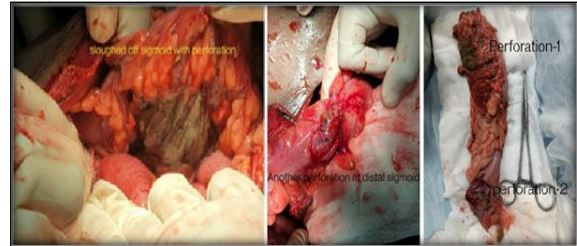


Figure 7: Image shows intraoperative images of the Sigmoid colon perforations

Case 4

A 60-year-old male presented to the emergency room with severe abdominal pain for the past 4 hours following a road traffic accident. On examination, the patient had guarding, and rigidity, and the vitals were unstable in the form of tachycardia and hypotension. CT trauma series was taken, which revealed a few rib fractures in the CT chest, and the abdomen study showed few mesenteric air pockets adjacent to the distal ileum with surrounding fat stranding and minimal free fluid. The patient was given a possible diagnosis of ileal perforation and was taken up for emergency laparotomy. Intraoperatively, the patient was found to have distal ileal perforation and peritonitis; resection of the perforated segment was followed by ileostomy.

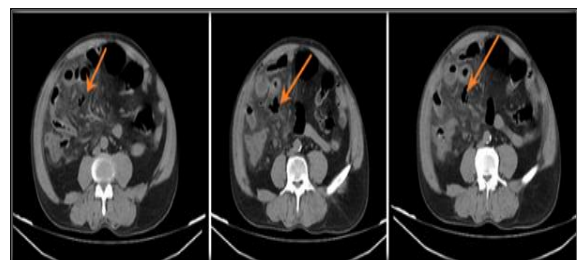


Figure 8: Image show extraluminal air pockets near distal ileum with adjacent mesenteric fat stranding

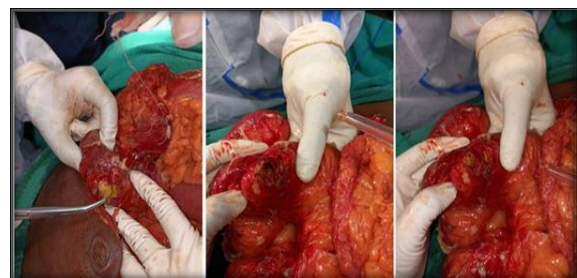

Figure 9: Image shows the intraoperative images of the ileal perforation of the same patient

Case 5

A 48 years old male presented to the emergency department with a history of a road traffic accident involving a hit by a two-wheeler, following which he developed severe abdominal pain. The patient's vitals were stable. On examination, the patient had guarding. The patient had severe scoliosis. Bowel injury was suspected, and CT abdomen pain and contrast were taken, revealing retroperitoneal free air pockets around the D2/D3 segments of the duodenum and the anterior pararenal space. The free air pockets were noted tracking down to the pelvis along with minimal free fluid. The patient was suspected of having D2/D3 perforation. Still, the patient was not taken up for immediate laparotomy due to high morbidity for this patient, and the patient had improved symptomatically within a few hours. The next morning patient was advised to undergo oral contrast to look for extravasation, which revealed no active contrast extravasation. The patient was diagnosed with concealed D2/D3 perforation and managed conservatively.

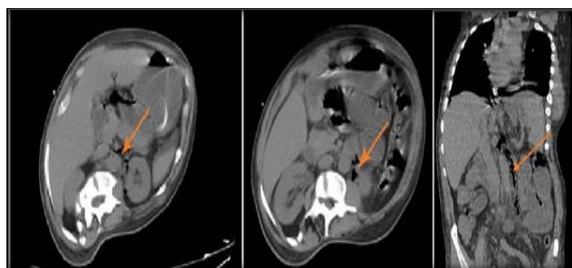


Figure 10: Image shows CECT image of the same patient

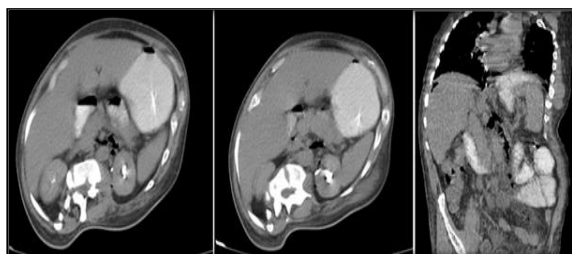


Figure 11 Image show CECT (oral) axial and coronal images of the same patient, revealing no contrast extravasation

DISCUSSION

It has been suggested that CT may be utilised to distinguish between bowel and mesentery lesions that need surgical intervention and those that can be treated non-operatively.^[1,2] In evaluating CT findings, intraperitoneal free air, mesenteric air, intestine wall thickness, enhanced bowel wall contrast enhancement, bowel wall defect, and mesenteric hematoma are all linked with high accuracy, specificity, and positive predictive values. Even though it can be exceedingly difficult to detect intraperitoneal free air in the aftermath of trauma, such situations necessitate quick surgical action. In

20% to 55% of patients, intraperitoneal or retroperitoneal extraluminal air is a relatively specific indicator of bowel injury.^[4-8]

The anterior abdominal wall becomes deeply accumulated with gas following bowel rupture. Subcutaneous emphysema that spreads into the extraperitoneal region and results in pseudo pneumoperitoneum can be a diagnostic stumbling block at this site.^[9] The Porta hepatis, mesentery or mesenteric veins are additional locations where excess luminal air may gather.^[10] The use of broad window settings in CT scans increases the identification of small amounts of free air, which are frequently missed.^[11]

Extraluminal contrast is a particular indicator of bowel rupture. The sensitivity, however, is modest and is partly ascribed to scanning early, before oral contrast reaches and enlarges the site of intestinal perforation, or because extraluminal contrast is used in tiny amounts by bigger intraperitoneal free fluid. Extra luminal contrast from intraperitoneal bladder rupture detected in delayed pictures after bladder filling may produce a false positive result. Several studies claim that only CT is unreliable in identifying BBMI, despite being the best non-invasive modality currently available.^[12-14] In 35% of patients, BBMI were not originally diagnosed, according to Sharma et al.^[13] According to Bhagvan et al., 13% of small intestinal injuries resulted in erroneous negative CT results.^[14] Any unexplained and generic CT finding for BBMI requires rapid investigation due to the likelihood of false negatives. The presence of symptoms such as neighbouring bowel thickening or mesenteric stranding increases the likelihood of correctly detecting BBMI.^[1]

The diagnostic precision of CT is improved by expertise and knowledge of BBMI findings on CT scans. However, BBMI diagnosis is challenging, and CT cannot be the sole diagnostic method. For proper care, close clinical observation, monitoring, and surgical competence are essential.^[1] There are some limitations to this study. Only patients with blunt abdominal trauma were assessed; the study was retrospective; patients from a particular time period were analysed. Additionally, only patients who had undergone surgery were included in the study since the CT findings were contrasted with the results of the operation. Additionally, a small number of surgically confirmed BBMI cases were included in this investigation.

CONCLUSION

The chance of a mesentery-gut injury needing surgery is highly likely, given the CT findings of mesenteric bleeding, presence of extra-luminal free air and bowel wall thickening associated with mesenteric hematoma or infiltration in the blunt trauma victim. It is non-specific to identify a focal mesenteric hematoma or infiltration without an adjacent bowel wall thickening, and it can happen

with both surgically operable and non-operable mesentery-bowel diseases. Careful clinical observation and follow-up studies, such as delayed repeat abdominal CT, laparoscopy, or perhaps exploration, are advised in patients who do not. We think using oral contrast material to render the small intestinal lumen opaque, finding mesenteric lesions, and presence of bowel wall thickening together with presence and site of extraluminal air makes the diagnosis easier and also aids in predicting the site of injury.

REFERENCES

1. Polat AV, Aydın R, Nural MS, Gul SB, Kamali Polat A, Aslan K. Bowel and mesenteric injury in blunt trauma: diagnostic efficiency and importance of experience in using multidetector computed tomography. *Ulus Travma Acil Cerrahi Derg* 2014;20:417-22.
2. Rizzo MJ, Federle MP, Griffiths BG. Bowel and mesenteric injury following blunt abdominal trauma: evaluation with CT. *Radiology* 1989;173:143-8.
3. Donohue JH, Federle MP, Griffiths BG, Trunkey DD. Computed tomography in the diagnosis of blunt intestinal and mesenteric injuries. *J Trauma* 1987;27:11-7.
4. Gay SB, Siström CL. Computed tomographic evaluation of blunt abdominal trauma. *Radiol Clin North Am* 1992;30:367-88.
5. Orwig D, Federle MP. Localized clotted blood as evidence of visceral trauma on CT: the sentinel clot sign. *AJR Am J Roentgenol* 1989;153:747-9.
6. Nghiem HV, Jeffrey RB Jr, Mindelzun RE. CT of blunt trauma to the bowel and mesentery. *AJR Am J Roentgenol* 1993;160:53-8.
7. Ceraldi CM, Waxman K. Computerized tomography as an indicator of isolated mesenteric injury. A comparison with peritoneal lavage. *Am Surg* 1990;56:806-10.
8. Nolan BW, Gabram SG, Schwartz RJ, Jacobs LM. Mesenteric injury from blunt abdominal trauma. *Am Surg* 1995;61:501-6.
9. Levine CD, Patel UJ, Wachsberg RH, Simmons MZ, Baker SR, Cho KC. CT in patients with blunt abdominal trauma: clinical significance of intraperitoneal fluid detected on a scan with otherwise normal findings. *AJR Am J Roentgenol* 1995;164:1381-5.
10. Shanmuganathan K, Mirvis SE, Sover ER. Value of contrast-enhanced CT in detecting active hemorrhage in patients with blunt abdominal or pelvic trauma. *AJR Am J Roentgenol* 1993;161:65-9.
11. Carey JE, Koo R, Miller R, Stein M. Laparoscopy and thoracoscopy in evaluation of abdominal trauma. *Am Surg* 1995;61:92-5.
12. Scaglione M, de Lutio di Castelguidone E, Scialpi M, Merola S, Diettrich AI, Lombardo P, et al. Blunt trauma to the gastrointestinal tract and mesentery: is there a role for helical CT in the decision-making process? *Eur J Radiol* 2004; 50:67-73.
13. Sharma OP, Oswanski MF, Singer D, Kenney B. The role of computed tomography in diagnosing blunt intestinal and mesenteric trauma (BIMT). *J Emerg Med* 2004; 27:55-67.
14. Bhagvan S, Turai M, Holden A, Ng A, Civil I. Predicting hollow viscus injury in blunt abdominal trauma with computed tomography. *World J Surg* 2013; 37:123-6.