

## A COMPARATIVE STUDY OF OPTIMUM DEPTH OF TIP OF RIGHT INTERNAL JUGULAR VENOUS CATHETER CANNULATION BY LANDMARK AND ATRIAL ECG METHOD

M. Sukumaran<sup>1</sup>, A. Asghar Ali<sup>1</sup>, A. Joel<sup>3</sup>

<sup>1</sup>Assistant Professor, Department of Anaesthesiology, Tirunelveli Medical College, Tamilnadu, India.

<sup>2</sup>Junior Resident, Department of Anaesthesiology, Tirunelveli Medical College, Tamilnadu, India.

Received : 08/01/2023  
Received in revised form : 03/02/2023  
Accepted : 15/02/2023

**Keywords:**

Optimum depth of tip; Right internal jugular venous; Catheter cannulation; Landmark; Atrial ECG method.

Corresponding Author:

**Dr. A. Joel**

Email: joel1751993@gmail.com

DOI: 10.47009/jamp.2023.5.2.31

Source of Support: Nil,  
Conflict of Interest: None declared

*Int J Acad Med Pharm*  
2023; 5 (2); 145-149



### Abstract

**Background:** Central venous access devices are used for short-term and long-term infusions of fluids, medications, and monitoring. This study aimed to compare landmark and atrial ECG methods for the correct position of the tip of the right internal jugular venous catheter (RIJVC) cannulation. **Materials and Methods:** This study was conducted in elective surgery operation theatre in Government Tirunelveli medical college, Tirunelveli, on 80 patients who were posted for elective surgery. Forty patients were cannulated using the landmark technique, and 40 were cannulated using intra-atrial ECG. The correct positioning of the catheter and complications in patients of both groups were reported. **Result:** Male predominance was observed in Group E 22 (55%) and Group L 24 (60%). In both groups, maximum patients were observed in the age group of 46 to 65 with a BMI of more than 25. The mean height and weight of patients were comparable in both groups. The mean insertion length of the catheter was reported to be 15.792 and 15.075 for groups E and L, respectively. In the landmark method, 80% were correctly positioned, and in the intra-atrial ECG method, 100% were correctly positioned. This difference was statistically significant, with a p-value of 0.0005. The complication was reported more in Landmark group patients than in ECG group patients. **Conclusion:** Intra-atrial electrocardiogram-guided central venous catheter tip placement was more accurate than the landmark technique. The complication was reported more in Landmark groups.

## INTRODUCTION

In operating rooms and intensive care units, central venous catheterization is frequently done for various reasons, including monitoring during cardiac surgery, during anaesthesia for congenital heart disease and other major surgical procedures in paediatric patients, fluid management, and as a route for medication.<sup>[1]</sup> It has been recommended that the central venous catheter (CVC) tip be positioned just above the superior vena cava-right atrium (SVC-RA) junction, parallel to SVC, to reduce the risk of serious complications like cardiac tamponade and perforation, pneumothorax, life-threatening arrhythmia, thrombosis, and tricuspid valve damage.<sup>[2-3]</sup> The carina is suggested as a helpful target level for the CVC tip location.<sup>[4]</sup> Therefore, it would be beneficial for the patient's safety to validate the precise CVC location before beginning the case using a straightforward bedside procedure and to anticipate the ideal CVC length accurately. This is crucial, especially for paediatric patients whose CVC

entry depth must be precisely measured.<sup>[5]</sup> A risky deep CVC insertion might result from the puncture site in the lower region of the neck, whereas a shallow insertion could result from a higher approach. According to patient characteristics, anatomical landmarks, electrocardiogram (ECG) guidance, and transoesophageal echocardiography guidance. Several techniques have been suggested to determine the correct central venous catheter insertion depth.<sup>[6-10]</sup> Our study examined the precision of CVC tip localization relative to the carina in postoperative chest X-ray (CXR) between the atrial and ECG and landmark approaches for CVC insertion.

## MATERIALS AND METHODS

This prospective randomized study was conducted in elective surgery operation theatre at Government Tirunelveli medical college, Tirunelveli, on 80 patients who were posted for elective surgery. Forty patients of both sexes were randomly allotted for the Intra-atrial electrocardiogram method (group E), and

forty patients of both sexes were allocated for the external landmark method (group L). Both groups' weights and heights of patients are measured before the procedure.

**Group E (Intraatrial electrocardiogram)** Patients in this group undergo central venous cannulation under the guidance of the intra-atrial electrocardiogram method.

**Group L (Landmark group)** Patients in this group undergo central venous cannulation with the help of external landmarks.

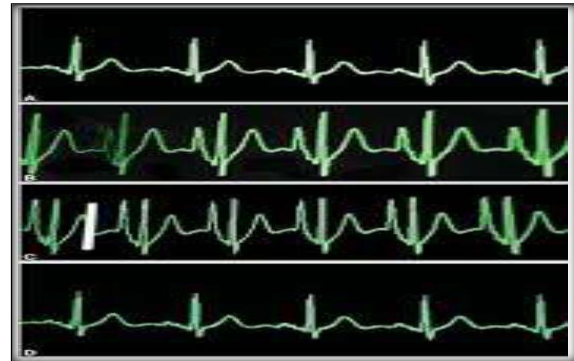**Inclusion Criteria**

Patients of either sex ageing from 18 years to 80 years within ASA physical status 1, 2, 3, and patients who have given valid informant consent were included in our study

**Exclusion Criteria**

Patients with more than two attempts at vein puncture, congestive heart failure, arrhythmias and previous history of arrhythmias, patients with pacemaker-driven rhythm, local infection, abnormal coagulation profile and pregnant women were excluded. Patients were evaluated for previous history of illness, other medical diseases, surgical history, central venous cannulation, and arrhythmias. Physical examination like general conditions of the patient, Vital signs, examination of the cardiovascular system, respiratory system, central nervous system and Airway assessment carried out of all patients. Further, the patient's complete hemogram, bleeding time, clotting time, chest x-ray and electrocardiogram were also studied. Patients who satisfied the inclusion criteria have explained the nature of the study and procedure. Written informed consent was obtained from all the patients included in the study. A basic weight and height measurement was taken before the procedure. The insertion point was the same in both internal jugular venous cannulation groups. It was a triangle formed by the two heads of the sternocleidomastoid at the level of the cricoid cartilage. Standard monitors like a pulse oximeter and electrocardiogram were connected. For internal jugular vein cannulation, the patient was put in a head-down position (Trendelenburg Position 30 degrees and the head turned to the left 45 degrees approximately. Neck extension was achieved by a small towel placed under the shoulders. In both the groups, after successful puncture of the right internal jugular vein (IJV), a 20 cm triple lumen Central venous catheter (Certofix® trio 16G, B. Braun Melsungen, Germany) was inserted over 50 cm guide wire using the Seldinger technique. Intra-atrial ECG (Group E): In Group E, the guide wire was withdrawn through the catheter until a mark on the guide wire indicated the tip to be exactly positioned at the tip of the catheter. A connection between the guide wire and the ECG adapter (Certodyn® - Universal adapter, B. Braun Melsungen, was established by connecting the red reference electrode to a universal adapter equipped with a switching function on the right thoracic side to record a modified lead II. The yellow electrode was placed on the left shoulder, and the

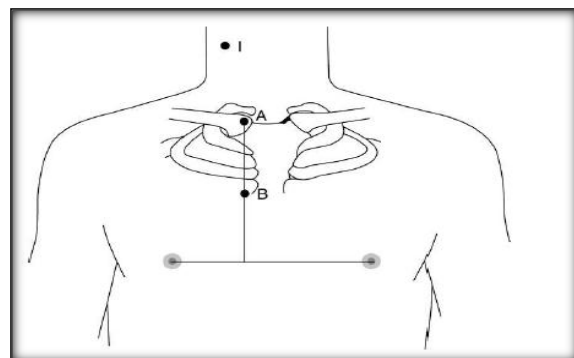
neutral green electrode was placed on the lower left chest. By turning the switch off the universal adapter, intra-atrial ECG could be recorded while advancing the guide wire along with the catheter, and the configuration of the P wave was seen on the ECG monitor. Gradually the height of the P wave increased, and it became equal to or more in amplitude than the R wave. On further advancement, the P wave became bifid, but at this point, the catheter and guide wire were immediately withdrawn until the P wave became the normal configuration. The Central venous catheter was fixed with stitches.



**Figure 1: The first line of the electrocardiogram shows a normal p wave (A) Second one shows p atrial (B-D)**

**External landmark group (Group L)**

In this patient's incision point was marked as (I). A horizontal line was drawn between two nipples. The right sternoclavicular joint was marked as A. Midpoint between the right sternoclavicular joint, and an inter-nipple line was marked as B Distance between Points I and B was called catheter length. The distance between Points I and B was called catheter length [Figure 2].



**Figure 2: Patients incision point marked**

Postoperative bedside chest X-Ray was taken for both groups. All the postoperative chest X-rays were done, and the radiologist read the position of the central venous catheter. In our study, the carina was taken as the landmark for identification of the superior vena cava right atrial junction (SVCRA junction). Suppose the position of the catheter was grossly abnormal. In that case, we try to redirect the catheter in our post anaesthesia care unit provided if the patient's clinical condition requires the catheter

for more than 48hrs. Otherwise, we remove the catheter within 24hrs.

**Parameters observed in Group L patients**  
 Accuracy of placement in the SVC- RA junction. Insertion length based on the anatomical landmark technique, intra-atrial electrocardiogram and Peres formula. Time was taken for catheter placement. Position of the catheter in postoperative chest X-Ray. Complications, if any, due to catheter malposition  
 Data were entered in Microsoft Excel, and analyses were done using the statistical package for social sciences (SPSS) for windows software. To find an association between two categorical variables chi-square test was used. The Pearson correlation coefficient was used to find the correlation coefficient for insertion length. The level of significance was set at 0.05.

## RESULTS

The present prospective randomized study was performed on 80 patients of either sex, aged 18 to 80, within ASA grading 1, 2 and 3. Forty patients of both sexes were randomly allotted for the Intra-atrial electrocardiogram method (group E), and forty patients of both sexes were allocated for the external landmark method (group L). Male predominance was observed in Group E 22 (55%) and Group L 24 (60%). In both groups, maximum patients were observed in the age group of 46 to 65 with a BMI of more than 25. The mean height and weight of patients were comparable in both groups. The mean insertion length of the catheter was reported to be 15.792 and 15.075 for groups E and L, respectively [Table 1].

**Table 1: Demographic variables of patients in both groups**

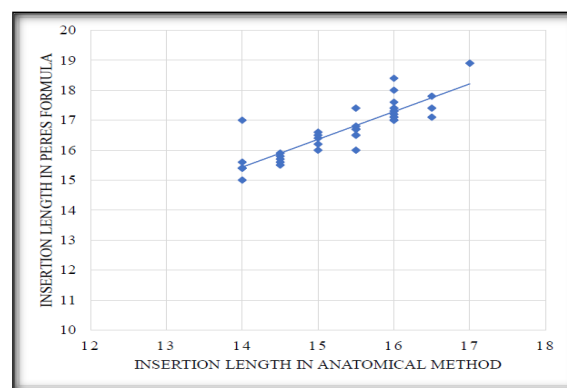
Variables		Group E (ECG Group)	Group L (Landmark Group)
Gender	Male	22 (55%)	24 (60%)
	Female	18 (45%)	16 (40%)
Age Group	22- 45 years	14 (35%)	12 (30%)
	46 - 65 years	19 (47.5%)	24 (60%)
	>65 years	7 (17.5%)	4 (10%)
BMI	18 - 25	16 (40%)	35 (44%)
	>25	24 (60%)	45 (56%)
Mean height cm ± SD		163.5 ± 8.45	166.9 ± 8.68
Mean Weight Kg± SD		70.5 ± 13.08	72.7 ± 13.25
Mean Insertion length cm± SD		15.075 ± 0.916	15.792 ± 0.882

The maximum number of patients were reported with catheter positioning at SVC-RA in both groups. In the intra-arterial ECG method, all 100% were positioned in SVC-RA. In the anatomical landmark technique (Group L), 80% were correctly positioned, whereas in the Intra-arterial ECG method, 100% were correctly positioned. This difference was statistically significant, with a P value of 0.005.

**Table 2: Observation of positioning of catheter and complications among both methods**

		Anatomical landmark method (n=40)	Intra-arterial ECG Method (n=40)	Total (n=80)	P-value
Position of catheter	High SVC	5 (12.5%)	0	5 (6.2%)	0.005
	Right atrium	3 (7.5%)	0	3 (3.8%)	
	SVC - RA	32 (80%)	40 (100%)	72 (90%)	
Complication	Nil Complications	37 (92.5%)	40 (100%)	77 (96.2%)	0.241
	Tachycardia	3 (7.5%)	0 (0%)	3 (3.8%)	

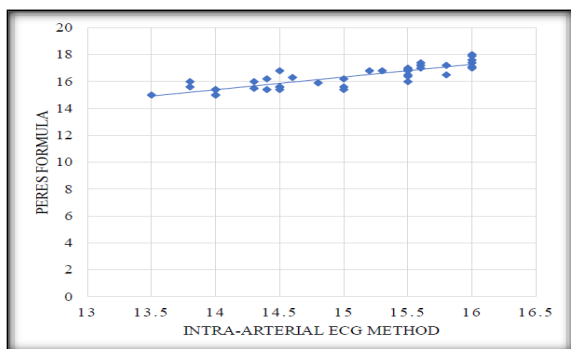
Among the anatomical landmark method, 7.5% had complications of Tachycardia, and 92.5% had no complications. In the intra-arterial ECG method (Group E), all 100% had no complications. In the anatomical landmark technique (Group L), 92.5% had no complications, and in the Intra-arterial ECG method, 100% had no complications. This difference was not statistically significant, with a P value of 0.24. The Pearson correlation coefficient for insertion length in the anatomical landmark method with the Peres formula is 0.590. This shows a 59% correlation of insertion length between both, which is statistically significant with  $P < 0.001$  [Figure 1].



**Figure 1: Correlation of insertion length in anatomical landmark method with Peres formula**

The Pearson correlation coefficient for insertion length in the Intra-arterial ECG method with the Peres formula is 0.700. This shows a 70% correlation

of insertion length between both, which is statistically significant with  $P < 0.001$  [Figure 2].



**Figure 2: Correlation of insertion length in Intra-arterial ECG method with Peres formula**

## DISCUSSION

The typical clinical procedure for measuring central venous pressure involves cannulating a central vein, which is also done for various other treatments. Since it was first used in clinical practice, anaesthesiologists have chosen percutaneous puncture of the right internal jugular vein (IJV) for central venous cannulation.<sup>[11-12]</sup> The IJV's stable, predictable anatomic placement, the presence of easily discernible and palpable surface markers, and the SVC's short, direct course are all factors in favour of this choice. During the majority of surgical operations, an IJV catheter is easily accessible and has a 90–99% success rate of being successfully implanted.<sup>[13]</sup> Male predominance was observed in Group E 22 (55%) and Group L 24 (60%). In both groups, maximum patients were observed in the age group of 46 to 65 with a BMI of more than 25. The mean height (Group E: 163.5 cm; Group L: 166.9 cm) and weight (Group E: 70.5 Kg; Group L: 72.7 Kg) of patients were comparable in both groups. Joshi et al., in their study, reported male predominance with a mean age of 58-59 years and a mean weight of 55-56 kg.<sup>[14]</sup> Whereas the mean height reported, was 157.96cm for the ECG group and 158.84cm for the Landmark group. These observations followed our study results. The mean insertion length of the catheter was reported to be 15.792 cm and 15.075cm for groups E and L, respectively. The Pearson correlation coefficient for insertion length in the anatomical landmark method with the Peres formula is 0.590. In contrast, in the ECG method, it was 0.7, and the effect was statistically significant ( $p < 0.05$ ) in both groups. Chalkiadis et al. also reported similar findings in their investigation.<sup>[15]</sup> Joshi et al. also reported 12.24 cm in ECG group patients and 15.88 cm in Landmark group patients, which is also close to our study observations.<sup>[14]</sup> In the intra-arterial ECG method, all 100% of patients were positioned correctly at SVC-RA, whereas in the anatomical landmark technique (Group L), 80% were correctly positioned. This difference was statistically significant, with a p-value of 0.005. In the present

study, we took a post-procedure chest x-ray for all patients to ascertain the position of the central venous catheter. In the intra-atrial electrocardiogram group, when we confirmed the position of the central venous catheter in the SVC-RA junction by monitoring p wave morphology in the monitor, 40 of 40 patients were accurately placed in the superior vena cava-right atrial junction. In the landmark group, 32 of 40 patients were correctly positioned (about 85%). 3 of the 40 patients were positioned in the right atrium, and 5 of the 40 were positioned in the superior vena cava. In a prospective, controlled, randomized trial comparing ECG guidance to conventional placement, Francis et al. reported a significantly higher success rate (96% v/s 59%) using a continuous column of normal saline for ECG-guided CVC placement.<sup>[16]</sup> Gebhard et al. reported 96% correct positioning in group ECG and 76% in group non-ECG.<sup>[17]</sup> In the present study, the average difference in distance measured by central venous catheter placement by intra-atrial electrocardiogram guidance with that of external anatomical landmark technique was found to be + 0.717cm with a mode of 1 cm difference. Chu et al., in their study, all the patients were adults undergoing surgery for malignancy and had only central venous catheters inserted via the SVCs.<sup>[18]</sup> The average difference in distance measured between TEE guidance and anatomical landmark technique was around +2 cm. But in their study, they used the distance between the insertion point and a point of 5cm below the manubriosternal junction was used as the initial catheter length. In their study, they adjusted the catheter length after imaging it with TEE, but we corrected it only when it was grossly abnormal. Among the anatomical landmark method, 7.5% had complications of Tachycardia, and 92.5% had no complications. In the intra-arterial ECG method (Group E), all 100% had no complications. A similar previous study carried out by Lee et al. did not show statistically significant differences in the complications ( $P = 0.162$ ) between ECG and landmark-guided technique.<sup>[19]</sup>

## CONCLUSION

Intra atrial electrocardiogram guided central venous catheter tip placement was more accurate than landmark technique. In this study intra atrial electrocardiogram guided technique was more efficient than the landmark method. Intra atrial electrocardiogram should be routinely used during central venous cannulation in all patients to avoid catheter related fatal complications. We should make the best use of the existing reliable technology for ensuring patient safety, hence routine identification of central venous catheter tip with intra atrial electrocardiogram has to be done if facility is available.

## REFERENCES

1. Collier PE, Blocker SH, Graff DM, Doyle P. Cardiac tamponade from central venous catheters. *Am J Surg* 1998; 176:212-4.
2. Kalen V, Medige TA, Rinsky LA. Pericardial tamponade secondary to perforation by central venous catheters in orthopaedic patients. *J Bone Joint Surg Am* 1991; 73:1503-6.
3. Booth SA, Norton B, Mulvey DA. Central venous catheterization and fatal cardiac tamponade. *Br J Anaesth* 2001; 87:298-302.
4. Yoon SZ, Shin JH, Hahn S, Oh AY, Kim HS, Kim SD, et al. Usefulness of the carina as a radiographic landmark for central venous catheter placement in paediatric patients. *Br J Anaesth* 2005; 95:514-7.
5. Stonelake PA, Bodenham AR. The carina as a radiological landmark for the central venous catheter tip position. *Br J Anaesth* 2006; 96:335-40.
6. Andropoulos DB, Bent ST, Skjonsby B, Stayer SA. The optimal length of insertion of central venous catheters for pediatric patients. *Anesth Analg* 2001; 93:883-6.
7. Yoon SZ, Shin TJ, Kim HS, Lee J, Kim CS, Kim SD, et al. Depth of a central venous catheter tip: Length of insertion guideline for pediatric patients. *Acta Anaesthesiol Scand* 2006; 50:355-7.
8. Ryu HG, Bahk JH, Kim JT, Lee JH. Bedside prediction of the central venous catheter insertion depth. *Br J Anaesth* 2007; 98:225-7.
9. Hayashi Y, Maruyama K, Takaki O, Yamauchi J, Ohnishi Y, Kuro M. Optimal placement of CVP catheter in paediatric cardiac patients. *Can J Anaesth* 1995; 42:479-82.
10. Chu KS, Hsu JH, Wang SS, Tang CS, Cheng KI, Wang CK, et al. Accurate central venous port-A catheter placement: Intravenous electrocardiography and surface landmark techniques compared by using transesophageal echocardiography. *Anesth Analg* 2004; 98:910-4.
11. Bailey PL, Glance LG, Eaton MP, Parshall B, McIntosh S. A survey of the use of ultrasound during central venous catheterization. *Anesth Analg* 2007; 104:491-7.
12. Sanford TJ Jr. Internal jugular vein cannulation versus subclavian vein cannulation. An anesthesiologist's view: The right internal jugular vein. *J Clin Monit* 1985; 1:58-61.
13. Oliver WC Jr., Nuttall GA, Beynen FM, Raimundo HS, Abenstein JP, Arnold JJ. The incidence of artery puncture with central venous cannulation using a modified technique for detection and prevention of arterial cannulation. *J Cardiothorac Vasc Anesth* 1997; 11:851-5.
14. Joshi AM, Bhosale GP, Parikh GP, Shah VR. Optimal positioning of right-sided internal jugular venous catheters: comparison of intra-atrial electrocardiography versus Peres' formula. *Indian J Crit Care Med* 2008; 12:10-4.
15. Chalkiadis GA, Goucke CR. Depth of central venous catheter insertion in adults: an audit and assessment of a technique to improve tip position. *Anaesth Intensive Care* 1998; 26:61-6.
16. Francis KR, Picard DL, Fajardo MA, Pizzi WF. Avoiding complications and decreasing costs of central venous catheter placement electrocardiographic guidance. *Surg Gynecol Obstet* 1992; 175:208-11.
17. Gebhard RE, Szmuk P, Pivalizza EG. The Accuracy of electrocardiogram controlled central line placement *Anesth Analg* 2007; 104:65-70.
18. Chu K-S, Hsu J-H, Wang S-S, Tang C-S, Cheng K-I, Wang C-K, et al. Accurate central venous port-A catheter placement: intravenous electrocardiography and surface landmark techniques compared using transesophageal echocardiography. *Anesth Analg* 2004; 98:910-4.
19. Lee JH, Bahk JH, Ryu HG, Jung CW, Jeon Y. Comparison of the bedside central venous catheter placement techniques: Landmark vs electrocardiogram guidance. *Br J Anaesth* 2009; 102:662-6.