

ULTRASOUND PREDICTORS OF UNILATERAL UNDESCENDED TESTES: A PROSPECTIVE STUDY

Sivatha Gopinath¹, Raveendran Jayabalan²¹Assistant Professor, Department of Radiology, Government Vellore Medical College. Tamilnadu, India.²Assistant Professor, Department of Radiology, Institute of Child Health, Egmore, Chennai, Tamilnadu, India.

Received : 08/01/2023
 Received in revised form : 02/02/2023
 Accepted : 14/02/2023

Keywords:

Cryptorchidism, Testicular Atrophic Index, Testicular Volume, palpable testis, nonpalpable.

Corresponding Author:

Dr. Raveendran Jayabalan

Email: raveendran.jayabalan@gmail.com

DOI: 10.47009/jamp.2023.5.2.29

Source of Support: Nil,
 Conflict of Interest: None declared

Int J Acad Med Pharm
 2023; 5 (2); 137-139

**Abstract**

Background: Cryptorchidism is a commonly prevalent genitourinary anomaly. The diagnosed male infants are prone to testicle cancer and infertility issues that increase with late diagnosis of the undescended condition of the testis. Physical examination is the mainstay diagnostic procedure, yet a substantial number of cases that included nonpalpable undescended testis (UDT) could not be indicated by the same. **Aim:** To evaluate the location and testicular volume of Undescended testis and correlation with intraoperative testicular findings in children under 15 years of age. **Materials and Methods:** This prospective study was conducted among children (<15 years) at Vellore medical college. In accordance with the age (<4 and >4 years), the patients were categorized into two groups Group A and Group B. TAI was evaluated using ultrasonography to evaluate the effect of the location of testicles or the age of patients on the volume of cryptorchid testicles. **Result:** Out of 50 patients analyzed, 40 patients were diagnosed with palpable testes and 10 patients with nonpalpable testes. Group A had a higher number of palpable UDT (23) than group B (17). The number of patients with nonpalpable UDT was higher in group B (7) than that of A (3). In both groups, patients with palpable UDT were found to occur substantially with a predominant anomaly on the right side. **Conclusion:** The scrotal US can provide an accurate comparative assessment of the growth of the testes before and after orchidopexy.

INTRODUCTION

Cryptorchidism (undescended testis-UDT) is the utmost common genito-urinary incongruity with a recurrence of 3% and 30% among full and premature males of pediatric age.^[1] UDT could occur either unilaterally, which is more common, or rather bilateral, which is relatively less common in occurrence.^[2] The result of such a clinical condition could lead to substantial medical implications, for instance, infertility besides testicular malignancy. The longer the prevalence of UDT, high is the incidence of complications related to fertility. The inability to detect a nonpalpable UDT adds additional risk to the prognosis of cryptorchidism¹. Although the occurrence of palpable UDT is predominant, a significant number of nonpalpable UDT demands the application of an effective diagnostic technique. Hence early diagnosis plays a very significant role in the management of UDT.^[3] Physical examination is the most vital diagnostic procedure for UDT. The non-palpability of the testis might exist as intra-abdominal or ectopic. Additional complications of a nonpalpable testis

may also be contributed by factors that prevent a physical examination that would include the non-cooperative nature or obese condition of the child.^[4] For a nonpalpable UDT, additional diagnostic imaging procedures such as ultrasound, CT and MRI are being employed. This is because of the criticality of the pre-surgical localization of the testis for a definitive UDT treatment.^[5] Since CT and MRI involve the exposure of children to radiations and some might require sedation, ultrasound (US) technique involving no radiation as well as designated as non-invasive is predominantly being employed for detection of UDT.^[6,7] Hence the following study was carried out to reveal the diagnostic efficiency of ultrasound in the correlation and outcome of undescended testis patients.

Aim

This study aimed to evaluate undescended testis's location and testicular volume and correlation with intraoperative testicular findings in children under 15 years of age.

MATERIALS AND METHODS

After getting informed consent and ethical committee approval, this prospective study was conducted at Vellore medical college from January 2019 to December 2019 on 50 patients. For UDT treatment, 50 patients were admitted to the Department of Paediatric Surgery and were evaluated in the Department of Radiology in Government Vellore Medical College. An age-wise categorization of the patients was done according to which patients under 4 years were grouped in Group A, and more than 4 years were segregated in Group B. The investigation was also followed up to a year post orchidopexy.

Inclusion Criteria

1. Patients diagnosed with undescended testes
2. Patients willing for surgery
3. Upper age limit is up to 15 years of age

Exclusion Criteria

1. Patients with retractile and ectopic testis
2. Patients not willing/ unfit for surgery
3. Patients with bilateral nonpalpable undescended testis
4. Age more than 15 years of age.

Ultrasound studies were performed by using 7.5 and 10 MHz transducers. In assessing undescended testicles, the largest measurements in each dimension were the usefulness of the testicular atrophy index. The testicular volume (TV) can be calculated by using the empirical formula of Lambert.

$$TV = L \times W \times H \times 0.71$$

The testicular atrophy index (TAI) of the affected testicle was calculated as:

$$TAI = \frac{(\text{Contralateral testis volume} - \text{affected testis volume})}{\text{Collateral testis volume}} \times 100$$

TAI is expressed in percentage.

In this study, we prospectively measured the TV of unilateral cryptorchid testicles and determined TAI to evaluate the effect of the location of testicles or the age of patients on the volume of cryptorchid testicles.

RESULTS

Out of 50 patients analyzed, 40 patients were diagnosed with palpable testes and 10 patients with nonpalpable testes. In Group A (26 patients), 3 patients have nonpalpable UDT and 23 patients have palpable UDT. In Group B (24 patients), 7 patients have nonpalpable UDT and 17 patients have palpable UDT. In both, the groups, prevalence of palpable UDT was predominant compared with that of nonpalpable UDT. Out of 50 cases, 30 cases were affected on the right side, 20 cases were affected on the left side.

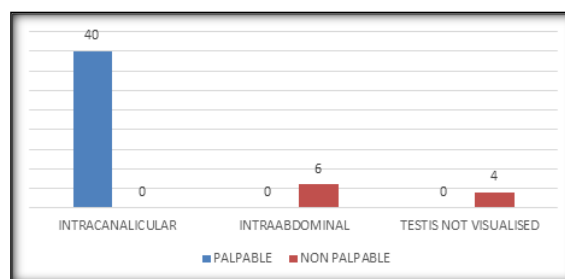


Figure 1: Preop Ultrasound findings

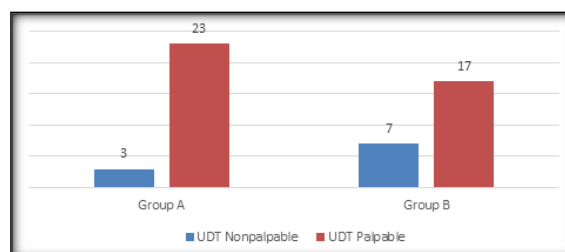


Figure 2

Out of 50 patients, among 40 patients of palpable undescended testes, pre-operative ultrasound shows intracanalicular position with 24 patients mean TAI 11% and remaining 16 patients have mean TAI 13%. Out of 10 patients of nonpalpable undescended testis, 6 patients were found to have an intraabdominal location with a mean TAI of 60% in group B and mean TAI of 15% in group A. Preop ultrasound of remaining 4 patients were inconclusive /testis not visible. So in Group B, showing TAI with more value suggests or implies vanishing testis syndrome. A decrease in the volume of cryptorchid testicles was observed in all age groups except within the group younger than 6 months. Among the 40 patients of palpable UDT, those who displayed intra-canalicular location underwent open orchidopexy, and those 10 patients of nonpalpable UDT underwent laparoscopic exploration. 6 patients were found to have intraabdominal testes, and 4 patients had vanishing testes/testicular agenesis. Postop follow-up: Group A patients and patients with low TAI showed significant improvement in testicular volume compared to the age group of more than 4 years and with high TAI.

DISCUSSION

UDT is emerging as a common clinical condition in male infants and that of pediatric age. While untreated UDT could lead to several complicated clinical implications, diagnostic time plays a vital role in managing this disorder.^[1,8] With the availability of many imaging techniques, ultrasound imaging is considered feasible and non-invasive by many researchers.^[9] Ultrasonography is known to be a reliable tool for the measurement of testicular volume with high reproducibility. It is used to determine the volume of the cryptorchid testis before and after testis repositioning.^[10,11] The accuracy and sensitivity of ultrasound imaging and

intra-operative findings were high. The number of patients displaying intra-canalicular and intra-abdominal locations in ultrasound imaging and inter-operative results was accurately associated. However, in earlier studies performed by Komine et al.^[12] and Phewplung et al.^[13] the accuracy levels were less than 100%. Our study's high sensitivity and accuracy levels imply that ultrasound is reliable in identifying the pre-operative location of the undescended testes, which is crucial for treating UDT. Higher TAI was observed in patients above 4 years of age but was reported with poor development. Also, with a predominate right side occurrence of UDT, the recurrence of nonpalpable UDT was found to increase with age. Yet, the occurrence of palpable UDT was more common in both age groups. The TAI value would increase with increasing age if the testes were left untreated. In a study by Kollin et al., it was reported that there was an increase in the median ratio from 0.68 at 6 months to 0.81 at 4 years ($P < 0.001$) in the early treatment group operated at 9 months of age.^[14] This means that early orchidopexy is likely to result in significant recovery of testicular volume. A similar revelation associating the time of UDT diagnosis with the success of orchidopexy was reported.^[15,16]

CONCLUSION

In summary, patients with UDT should be evaluated at an earlier age with ultrasonographic indices of TAI and TV. The scrotal US can provide an accurate comparative assessment of the growth of testes before and after orchidopexy. In group A patient, the growth of the testes after surgery was statistically significant, so earlier age should be recommended for orchidopexy. Ultrasound parameters of Testicular volume and atrophic testicular index play a significant role in Undescended testis, especially in nonpalpable testis. In conclusion, earlier the age of orchidopexy and patients with low TAI show significant improvement.

REFERENCES

1. Acerini CL, Miles HL, Dunger DB, Ong KK, Hughes IA. The descriptive epidemiology of congenital and acquired

- cryptorchidism in a UK infant cohort. *Archives of disease in childhood*. 2009 Nov 1;94(11):868-72.
2. Kolon TF, Herndon CA, Baker LA, Baskin LS, Baxter CG, Cheng EY, Diaz M, Lee PA, Seashore CJ, Tasian GE, Barthold JS. Evaluation and treatment of cryptorchidism: AUA guideline. *The Journal of urology*. 2014 Aug;192(2):337-45.
3. Adesanya OA, Ademuyiwa AO, Bode CO, Adeyomoye AA. Diagnostic value of high resolution ultrasound in localisation of the undescended testis in children. *African Journal of Paediatric Surgery*. 2013 Apr 1;10(2):127.
4. Docimo SG, Silver RI, Cromie W. The undescended testicle: diagnosis and management. *American Family Physician*. 2000 Nov 1;62(9):2037-44.
5. Niedzielski JK, Oszukowska E, Słowikowska-Hilczer J. Undescended testis—current trends and guidelines: a review of the literature. *Archives of medical science: AMS*. 2016 Jun 1;12(3):667.
6. Braga LH, Lorenzo AJ, Romao RL. Canadian Urological Association-Pediatric Urologists of Canada (CUA-PUC) guideline for the diagnosis, management, and follow-up of cryptorchidism. *Canadian Urological Association Journal*. 2017 Jul;11(7):E251.
7. Nijs SM, Eijsbouts SW, Madern GC, Leyman PM, Lequin MH, Hazebroek FW. Nonpalpable testes: is there a relationship between ultrasonographic and operative findings?. *Pediatric radiology*. 2007 Apr;37(4):374-9.
8. Ito T, Matsui F, Fujimoto K, Matsuyama S, Yazawa K, Matsumoto F, Shimada K. Acquired undescended testis and possibly associated testicular torsion in children with cerebral palsy or neuromuscular disease. *Journal of pediatric urology*. 2018 Oct 1;14(5):402-6.
9. Rubin SZ, Mueller DL, Amundson GM, Wesenberg RL. Ultrasonography and the impalpable testis. *Australian and New Zealand Journal of Surgery*. 1986 Aug;56(8):609-11.
10. Cendron M, Huff DS, Keating MA, Snyder HM, Duckett JW. Anatomical, morphological and volumetric analysis: a review of 759 cases of testicular maldescent. *The Journal of urology*. 1993 Mar;149(3):570-3.
11. Riebel T, Herrmann C, Wit J, Sellin S. Ultrasonographic late results after surgically treated cryptorchidism. *Pediatric radiology*. 2000 Feb;30(3):151-5.
12. Komine S, Murayama M, Kinoshita N, Iguchi A, Nakamura S, Masaki Z, Miyaji H. High resolution ultrasound examination in the diagnosis of the undescended testis in the inguinal region. *Hinyokika kyo. Acta urologica Japonica*. 1988 Feb 1;34(2):305-8.
13. Trinavarat P. Accuracy of ultrasound in pediatric undescended testes. *Asian Biomedicine*. 2018 Apr 13;4(6):983-6.
14. Kollin C, Karpe B, Hesser U, Granholm T, Ritzén EM. Surgical treatment of unilaterally undescended testes: testicular growth after randomization to orchidopexy at age 9 months or 3 years. *The Journal of urology*. 2007 Oct;178(4S):1589-93.
15. Cortes D, Thorup JM, Visfeldt J. Cryptorchidism: aspects of fertility and neoplasms. *Hormone Research in Paediatrics*. 2001;55(1):21-7.
16. Chung E, Brock GB. Cryptorchidism and its impact on male fertility: a state of art review of current literature. *Canadian Urological Association Journal*. 2011 Jun;5(3):210.