

LARGE AND BENIGN DEEP SEATED INTRAMUSCULAR LIPOMA; MOST UNDERESTIMATED BENIGN LESION OF THE BODY

Prashanthkumar Bhure¹, Mohd Zaheeruddin Ather², Arunkumar Tukaram², Sharanabasappa Bellikatti¹, Sunil Kumar², Aiswarya Sudheer³

¹Assistant Professor, Department of General Surgery, Esic Medical College & Hospital, Gulbarga, Karnataka, India

²Associate Professor, Department of General Surgery, Esic Medical College & Hospital, Gulbarga, Karnataka, India

³Junior Resident, Department of General Surgery, Esic Medical College & Hospital, Gulbarga, Karnataka, India

Received : 19/09/2022
Received in revised form : 28/10/2022
Accepted : 08/11/2022

Keywords:

Lipoma, Liposarcoma, intramuscular, excision, benign swelling.

Corresponding Author:

Dr. Sharanbasappa Bellikatti,
Email: sharanpb90@gmail.com
ORCID: 0000-0002-1996-530X

DOI: 10.47009/jamp.2022.4.5.76

Source of Support: Nil,
Conflict of Interest: Nonedeclared

Int J Acad Med Pharm
2022; 4 (5); 380-383



Abstract

Background: Benign & large intramuscular lipoma is hard to find in literature, moreover deep seated intramuscular lipoma is rarely seen. Differentiation of the infiltrative type of intramuscular lipoma from liposarcoma is very difficult. Whenever Surgical margin is not clear post-operative recurrence can be seen. Intramuscular lipoma can occur anywhere in the body and almost in any anatomical site. **Objectives:** This study aims at decreasing the chances of missing out cases of liposarcoma which have close resemblance to large intramuscular lipomas. **Materials and Methods:** A prospective study of all the patients who are clinically diagnosed with intramuscular lipoma were studied between March 2020 to March 2022. **Result:** All patients in the study had their lipomas completely removed to prevent a local recurrence. Lipomatous lesions were completely removed and most of them presented capsulated which facilitates Surgery. All patient in our study explained about surgery and post-surgery follow-up. 12 cases of intramuscular lipomas were studied of which predominantly Males are around 67% with median age group of 43 years, predominantly seen in upper limb. Various results regarding location, clinical presentation, intraoperative finding and treatment of our study have been described in detail below. **Conclusion:** Deep seated intramuscular lipoma have typical presentation, especially when they are large and usually show signs that may lead to confusion with well-differentiated low-grade liposarcoma. Intramuscular lipomas are difficult to identify preoperatively, MRI sometimes doesn't distinguish intramuscular lipoma from liposarcoma. Surgery is the mainstay of treatment. HPE examination and close observation post surgery is essential to exclude any chance of liposarcoma.

INTRODUCTION

Lipomas are the most common type of soft tissue tumour occurring in the subcutaneous tissue. Rarely, lipomas are found in the deeper soft tissue such as intramuscular, intermuscular & parosteal sites. Those seen within a skeletal muscle are called as intramuscular lipoma. Intramuscular lipomas may be seen in any age group & intramuscular lipoma are deep seated, nontender, benign, circumscribed and always unencapsulated lesions. Incidence of Intramuscular lipomas is <1% of all lipomas.^[1] Most Intramuscular lipoma are solitary i.e. located within a single muscle, while multiple swellings are very rare in intramuscular lipoma. They present with typical histological features. Intramuscular lipoma may be divided into 3 types i.e. the well-

circumscribed type, the infiltrative type, and lastly the mixed type. In these three types differentiation between the infiltrative type from liposarcoma is very difficult. Chances of Local recurrence are high when the surgical margin is not clear. They can occur anywhere in the body.^[1]

Intramuscular lipomas (IM) are benign adipose tumours of the soft tissues which may resemble sarcomas due to their size, deep location and occasionally infiltrative growth. Being aware of their existence is fundamental in order to treat them correctly.^[2]

Intramuscular lipomas, however, arise between muscle fibres, pass through the intermuscular septa and infiltrate the surrounding tissues, rendering removal of the lesion from the nearby muscles difficult. Liposarcoma are malignant soft tissue

tumours reported in radiological as well as histological findings to comprise of 7.27% of the soft tissue sarcomas, and be able to mimic inter-and intramuscular lipomas, rendering the diagnosis and choice of treatment difficult.^[3]

In chest wall, Lipomas can be classified into two varieties depending on their location, namely superficial and deep-seated intramuscular chest wall lipomas. Deep-seated intramuscular chest wall lipomas are rarer than superficial lipomas, and they can show histological infiltrative behaviours and have the potential for malignancy, such as liposarcoma.^[4]

The World Health Organization's Committee for the classification of soft tissue tumours established that benign lipomatous lesions involving soft tissues can be classified into 9 groups according to histological features which include lipoma, lipomatosis, lipoblastoma, angioliipoma, myoliipoma of soft tissues, chondroid lipoma, spindle cell lipoma, hibernoma and pleomorphic lipoma.^[5]

MATERIALS AND METHODS

This is a prospective study conducted in the Department of General Surgery of ESIC Medical

College, Kalaburagi, for a time period of 2 years from 01-03-2020 to 01-03-2022. All the patients clinically diagnosed with intramuscular lipoma are included in the study. The sample size is 12.

Inclusion Criteria

- All clinically diagnosed intramuscular lipoma.

Exclusion Criteria

- Preoperative evaluation found to be other than intra-muscular lipoma
- Clinically proven liposarcoma
- Not fit for elective surgery
- Uncontrolled DM, HTN, deranged PT/INR.

RESULTS

All patients underwent a full evaluation including detailed history. All routine blood investigations, Ultrasonography / Imaging , FNAC were done. All patient in our study were explained about surgery and post-surgery follow up. Written consent from the patients were taken for surgical Excision of lipoma. Lipomatous lesions were completely removed to prevent a local recurrence. Specimen sent for histopathological conformation.

Table 1: Age Distribution

| Age | <20 Years | 21-30years | 31-40 Years | 41-50years | 51-60 Years | >61 Years |
|--------|-----------|------------|-------------|------------|-------------|-----------|
| Number | 1 | 2 | 1 | 5 | 2 | 1 |

Table 2: Sex Destruction

| Male | Female |
|------|--------|
| 8 | 04 |

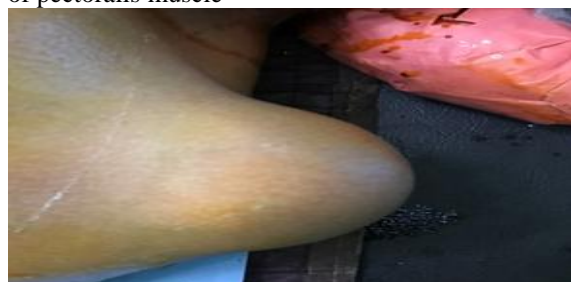Table 3: Charcterstic of Intramusclar Lipoma

| SL NO | Gender | Age | Duration | Localisataion |
|-------|--------|-----|-----------|-------------------------------------|
| 1 | M | 36 | 1 ½ YEARS | LEFT FOREARM |
| 2 | F | 27 | 2 YEARS | CLAVICULAR HEAD OF PECTROALIS MAJOR |
| 3 | M | 41 | 9 MONTHS | CHEST |
| 4 | F | 18 | 2 MONTHS | MID PALMAR |
| 5 | M | 43 | 3 YEARS | THIGH |
| 6 | M | 54 | 9 MONTHS | BUTTOCK |
| 7 | M | 23 | 2 MONTHS | THIGH |
| 8 | M | 49 | 3 YEARS | CHEST |
| 9 | F | 59 | 8 MONTHS | BUTTOCK |
| 10 | M | 44 | 6 MONTHS | SHOULDER |
| 11 | F | 72 | 2 YEARS | NECK |
| 12 | M | 48 | 1 YEARS | ARM |

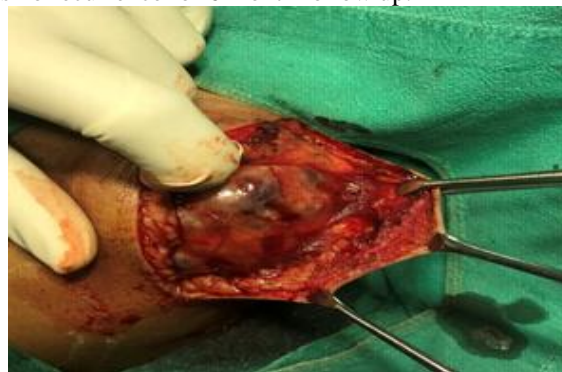LARGEST SIZE IS 9.5 * 4.5 CM ANG SMALLEST IS 1.5*1.2 CM. All patients underwent surgery successfully following admission and recovered successfully. There was no recurrence for 6 month follow up.

Few interesting case pictures

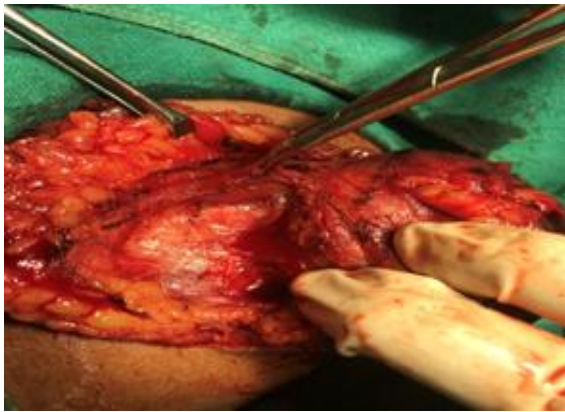Case 1: Intramuscular lipoma from clavicular head of pectoralis muscle



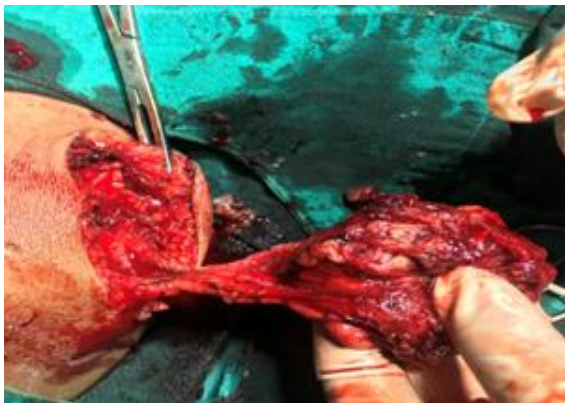Preoperative picture left shoulder



After incision



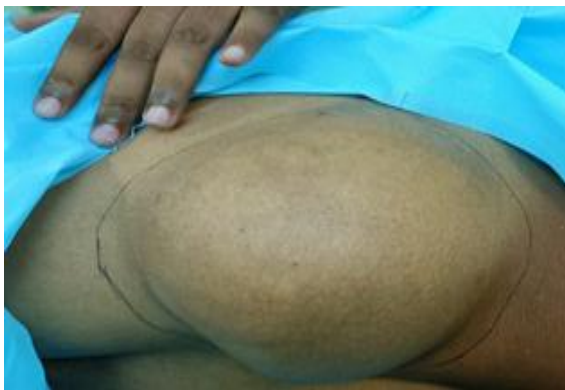Clavicular head of PM



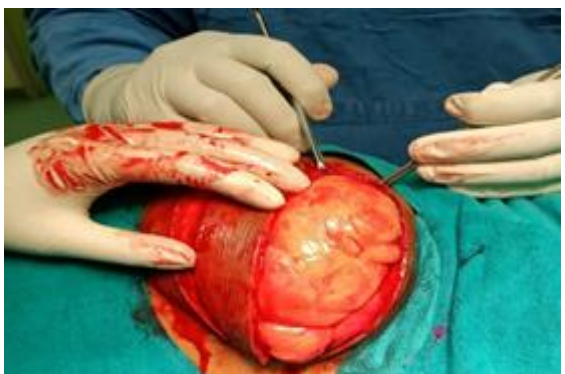Excision of specimen

Case 2

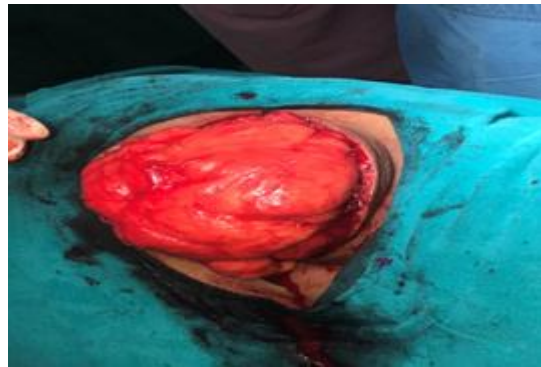
59-year female large intramuscular lipoma from left gluteus maximus.



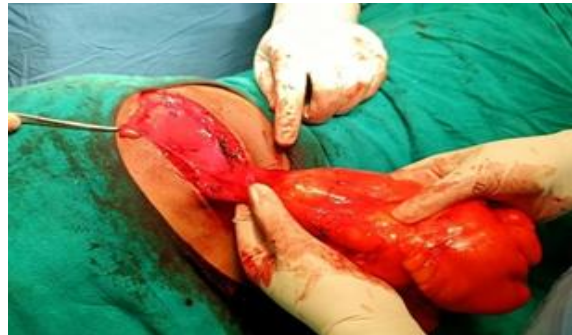Preoperative picture



Intraoperative after incision



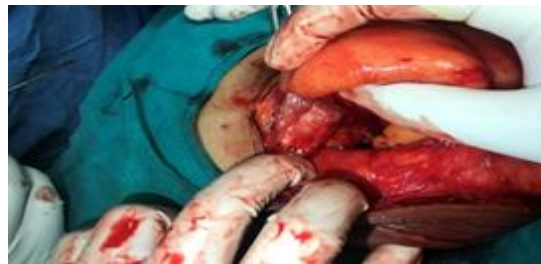Intraoperative : before excision



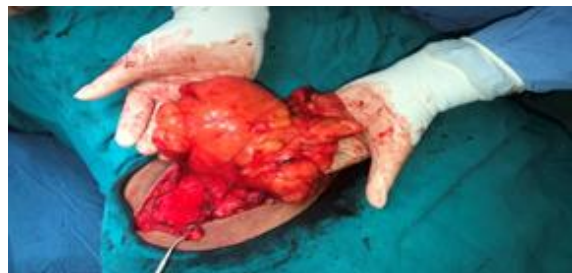Intraoperative excision

Case 3

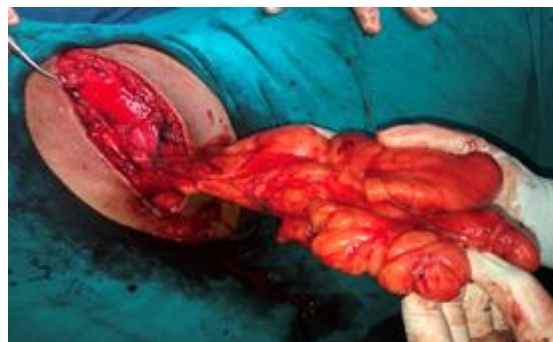Left buttock intramuscular lipoma

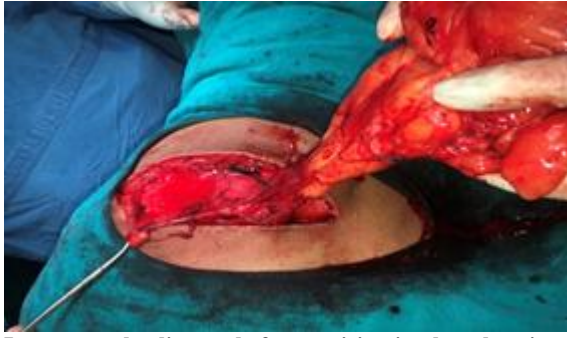

Intramuscular lipoma gluteal region



Intramuscular lipoma after dissection





Intramuscular lipoma before excision in gluteal region

DISCUSSION

Lipoma is benign soft tissue tumour that usually presents as slow growing, painless, well circumscribed mass varying in size in different parts of the body.^[6]

The usage of high-resolution, high frequency USG has shown improvements in image quality and these allow a more specific and accurate description of the lesion. The differential diagnoses other than lipomas on ultrasound include epidermoid cyst, ganglion cyst, peripheral nerve sheath tumour, accessory breast tissue, hamartomas, and fibroma.^[7]

The intramuscular lipomas are benign lesions, despite of their infiltrative nature & high local recurrence rate. Intramuscular lipoma do not have a malignant transformation and never metastasize. But intramuscular lipoma with malignant transformation has been mentioned in very few studies even though no definite evidence is available.^[8]

Discussion on Age

In our study maximum number of cases are aged around 31-40 years 5cases (41%), least incidence being < 20 years &> 61 years 1 cases (8.3% each), and 21-30 year and 51-60 years both 2 cases each (16.7% each)

Number of Lipomas

In our study all cases are solitary, no cases are multiple

Age Distribution

Predominantly male, male case are 8 in number and female cases 4 case; in 2;1 ratio

Location

Around 8 cases i.e. around 2/3rd found in upper trunk, remaining 1/3rd lower trunk.

CONCLUSION

Intramuscular lipomas are relatively uncommon lipoma subtype. Due to poor clinical and unfamiliar pathology, intramuscular lipomas are commonly misdiagnosed with other benign and malignant lesion of the body. So careful clinical, preoperative workup in the form of imaging and histological examination can diagnose typical characteristic of intramuscular lipoma and post-operative follow up and close surveillance is needed whenever in doubt as infiltrative type of intramuscular lipoma has a close resemblance to liposarcoma.

We want to conclude that intramuscular lipoma is relatively rare entity which shouldn't be under diagnosed and misdiagnosed. So close preoperative and strict post-operative follow-up are must in these cases.

REFERENCES

1. Sferopoulos NK. Anatomical Distribution of Intramuscular Lipomas. *J Forensic Sci Res.* 2017;1:035-039.
2. Ramos-Pascua LR, Guerra-Álvarez OA, Sánchez-Herráez S, Izquierdo-García FM, Maderuelo-Fernández JÁ. Lipo-mas intramuscular: bultos benignos grandes y profundos. Revisión de una serie de 51 casos. *Rev Esp Cir Ortop Traumatol.* 2013; 57:391--397.
3. Liu DR, Li C, Chen L. Management of giant intermuscular lipoma of hips: A case report and review of literature. *Mol Clin Oncol.* 2013;1(2):369-372. doi: 10.3892/mco.2013.63.
4. Hwang J, Jo WM, Min BJ, Shin JS. Deep-seated intramuscular lipoma penetrates the intercostal muscle. *J Thorac Dis.* 2015;7(10):E493-5. doi: 10.3978/j.issn.2072-1439.2015.10.29.
5. Medina CR, Schneider S, Mitra A, Spears J, Mitra A. Giant submental lipoma: Case report and review of the literature. *Can J Plast Surg.* 2007;15(4):219-22. doi: 10.1177/229255030701500405.
6. Juliasse LE, Nonaka CF, Pinto LP, Freitas Rde A, Miguel MC. Lipomas of the oral cavity: clinical and histopathologic study of 41 cases in a Brazilian population. *Eur Arch Otorhinolaryngol.* 2010;267(3):459-65. doi: 10.1007/s00405-009-1010-z.
7. Rahmani G, McCarthy P, Bergin D. The diagnostic accuracy of ultrasonography for soft tissue lipomas: a systematic review. *Acta Radiol Open.* 2017;6(6):2058460117716704. doi: 10.1177/2058460117716704.
8. McTighe S, Chernev I. Intramuscular lipoma: a review of the literature. *Orthop Rev (Pavia).* 2014;6(4):5618. doi: 10.4081/or.2014.5618.