

Concurrence of Mature Cystic Teratoma and Ovarian Carcinoid Tumor in a Young Patient

Dincer Yildirim¹, Gozde Sahin², Sertac Aycicek³, Denizhan Bayramoglu⁴

¹ Division of Gynecologic Oncology, Department of Obstetrics and Gynecology, Diyarbakir Gazi Yasargil Research and Training Hospital, Diyarbakir, Turkey

² Division of Gynecologic Oncology, Department of Obstetrics and Gynecology, Sanliurfa Research and Training Hospital, Sanliurfa, Turkey

³ Department of Obstetrics and Gynecology, Diyarbakir Gazi Yasargil Research and Training Hospital, Diyarbakir, Turkey

⁴ Division of Gynecologic Oncology, Department of Obstetrics and Gynecology, Konya City Hospital, Konya, Turkey

ORCID; 0000-0002-7516-5972, 0000-0003-3067-9125, 0000-0002-9306-6281, 0000-0002-6183-8398

Abstract: Ovarian carcinoid tumors which are generally uncommon can be primary or metastatic and are usually related with mature cystic teratoma. The main treatment method for ovarian carcinoid tumors is surgery. In this care report, we presented an unusual patient with carcinoid tumor originating from mature cystic teratoma in a 19-year-old young woman admitted with the complaint of abdominal pain. The patient underwent bilateral cystectomy and received no further treatment. Ovarian carcinoid tumor originating from mature cystic teratoma is an unusual condition in young women like in our case and generally has a good prognosis if it is in the early stage.

INTRODUCTION

Mature cystic teratomas (MCT) commonly have benign histopathologic features and account for 10–20% of ovarian tumors ¹. They originate from the three germ layers; ectoderm, mesoderm and endoderm. Teratoma with malignant transformation (TMT) is a rare condition that can be seen in 1–3 % of all MCTs ². The types of malignant tumor are carcinoid tumor, adenocarcinoma and squamous cell carcinoma ³. Ovarian carcinoid tumors are generally related with mature cystic teratoma. Ovarian carcinoid tumors are rare and account for %1 of all carcinoid tumors. They can be primary or metastatic. Primary ovarian carcinoid tumors are generally unilateral; however, contralateral ovary can have mucinous tumor or mature cystic teratoma in %16 of the cases. The prognosis of ovary confined tumor is very good and its 10-year survival rate is %100. Distant metastases originating from the germ cells are associated with poor prognosis. They have 4 pathologic types as insular, stromal, trabecular, and mucinous. The insular type is most the common and can be accompanied by carcinoid syndrome. The carcinoid syndrome has the symptoms like palpitation, flushing and diarrhea caused by serotonin release. The primary treatment is surgery including cystectomy, unilateral or bilateral salpingo-oophorectomy and hysterectomy with bilateral salpingo-oophorectomy with or without surgical staging depending on the age.

In this case report, we presented an unusual patient with carcinoid tumor originating from mature cystic teratoma in a 19-year-old young woman ^{4,5}.

CASE REPORT

A 19-year-old single woman was admitted the hospital with abdominal pain. Ultrasound and Magnetic Resonance Imaging results of the patient approved the dermoid cyst of almost 12×7 cm originating from the left ovary (Figure 1) and anechoic cyst of 6x4 cm originating from the right ovary. The tumor markers were normative with the dispensation of CA 9-19 (1700 ng/mL). There were no signs of carcinoid syndrome in the patient. An informed consent was received from the patient. She was treated with laparoscopic bilateral ovarian cystectomy. On macroscopic examination, a dirty yellow material mixed with hairs was monitored in the brown cystic tissue fragment and a solid area of 4.5x3

Received : 07/06/2021

Received in revised form : 09/09/2021

Accepted : 10/22/2021

Available online : 01/15/2022

Keywords:

Carcinoid tumor
Cystic teratoma
Salpingo-oophorectomy
Abdominal pain

Corresponding Author:

Gozde Sahin

E-mail; sahin.gozde1983@gmail.com

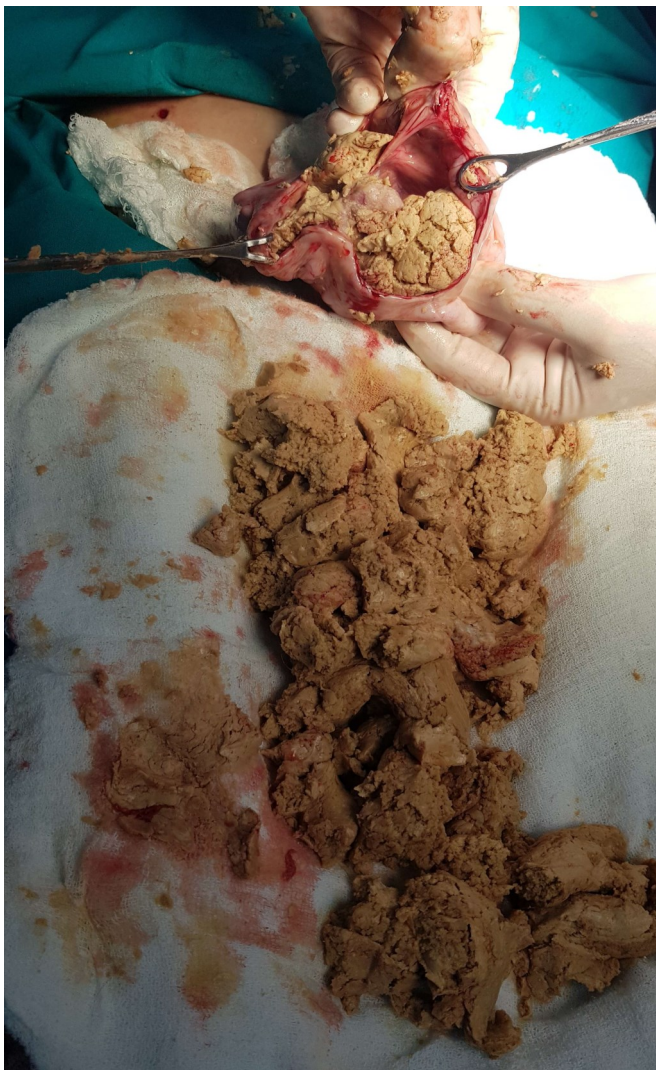
http://dx.doi.org/10.29228/jamp.53849

Int J Acad Med Pharm,

2022; 4 (1); 86-87



cm with brown bone-hard structures attached to the mucosa of the cyst was monitored in the left ovary while a white colored structure similar to a follicle cyst was observed in the right ovary. In pathology sections, a tumor focus with coarse chromatin consisting of infiltrative cell groups was observed in an area of mature cystic teratoma containing skin, skin appendages, respiratory, intestinal epithelium, and cartilage tissue in the left ovary (Figure 2) and follicle cyst in the right ovary. The diameter of the tumor was 5 mm. On immunohistochemical examination, CDX2, CD56, Chromogranin A, Synaptophysin, and PANCK were positive while Inhibin and EMA were negative. The proliferation index was detected by Ki67 expression and found as 1- 2%. The pathologic diagnosis was carcinoid tumor arising from mature cystic teratoma. The patient underwent left salpingo-oophorectomy and received no further treatment. No recurrence or metastasis was detected on the Computed Tomography (CT) and the tumor markers were normal after 1-year follow-up.



Figür 1. Gross appearance of the left ovary a multicystic mass containing viscous sebaceous material and hair

DISCUSSION

MCTs are generally benign and malignant conversion is unusual⁶. Ovarian carcinoid tumors evolve from neuroendocrine cells of the gastrointestinal or respiratory epithelium. Worse prognosis in malignant conversion is intraoperative rupture, invasion of cyst wall and tumor seeding³. Primary ovarian carcinoid tumors are generally unilateral; however, a cystic teratoma or mucinous neoplasm can be in the contralateral ovary in 16% of the patients⁷. Some species of

carcinoid tumors often secrete serotonin, histamine, catecholamine, prostaglandin, and vasoactive peptides which can cause carcinoid syndrome. The symptoms of carcinoid syndrome are flushing, secretory diarrhea, wheezing, and cardiac disease⁸.

Preoperative diagnosis of TMT cannot be precisely identified. In most cases, a final diagnosis is feasible just on the histopathologic examination if the tumor is small or there are no specific symptoms of the disease.

In our case, we found the ovarian carcinoid tumor by coincidence as well. Tumor cells were immunopositive for Chromogranin A, Synaptophysin and CD56. These findings are typical for carcinoid tumors. In MCT, the adequate specimen from the solid fragments is significant in order to seize upon the microscopic fields containing TMT. Surgical excision is the treatment method for primary ovarian carcinoma. Most of ovarian carcinoid tumors arising from teratomas are observed in postmenopausal women; however, young women can have these tumors as well. Postmenopausal women can be treated with hysterectomy and bilateral salpingo-oophorectomy; however, local excision and unilateral salpingo-oophorectomy are the most preferred therapeutic options for young women. The major problem after surgery is the recurrence of the tumor. The primary site for carcinoid tumor metastasis is liver. Chemotherapy or radiation therapy has a limited role in recurrence or advanced disease^{4,5}.

Ovarian carcinoid tumor originating from MCT is quite uncommon in young women and generally has good prognosis if it is in an early stage. Preoperative diagnosis is very difficult. It can be histopathologically diagnosed with comprehensive examination.

Ovarian carcinoid tumors have low malignant potency, but the prognosis is poorer if the disease is in an advanced stage. Organ-confined disease has good prognosis and the 5-year survival rate is almost 100%. However, prognosis of the patients with advanced ovarian carcinoid which is usually treated with aggressive cytoreductive surgery is poor with a 5-year overall survival rate of approximately 33%^{4,9}.

REFERENCES

1. Khanna S, Srivastava V, Saroj S, Mishra SP, Gupta SK. 2012. An unusual presentation of ovarian teratoma: a case teratoma. *Case Reports in Emergency Medicine* 2012: 845198.
2. Kim SM, Choi HS, Byun JS, Kim YH, Kim KS, Rim SY, et al. 2003. Mucinous adenocarcinoma and strumal carcinoid tumor arising in one mature cystic teratoma of the ovary with synchronous cervical cancer. *Journal of Obstetrics and Gynaecology Research* 29: 28–32.
3. Boyraz G, Selcuk I, Guner G, Usubutun A, Gunalp GS. 2012. A primary insular type carcinoid tumor arising in a mature cystic teratoma of the ovary: a case report. *Journal of Clinical Case Reports* 2: 16.
4. De la Torre J, García A, Castellví J, López M, Gil A. 2004. Primary ovarian trabecular carcinoid tumour: a case report with an immunohistochemical study and a review of the literature. *Archives of Gynecology and Obstetrics* 270: 274-277.
5. Amano Y, Mandai M, Baba T, Hamanishi J, Yoshioka Y, Matsumura N, et al. 2013. Recurrence of a carcinoid tumor of the ovary 13 years after the primary surgery: A case report. *Oncology Letters* 6: 1241-1244.
6. Donadio AC, Motzer RJ, Bajorin DF, Kantoff PW, Sheinfeld J, Houldsworth J, et al. 2003. Chemotherapy for teratoma with malignant transformation. *Journal of Clinical Oncology* 21: 4285-4291.
7. Robby SJ, Norris HJ, Scully RE. 1975. Insular carcinoid primary in the ovary. A clinicopathologic analysis of 48 cases. *Cancer* 36: 404-418.
8. Yamasaki T, Yagihashi Y, Shirahase T, Hashimura T, Watanabe C, et al. 2004. Primary carcinoid tumor arising in a retroperitoneal mature teratoma in an adult. *International Journal of Urology* 11: 912-915.
9. Kim JY. 2016. A carcinoid tumor arising from a mature cystic teratoma in a 25-year-old patient: a case study. *World Journal of Surgical Oncology* 14: 120.